

Biliary stenting and successful intentional stent retrieval after 6 months in a benign stricture following hepaticojejunostomy

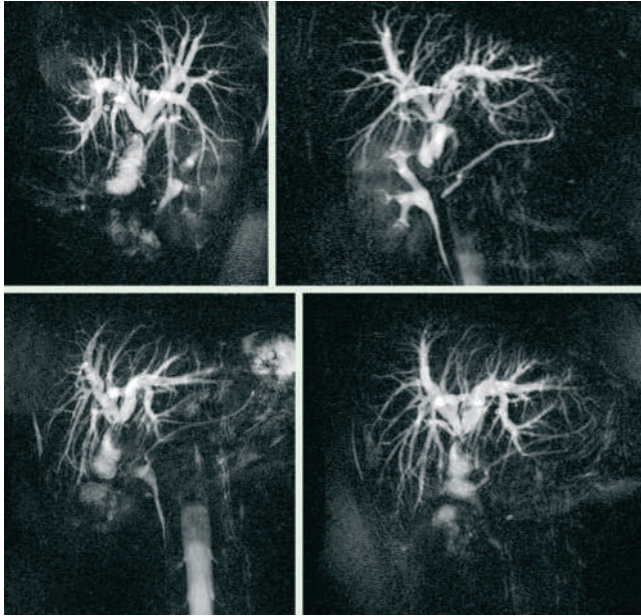


Fig. 1 Magnetic resonance cholangiopancreatography T₂-sequence showing stenosis of the anastomosis after hepaticojejunostomy.

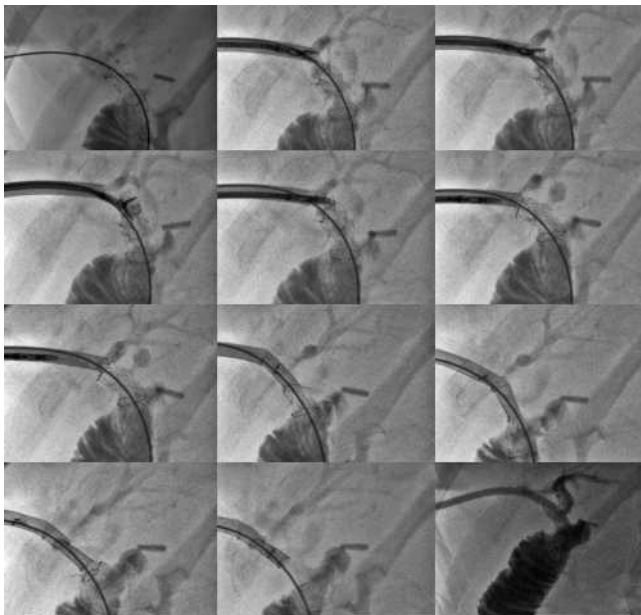


Fig. 2 Sequence of stent extraction through a 12 F introduction sheath using an endoscopic grasping forceps.




Fig. 3 Stent and introduction sheath after removal.

Video 1

Extraction of the stent through a 12 F introduction sheath using an endoscopic grasping forceps.

The management of benign biliary strictures remains a challenge for interventional endoscopists. Surgery, still the mainstay of treatment, is associated with nonnegligible morbidity and mortality. Recently, new techniques and devices for endoscopic therapy have become available [1,2].

A 45-year-old woman was referred to our clinic because of recurrent fever of un-

known origin. She had a history of hepaticojejunostomy due to bile duct injury following laparoscopic cholecystectomy. Ultrasound, laboratory, and MRI studies led to the discovery of a circular stenosis of the anastomosis (▶ Fig. 1). Biopsies ruled out a malignant stenosis. Percutaneous transhepatic cholangiography (PTC) showed a filiform and complex stenosis. Multiple unsuccessful balloon dila-

tations were carried out and a temporary Yamakawa drain was placed. PTC after removal of the drain showed a residual stenosis of more than 50%. Hence percutaneous transhepatic cholangiographic drainage with stenting was considered. In order to allow the stent to be withdrawn 6 months later, a polytetrafluoroethylene (ePTFE)-covered stent (Viabil; Gore, Flagstaff, AZ, USA) was chosen. The patient was asymptomatic during the following 6 months. The stent was removed percutaneously through a 12 F introduction sheath with an endoscopic grasping forceps (▶ Fig. 2, 3, ▶ Video 1). The patient was discharged 3 days after stent removal.

Percutaneous treatment of benign biliary stenosis is still a challenging issue for endoscopists. Poor long-term patency of metallic stents in the biliary system and the near-impossibility of removing them limits their range of use in benign stenoses [1,3]. Because of its exoskeleton structure (▶ Fig. 4), the Viabil stent is able to collapse during withdrawal and seems a feasible option when balloon dilatation of a benign stricture is not sufficient [1]. Coated stents have proven good long-



Fig. 4 Viabil stent and its exoskeleton structure.

term patency in malignant stenoses and carry a low risk of tissue ingrowth and sludge accumulation [1,4,5]. This supports the feasibility of intentional retrieval and allows the endoscopist greater latitude when extended time periods of stent placement are necessary [1].

Endoscopy_UCTN_Code_TTT_1AR_2AZ
Endoscopy_UCTN_Code_TTT_1AR_2AJ

D. von Renteln, B. Riecken, M. Ulmer, K. Caca

Medizinische Klinik I, Klinikum Ludwigsburg, Ludwigsburg, Germany

References

- 1 Kuo MD, Lopresti DC, Gover DD et al. Intentional retrieval of viabil stent-grafts from the biliary system. *J Vasc Interv Radiol* 2006; 17: 389–397
- 2 Born P, Rosch T, Bruhl K et al. Long-term results of endoscopic and percutaneous transhepatic treatment of benign biliary strictures. *Endoscopy* 1999; 31: 725–731
- 3 Wadhwa RP, Kozarek RA, France RE et al. Use of self-expandable metallic stents in benign GI diseases. *Gastrointest Endosc* 2003; 58: 207–212
- 4 Soderlund C, Linder S. Covered metal versus plastic stents for malignant common bile duct stenosis: a prospective, randomized, controlled trial. *Gastrointest Endosc* 2006; 63: 986–995
- 5 Leung J, Rahim N. The role of covered self-expandable metallic stents in malignant biliary strictures. *Gastrointest Endosc* 2006; 63: 1001–1003

Bibliography

DOI 10.1055/s-2007-966801

Endoscopy 2007; 39: E335–E336

© Georg Thieme Verlag KG Stuttgart · New York · ISSN 0013-726X

Corresponding author

K. Caca, MD

Medizinische Klinik I

Klinikum Ludwigsburg

Ludwigsburg

Germany

karel.caca@kliniken-lb.de