Bizarre gastric ulcer related to betel quid use: report of two cases

A 47-year-old gentleman, who had chewed 20 betel quids daily for 25 years, presented with a 3-day history of melena. Esophagogastroduodenoscopy (EGD) disclosed an ulcerated tumor 3 cm in size in the antrum (**Fig. 1**). Biopsy of the tumor revealed acute and chronic inflammation. The patient quit chewing betel quids. Because of a strong suspicion of malignancy, EGD was repeated 5 days later. It showed ulcers, from 0.5 to 2 cm in diameter, in the antrum. Biopsy again disclosed acute and chronic inflammation. Hence, betel-quid-related gastric injury was suspected. EGD 1 month later showed only a scar in the antrum (**Fig. 2**) and the histology again proved benign.

Another 44-year-old gentleman, who had chewed 20 betel quids daily for 20 years, presented having produced coffee-ground vomitus for 1 day. EGD showed ulcers from 0.2 to 3 cm in diameter in the antrum (**Fig. 3**). Biopsy showed acute and chronic inflammation. *Helicobacter pylori* was found. Endoscopic ultrasound revealed thickening of the antrum. The mucosa and submucosa planes were blurred, but the muscularis propria was intact (**Fig. 4**). The patient quit chewing betel quids and underwent *Helicobacter pylori* eradication therapy. EGD 2 months later revealed two tiny healing ulcers in the antrum (**Fig. 5**). Biopsy disclosed chronic inflammatory cells in the lamina propria. EGD 3 months later showed only erythematous changes of the antral mucosa (**Fig. 6**).

Betel quid consumption results in gastric ulcers in animal studies [1,2]; this is the first report of betel-quid-induced ulcer in human patients. There is no laboratory marker, endoscopic finding, or pathologic feature pathognomonic of betel-quid-induced ulcer. Image studies aid little in the diagnosis. In areas where betel quid chewing is endemic, patients with gastric ulcer or suspected cancer should be asked whether they have a habit of betel quid use. These two cases show that betel-quid-related gastric ulcer can be bizarre in appearance and repeated biopsy is mandatory.

Endoscopy_UCTN_Code_CCL_1AB_2AD_3AC

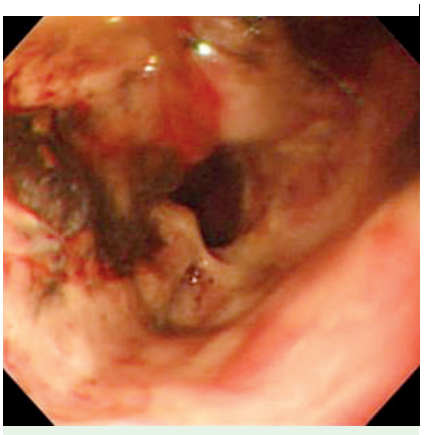

Fig. 1 Esophagogastroduodenoscopy (EGD) showed an ulcerated tumor 3 cm in size in the gastric antrum, involving the pyloric ring.

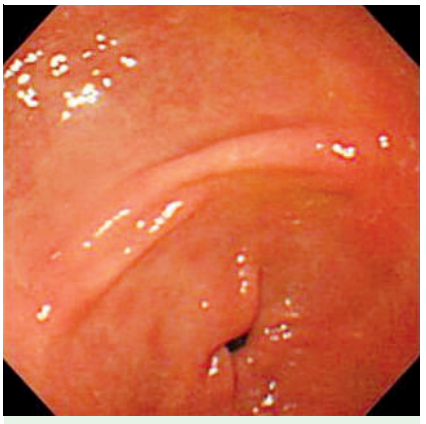

Fig. 2 EGD disclosed a small ulcer scar in the posterior wall of the gastric antrum.

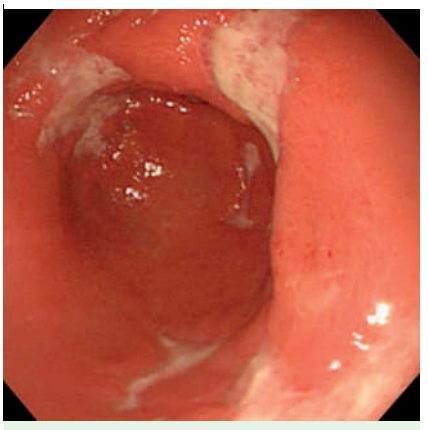

Fig. 3 EGD showed scattered shallow ulcers measuring from 0.2 to 3 cm in diameter in the gastric antrum.

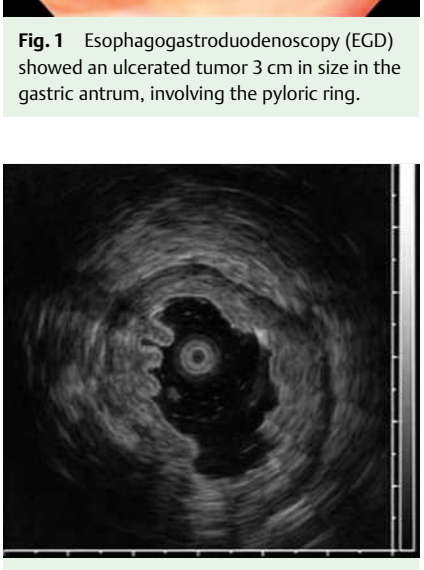

Fig. 4 Endoscopic ultrasound showed thickening of gastric antral wall, up to 10 mm in thickness.

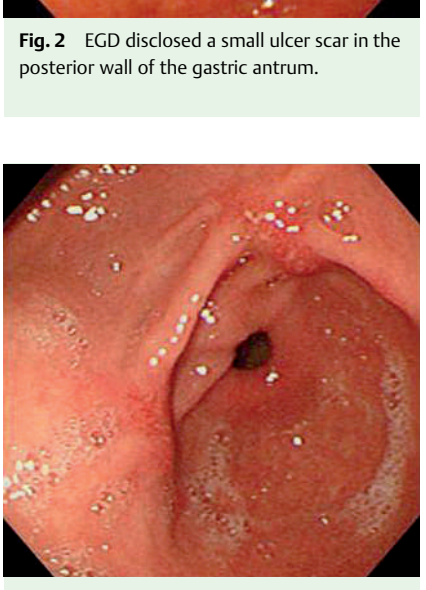

Fig. 5 EGD disclosed two tiny healing ulcers in the gastric antrum.

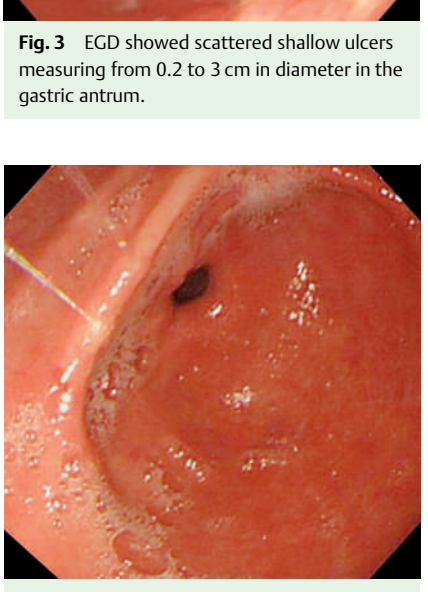

Fig. 6 EGD disclosed mildly erythematous changes of the mucosa in the gastric antrum.

H. C. Lu[1], H. C. Huang[1,2], A. F. Y. Li[2,3], H. C. Lin[1,2], F. Y. Chang[1,2], S. D. Lee[1,2]

[1] Department of Medicine, Taipei Veterans General Hospital, Taipei, Taiwan, Republic of China

[2] National Yang-Ming University School of Medicine, Taipei, Taiwan, Republic of China

[3] Department of Pathology, Taipei Veterans General Hospital, Taipei, Taiwan, Republic of China

References

1 *Hung CR.* Protective effects of lysozyme chloride and reduced glutathione on betel quid chewing-produced gastric oxidative stress and haemorrhagic ulcer in rats. Inflammopharmacology 2004; 12: 115 – 129

2 *Hung CR, Wang PS.* Role of histamine and acid back-diffusion in modulation of gastric microvascular permeability and haemorrhagic ulcers in betel-quid-fed rats. Inflammopharmacology 2004; 12: 277 – 287

Bibliography

DOI 10.1055/s-2007-995684
Endoscopy 2008; 40: E124 – E125

ISSN 0013-726X

Corresponding author

H. C. Huang, MD
Division of Gastroenterology
Department of Medicine
Taipei Veterans General Hospital
No. 201, Sec. 2, Shih-Pai Road
Taipei 11217
Taiwan
Republic of China
Fax: + 886-2-28739318
hchuang2@vghtpe.gov.tw