

Recurrent bacteremia due to retained embolized glue following variceal obliteration

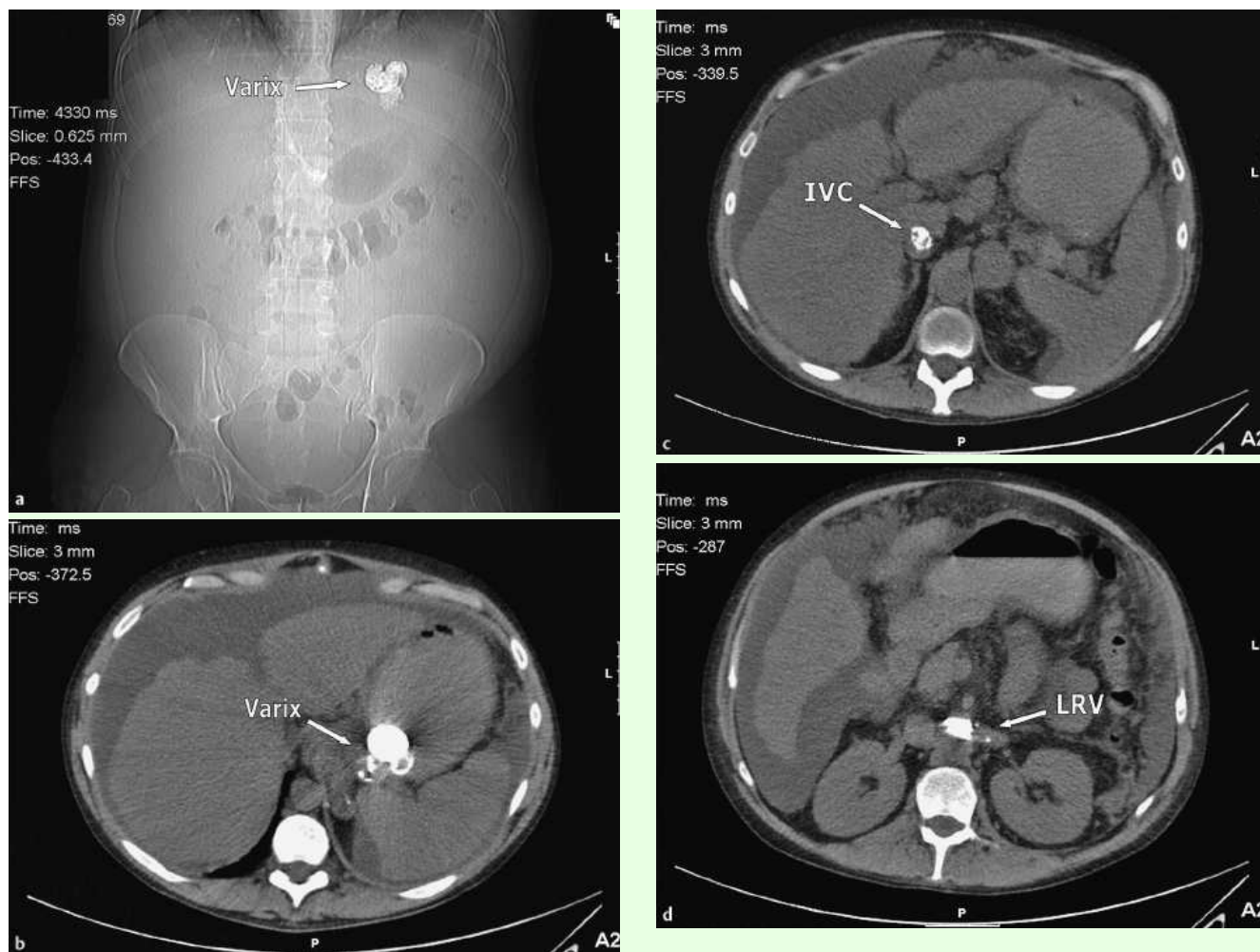


Fig. 1 a–d Abdominal/pelvic CT scan showing multifocal radiopaque densities in the gastric fundal varix and also inferior vena cava (IVC) extending to the left renal vein (LRV) consistent with retained systemically embolized glue, within days of repeated endoscopic injections of glue/lipiodol for gastric variceal hemorrhage.

Cyanoacrylate glue injection is the endoscopic treatment of choice for gastric variceal hemorrhage [1]. Though generally safe [2], glue is rarely associated with systemic embolization and significant bacteremia [3]. Prolonged bacteremia (≥ 4 weeks) has only been reported in two patients [4], in whom retained variceal casts acted as infected foci. Here we report a patient, 24 weeks after variceal injection, with recurrent life-threatening septicemia due to retained “embolized” glue.

A 38-year-old man presented with decompensated alcoholic liver disease complicated by spontaneous bacterial peritonitis (SBP). Intravenous tazocin (piperacillin/tazobactam) treatment was com-

menced after ascitic cultures isolated extended spectrum β -lactamase (ESBL)-producing *Escherichia coli* sensitive to tazocin and ertapenem. Between days 3 and 14, recurrent gastric variceal hemorrhage required repeated endoscopic glue injection to achieve hemostasis. On day 14, renal function suddenly deteriorated (despite terlipressin and albumin); CT imaging revealed glue in the gastric varix and inferior vena cava extending to the left renal vein (► Fig. 1). Renal function improved with supportive measures. From week 3, recurrent swinging pyrexia proved unresponsive to empiric treatment with cefotaxime and later tazocin. Investigation, which included full viral

and bacteriological screens, transthoracic echocardiogram, dental radiographs, gallium scan, and gastrointestinal endoscopies, failed to identify an infective source until, at weeks 7, 14, and 22, following antibiotic-free periods, ESBL-producing *Escherichia coli* sensitive to ertapenem was isolated from blood, and repeat CT at week 24 showed persistence of the glue observed at week 3 (► Fig. 2). Only 6 weeks of intravenously administered ertapenem, following on from shorter courses, successfully treated the pyrexia, with negative culture and sustained improvement in hepatic function. The exclusion of other infective foci suggests that the embolized glue acted as a

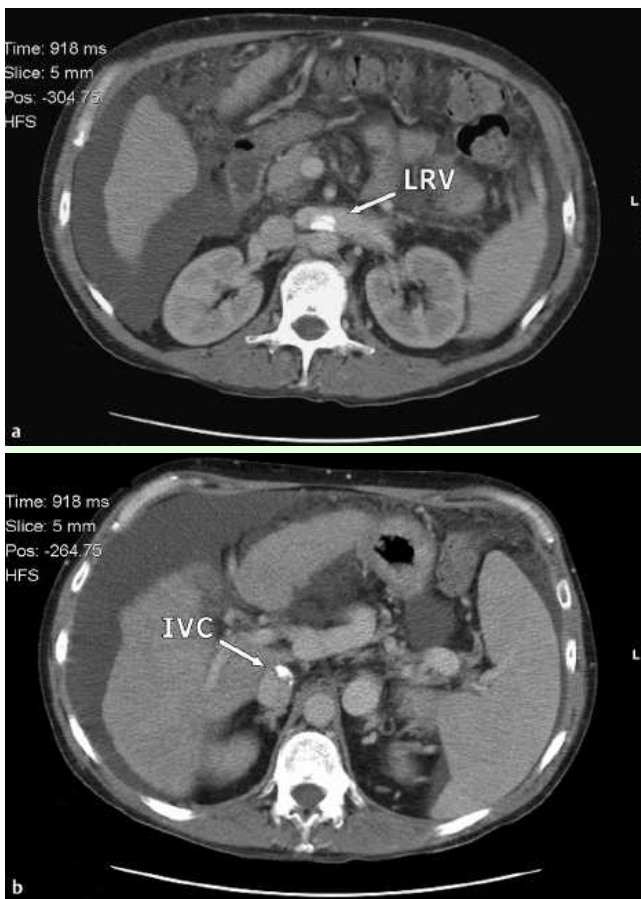


Fig. 2 a, b Abdominal CT scan demonstrating the persistence of the multifocal radiopaque densities in the inferior vena cava (IVC) extending to the left renal vein (LRV) at 24 weeks after glue injection therapy.

nidus for bacterial seeding on or within the adhesive casts during the original procedure. Breakdown of the casts over time could have resulted in the intermittent release of colonized microbes into the systemic circulation, which would have been only partially responsive to short courses of intravenous antibiotics. In conclusion, embolized glue may persist beyond 24 weeks and should be considered if recurrent infection develops which may necessitate protracted courses of antibiotics. This reiterates the need for caution with glue, and the benefit of endosonographic or fluoroscopic monitoring.

Endoscopy_UCTN_Code_CPL_1AH_2AC

**G. Wright¹, W. R. Matull¹,
L. Zambreau¹, S. O'Neill¹, R. Smith²,
J. O'Beirne¹, M. Y. Morgan^{1,2,3}**

¹ The Royal Free Sheila Sherlock Liver Unit, The Royal Free Hospital, Pond Street, London, UK

² Department of Medical Microbiology, Royal Free Hospital, Pond Street, London, UK

³ The Centre for Hepatology, Royal Free Campus, Royal Free & University College Medical School, Rowland Hill Street, Hampstead, London, UK

References

- 1 Seewald S, Sriram PV, Naga M et al. Cyanoacrylate glue in gastric variceal bleeding. *Endoscopy* 2002; 34: 926–932
- 2 Huang YH, Yeh HZ, Chen GH et al. Endoscopic treatment of bleeding gastric varices by N-butyl-2-cyanoacrylate (Histoacryl) injection: long-term efficacy and safety. *Gastrointest Endosc* 2000; 52: 160–167
- 3 Chen WC, Hou MC, Lin HC et al. Bacteremia after endoscopic injection of N-butyl-2-cyanoacrylate for gastric variceal bleeding. *Gastrointest Endosc* 2001; 54: 214–218
- 4 Liao SC, Ko CW, Yeh HZ et al. Successful treatment of persistent bacteremia after endoscopic injection of N-butyl-2-cyanoacrylate for gastric varices bleeding. *Endoscopy* 2007; <http://www.thieme-connect.de/journals/toc/endoscopy/29237>; DOI: 10.1055/s-2007-966556

Bibliography

DOI 10.1055/s-0029-1214580

Endoscopy 2009; 41: E56–E57

© Georg Thieme Verlag KG Stuttgart · New York · ISSN 0013-726X

Corresponding author

M. Y. Morgan, MB ChB, FRCP

The Centre for Hepatology

Royal Free Campus

Royal Free & University College Medical School

Rowland Hill Street

Hampstead

London NW3 2PF

UK

Fax: +44-207-4332870

mymorgan@medsch.ucl.ac.uk