Treatment of radiation-induced distal rectal lesions with argon plasma coagulation: use of a transparent cap

The increasing incidence of chronic radiation proctitis (CRP) is due to the increasing use of radiotherapy in prostate cancer. The incidence ranges between 2% and 20% in various retrospective studies. Median time to clinical symptoms ranges from 8 to 13 months [1]. Argon plasma coagulation (APC) has now been established as an effective, safe, and well-tolerated endoscopic therapy, with success rates between 80% and 100% [2]. The dose–volume toxicity is a well-proven factor in rectal bleeding. Intensity-modulated radiotherapy (IMRT) has reduced the overall rectal toxicity, but rectal lesions induced by IMRT often begin right above the anus [3]. The use of APC is difficult for lesions located immediately above the dentate line in the upper part of the anal canal. These can generally only be approached in the retroflexed position. Disadvantages include a higher risk of rectal scarring, less mobility of the endoscope, and greater patient discomfort.

The use of a transparent cap at the tip of the colonoscope allows direct viewing of low rectal lesions and of the upper part of the anal canal without the retroflexed position (**Fig. 1**).

Visualization of lesions right above the dentate line is facilitated by displacement of mucosal folds without obscuring the lumen (**Fig. 2** and **Video 1**).

Stability is maintained by placing the tip of the endoscope against the mucosa, thus allowing safe APC. Thanks to the cap, the endoscope remains close to the lesion, but not too close to it.

From November 2007 to March 2008, we treated seven patients for CRP with APC using a transparent cap. Sessions were performed without sedation and were well tolerated by all patients, with no short-term complications. In conclusion, using IMRT for prostate cancer increases low rectal toxicity that can be easily managed by APC with a transparent cap attached to the tip of the colonoscope.

Fig. 1 Transparent cap at the tip of the colonoscope.

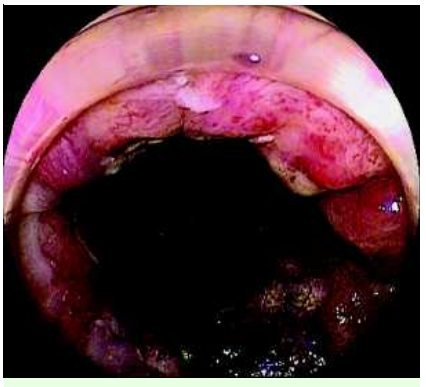

Fig. 2 Visualization of lesions right above the dentate line is facilitated by transparent cap.

Endoscopy_UCTN_Code_TTT_1AQ_2AZ

Video 1

Treatment of radiation-induced distal rectal lesions with argon plasma coagulation and the use of a transparent cap.

R. Coriat, C. Wolfers, U. Chaput, S. Chaussade
Department of Gastroenterology, Cochin Hospital, Université Paris Descartes – Medicine, Paris, France

References

1 *Tagkalidis PP, Tjandra JJ.* Chronic radiation proctitis. ANZ J Surg 2001; 71: 230–237
2 *Postgate A, Saunders B, Tjandra J, Vargo J.* Argon plasma coagulation in chronic radiation proctitis. Endoscopy 2007; 39: 361–365
3 *Veldeman L, Madani I, Hulstaert F et al.* Evidence behind use of intensity-modulated radiotherapy: a systematic review of comparative clinical studies. Lancet Oncol 2008; 9: 367–375

Bibliography

DOI 10.1055/s-2008-1077663
Endoscopy 2008; 40: E270
© Georg Thieme Verlag KG Stuttgart · New York ·
ISSN 0013-726X

Corresponding author

R. Coriat, MD
Department of Gastroenterology, Cochin Hospital
27 rue du faubourg saint Jacques
Paris 75014
France
Fax: +33-1-58411930
romain.coriat@cch.aphp.fr

This document was downloaded for personal use only. Unauthorized distribution is strictly prohibited.