

Idiopathic fibrosing hypertrophic gastritis: a new entity that mimics linitis plastica carcinoma

The author reports a case and proposes a hitherto undescribed entity of “idiopathic fibrosing hypertrophic gastritis”. This entity is characterized by diffuse severe submucosal fibrosis and hypertrophy of the muscularis propria of the stomach, of unknown etiology. This gastritis characteristically simulates linitis plastica carcinoma and causes pyloric stenosis, endoscopically and grossly.

A 55-year-old man presented with loss of appetite. His past history and blood data suggested no relevant factors. Endoscopy showed severe pyloric stenosis and strongly suggested linitis plastica carcinoma (▶ Fig. 1 a); however, biopsies were negative. Total gastrectomy was performed. Pathologic gross examination showed marked thickening of the entire gastric wall (▶ Fig. 1 b). Microscopic examination of the whole stomach showed diffuse marked submucosal fibrosis with inflammation (▶ Fig. 1 c) and diffuse severe hypertrophy of the muscularis propria (▶ Fig. 1 d). The mucosa was free of ulcers and ulcer scars. No carcinoma cells were recognized on microscopic and immunohistochemical studies (cytokeratins, p53, MIB-1, and CEA). Special and immunohistochemical stains showed no amyloid or organisms (*Helicobacter pylori*, *Spirochaeta* spp., Gram-positive bacteria, acid-fast bacteria, cytomegalovirus, and fungi), so the etiology was unknown. Cases like the present one are extremely rare. Such cases of gastritis simulating linitis plastica carcinoma have been reported only twice, in corrosive gastritis [1] and in cytomegalovirus gastritis [2]. The etiology of the present case is unknown, and only speculative. Congenital pyloric stenosis is unlikely because of the patient’s age. Healed gastric ulcer is unlikely because the patient’s past history revealed no relevant factors, and also because it is unlikely that gastric ulcer would lead to severe fibrosis and muscular hypertrophy in the entire stomach. The author speculates that repeated unknown attacking agents caused fibrosis of the gastric walls, causing submucosal fibrosis and pyloric stenosis. To overcome the stenosis, the muscular layer later became hypertrophic.

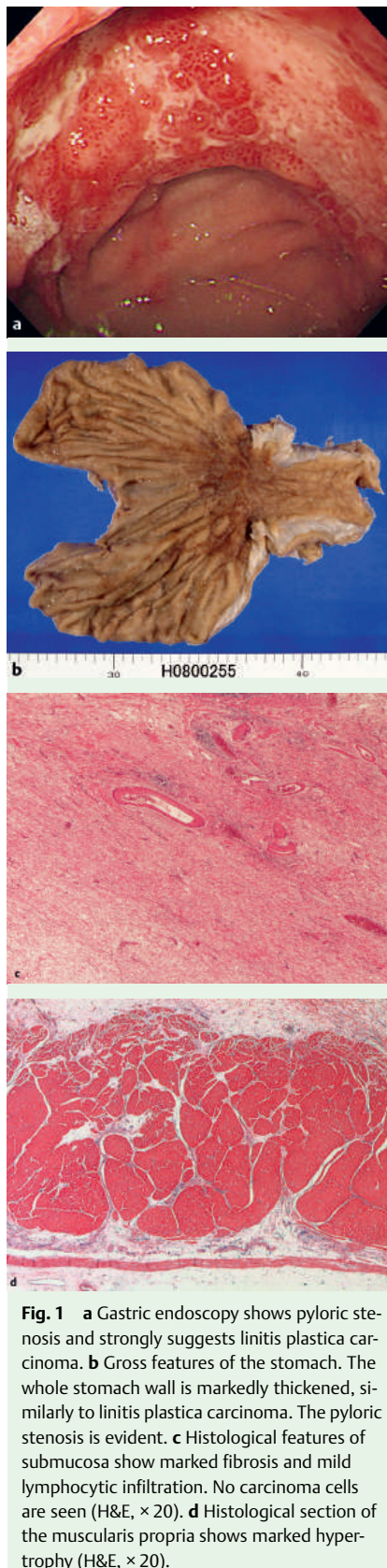


Fig. 1 a Gastric endoscopy shows pyloric stenosis and strongly suggests linitis plastica carcinoma. b Gross features of the stomach. The whole stomach wall is markedly thickened, similarly to linitis plastica carcinoma. The pyloric stenosis is evident. c Histological features of submucosa show marked fibrosis and mild lymphocytic infiltration. No carcinoma cells are seen (H&E, × 20). d Histological section of the muscularis propria shows marked hypertrophy (H&E, × 20).

Endoscopy_UCTN_Code_CCL_1AB_2AD_3AD
Endoscopy_UCTN_Code_CCL_1AB_2AD_3AC

T. Terada

Department of Pathology, Shizuoka Municipal Shimizu Hospital, Shizuoka, Japan

References

- 1 Usui Y, Matsukawa M, Hamada T et al. Corrosive gastritis mimicking linitis plastica carcinoma. *Gastroenterol Jpn* 1989; 24: 398 – 401
- 2 Lagasse JP, Causse X, Legoux JL et al. Cytomegalovirus gastritis simulating cancer of linitis plastica on endoscopic ultrasonography. *Endoscopy* 1998; 30: S101 – S102

Bibliography

DOI 10.1055/s-2008-1077664

Endoscopy 2009; 41: E90

© Georg Thieme Verlag KG Stuttgart · New York · ISSN 0013-726X

Corresponding author

T. Terada, MD, PhD

Shizuoka Municipal Shimizu Hospital
Miyakami 1231

Shimizu-ku

Shizuoka

424-8636

Japan

Fax: +81-54-3341173

piyo0111jp@yahoo.co.jp