

Medial collateral ligament reconstruction during TKA: a new approach and surgical technique

PAOLO ADRAVANTI¹, FRANCESCO DINI², GIUSEPPE CALAFIORE¹, MICHELE ATTILIO ROSA²

¹ Casa di Cura "Città di Parma", Parma, Italy

² Section of Orthopaedics and Traumatology, Department of Biomedical Sciences and Morphological and Functional Images, School of Orthopaedics and Traumatology, University of Messina, Italy

Abstract

Medial collateral ligament (MCL) injuries during total knee arthroplasty are rare but severe complications. They can be treated conservatively, by increasing prosthetic constraint, by using a thicker polyethylene insert, or by directly suturing the ligament. A prosthesis is successful to the extent that it ensures long-term knee stability. We describe our surgical approach to the restoration of knee joint stability in MCL deficiency: a reconstructive technique using the semitendinosus tendon.

Keywords: medial collateral ligament, injury, intraoperative, reconstruction, total knee arthroplasty.

Introduction

The frequency of total knee arthroplasty (TKA), already one of the most commonly performed orthopaedic surgical procedures, is expected to increase exponentially in the near future. Although rare, medial collateral ligament (MCL) injury is one of the most severe complications associated with TKA. Because the MCL is crucial in maintaining stability to valgus stress and because it is the only restraint to valgus

stress in the medial compartment, MCL deficiency in a TKA patient increases the risk of prosthesis failure (1). Primary MCL deficiency, which may be due to excessive valgus or to a previous ligament injury, or may be an outcome of tibial osteotomy with cutting of the MCL, needs to be differentiated from intraoperative injury.

It has been reported that 2.7% of intraoperative injuries during TKA involve the MCL (2) and that they often occur during soft tissue release in the medial compartment, a standard step to correct varus knee and restore soft tissue balance. The procedure entails releasing the deep MCL and the posteromedial capsule, and sometimes also the semimembranosus and the superficial MCL, in which case condylar osteotomy, the pie-crust technique or the subperiosteal sleeve from the tibia can be used to achieve soft tissue balance. In performing these procedures, however, the medial compartment may be opened more than necessary, or the MCL may be ruptured at the joint line due to femoral saw-cut error or during release of the deep MCL or osteophyte removal. Most often these injuries are treated conservatively (3, 4), by increasing the prosthetic constraint (5) or the thickness of the polyethylene insert, or by suturing or reconstructing the MCL (6, 7). We treat these injuries following an algorithm based primarily on where they are located, and we have found reconstruction to be the most reliable technique for achieving a satisfactory clinical outcome. Our preferred method is to use the semitendinosus tendon because of its greater reliability in the reconstruction of an isolated MCL injury and because of its proximity to the surgical site, which means that its harvesting requires a minimally invasive incision and its insertion can be left intact.

Corresponding Author:

Francesco Dini, MD
Section of Orthopaedics and Traumatology, Department of Biomedical Sciences and Morphological and Functional Images, School of Orthopaedics and Traumatology University of Messina
Via Consolare Valeria 1, 98100 Messina, Italy
E-mail: dini.orto@gmail.com

The surgical technique is dictated by the site of the injury: when it involves only the insertion, we prefer to use staples or anchors; if it occurs along the course of the ligament, we reconstruct the MCL using a semitendinosus tendon autograft as described below.

Surgical technique

Harvesting of the semitendinosus tendon

The semitendinosus tendon is harvested by extending by a couple of centimeters the existing skin incision utilized in the primary TKA. The dissection is taken down medially to the sartorius muscle fascia. The fascia is then incised longitudinally along the hamstring fibers between the gracilis and the semitendinosus tendons. Since they usually adhere to the fascia, the tendons should be carefully isolated to avoid damaging the fascia.

The semitendinosus tendon is liberated from its adhesions without detaching it from its insertion. A length of at least 27 cm is obtained with a tendon harvester. After the graft has been harvested, it is folded in half to produce a double-strand graft and a locking suture is placed in the proximal end using thick absorbable suture thread (Vicryl 2, Ethicon, Johnson & Johnson, New Brunswick, NJ). The graft is then passed under the sartorius fascia to the insertion of the superficial MCL.

Preparation of the femoral tunnel

The medial epicondyle (proximal insertion of the MCL) is identified and marked with a dermatographic pen. A guide wire (Kirschner wire) is then positioned (**Fig. 1**) so that it is oriented approximately 20° distal-to-proximal on the frontal plane and perpendicular to the shaft of the femur on the lateral plane. Care should be taken not to interfere with the prosthesis components. The lateral femoral cortical bone is used as an additional prosthetic support base; it is also important to assess the graft kinematics before creating the tunnel. After the femoral tunnel direction has been established using the guide wire, the isometric properties of the graft are tested by wrapping it around the wire and moving the knee joint in flexion and extension. The graft should be neither too lax in flexion nor so tight that it constrains extension. The thickness of the double-bundle graft is then measured and the femoral tunnel is drilled to a length of approx-

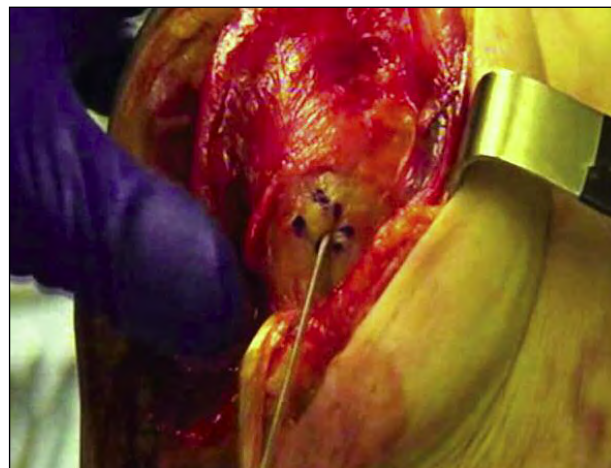


Fig. 1. Direction of the femoral tunnel as established using a Kirschner wire.

imately 25 mm using a bit equal in diameter to the graft thickness. The guide wire is over reamed with a 4.5-mm cannulated drill.

Graft fixation

The graft is then fixed to the femur with an Endobutton (Endobutton CL Ultra fixation device, Smith & Nephew, London, UK). Normally, we use a “long” Endobutton (40-50 mm) to avoid having an overly long tendon graft in the femoral tunnel (**Fig. 2**). During Endobutton fixation to the lateral femoral cortex, the knee is positioned in about 30° flexion with light varus stress. The graft is fixed to the medial cortex with a bioabsorbable screw (BioRCI screw, Smith & Nephew) inside the tunnel (**Fig. 3**).

The free end of the graft is then passed again under the sartorius fascia and stapled to the tibia to reconstruct the superficial MCL, while maintaining the knee flexed at 30° and under light varus stress. The deep MCL is reconstructed using a 3.5-mm suture anchor (Twifix Ti 3.5, Smith & Nephew) with two non-absorbable braided sutures (Ultrabraid, Smith & Nephew), inserted just below the tibial plateau medially, with the knee flexed at 15° and under light varus stress.

Rehabilitation protocol

During the first 30 days after the operation, the patient wears a hinged brace and is allowed limited weight bearing with two crutches for about 40 days. Rehabilitation is begun on the first postoperative day.

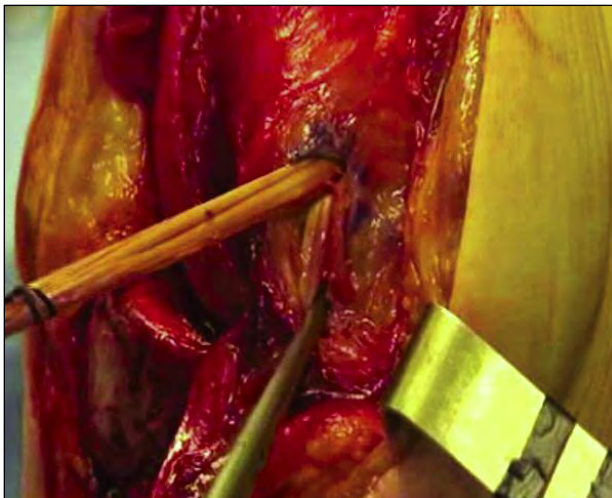


Fig. 2. Passage of the graft in the femoral tunnel.

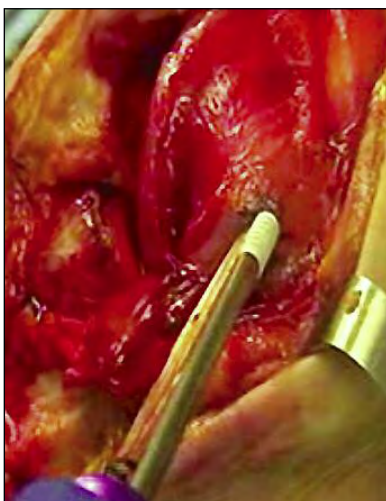


Fig. 3. Fixation of the graft to the medial femoral cortex with a bioabsorbable screw.

Discussion

Intraoperative MCL injury is a rare complication of TKA. Its incidence in our experience is about 0.3% of all complications. Nonetheless, an orthopaedic surgery Department should have the technical means in place to ensure that such injuries can be appropriately

treated. Our experience indicates that MCL injury severity is related to the site of damage. Major difficulties arise in the segment of the MCL at the joint rim where end-to-end sutures and conservative treatment are ineffective and very likely to fail. Other options include augmentation of prosthetic constraint, which may be considered for some patients but not for young, active patients, or use of a thicker polyethylene insert. This, however, requires release of the lateral compartment and raises the joint rim, leading to kinematic imbalance and postoperative pain.

We believe that our repair technique is a valid treatment option in patients with MCL deficiency since it is simple to perform and requires minimal detachment without the need for additional incisions. Should the semitendinosus tendon not be available as, for example, in patients in whom it has been used for previous ligament repair, artificial ligaments, like LARS (Ligament Augmentation & Reconstruction System, Arc-Sur-Tille- France), can provide a good alternative.

References

1. Wijdicks CA, Griffith CJ, Johansen S, et al. Injuries to the medial collateral ligament and associated medial structures of the knee. *J Bone Joint Surg Am.* 2010;92:1266-1280.
2. Leopold SS, Mcstay C, Klafeta K, et al. Primary repair of intraoperative disruption of the medial collateral ligament during total knee arthroplasty. *J Bone Joint Surg Am.* 2001;83-A:86-91.
3. Koo MH, Choi CH. Conservative treatment for the intraoperative detachment of medial collateral ligament from the tibial attachment site during primary total knee arthroplasty. *J Arthroplasty.* 2009;24:1249-1253.
4. Siqueira MB, Haller K, Mulder A, et al. Outcomes of medial collateral ligament injuries during total knee arthroplasty. *J Knee Surg.* 2014 Oct 16. [Epub ahead of print].
5. Lee GC, Lotke PA. Management of intraoperative medial collateral ligament injury during TKA. *Clin Orthop Relat Res.* 2011;469:64-68.
6. Shahi A, Tan TL, Tarabichi S, et al. Primary repair of iatrogenic medial collateral ligament injury during TKA: a modified technique. *J Arthroplasty.* 2015;30:854-857.
7. Stephens S, Politi J, Backes J, et al. Repair of medial collateral ligament injury during total knee arthroplasty. *Orthopedics.* 2012;35:e154-e159.