

## A commentary: To screen for calf DVT or not to screen? The highly variable practice among Italian centers highlights this important and still unresolved clinical option. Results from the Italian MASTER registry

Gualtiero Palareti<sup>1</sup>, Giancarlo Agnelli<sup>2</sup>, Davide Imberti<sup>3</sup>, Marco Moia<sup>4</sup>, Walter Ageno<sup>5</sup>, Riccardo Pistelli<sup>6</sup>, Romina Rossi<sup>2</sup>, Melina Verso<sup>2</sup> for the MASTER investigators

<sup>1</sup>University of Bologna, Bologna, Italy; <sup>2</sup>University of Perugia, Perugia, Italy; <sup>3</sup>Hospital of Piacenza, Piacenza, Italy; <sup>4</sup>IRCCS Maggiore Hospital, Milan, Italy; <sup>5</sup>University of Insubria, Varese, Italy; <sup>6</sup>Catholic University, Rome, Italy, and the MASTER study centers

Dear Sir,

The clinical implications of deep vein thrombosis (DVT) limited to the calf (isolated distal DVT, IDDDVT), involving posterior and anterior tibial veins, peroneal veins and muscular calf veins, are not yet fully ascertained. Little is known about the natural history and clinical risk of this pathology if left untreated; therefore, there is currently no universal consensus on the need to diagnose and treat IDDDVT. Although there is evidence that most DVT episodes start in the calf veins, it is usually thought that the majority become dangerous when they involve the proximal veins. A rate of 10% of proximal extension of untreated distal DVT was calculated in a recent review of available studies involving asymptomatic (post-surgical) and symptomatic patients (1). It has been assumed that in most cases proximal extension occurs within one week from onset (2). This is the basis of the diagnostic procedure, currently considered the standard approach for suspected DVT, that involves a compression ultrasound examination limited to the proximal veins, to be repeated in selected cases after a week to diagnose (and treat) calf vein DVT extending to proximal veins (serial CUS) (3, 4). More recently, a single compression ultrasound investigation of both proximal and distal veins (comprehensive CUS) was shown to be effective and safe (5–8).

Both procedures are currently used clinically and both have their advantages and disadvantages (9). However, the two different diagnostic strategies lead to different results at different vascular centers. This is a cause of uncertainty for health care professionals about what to do in cases with suspected DVT and may also cause an embarrassing discrepancy in the final diagnosis for patients who may or may not receive a diagnosis of venous thrombosis at the vascular center they are referred to.

The present paper reports on the results recorded in the Multicenter Advanced Study for a Thromboembolism Registry (MASTER study), especially focusing on the different diagnostic practice of various Italian centers regarding the diagnostic procedure for suspected DVT and results in patients with isolated calf DVT diagnosis versus those with proximal DVT.

### Results of the MASTER registry

The MASTER registry is an Italian, multicenter, observational study designed to prospectively collect information on patients with acute VTE and treatment practices used in 25 different hospitals (10). Consecutive patients with objectively documented symptomatic VTE were enrolled between January 2002 and October 2004.

Of the 1,772 patients included in the MASTER registry for the presence of DVT in the lower limbs, 170 (9.6%) had an isolated calf DVT (IDDDVT), diagnosed in all cases by a complete ultrasound examination. As shown in Figure 1, the rate of IDDDVT versus the total number of diagnosed DVT greatly differed among the enrolling centers, ranging from zero to 24%. In Table 1 the referring vascular centers are grouped according to classes of diagnosed IDDDVT rates versus the total diagnosed DVT. Table 2 shows some demographic and clinical characteristics of the patients with IDDDVT in comparison to those with proximal DVT. Compared with proximal DVT patients, those with IDDDVT were significantly younger and less often displayed the usual signs/symptoms (pain, edema, erythema) at presentation in the affected leg. A condition of recent surgery or trauma was more often present in IDDDVT than in proximal DVT patients; whereas cancer was less frequent. In contrast with what might have been expected, symptomatic pulmonary embolism (PE) was present in a higher proportion of IDDDVT vs proximal DVT patients (26.5% and 19.9%, respectively,  $p < 0.05$ ).

### Comments

Since a standardized diagnostic procedure had not been recommended or implemented before or during the study among the participant centers, the Master registry reflects the every-day clinical practice of Italian vascular centers as regards diagnosis and treatment of leg DVT. The results recorded confirmed that the diagnostic strategies for suspected leg DVT adopted in Italian centers vary widely, and highlight, in particular, their various approaches to diagnosis and treatment of isolated distal DVT. Some centers use limited serial CUS and do not diagnose (or do so rarely) isolated calf DVT. Others adopt the comprehensive techniques and diagnose IDDDVT cases. It should be noticed,

#### Correspondence to

Prof. Gualtiero Palareti  
Dept. Angiology & Blood Coagulation "Marino Golinelli"  
University Hospital S. Orsola-Malpighi  
Bologna, Italy  
Tel.: +39 051 6362483; Fax +39 051 341642  
E-mail: gualtiero.palareti@unibo.it

#### Financial support:

The Italian MASTER Registry was supported by an unrestricted educational grant from Sanofi-Aventis; the pharmaceutical company had no role in analyzing the data or preparing the manuscript.

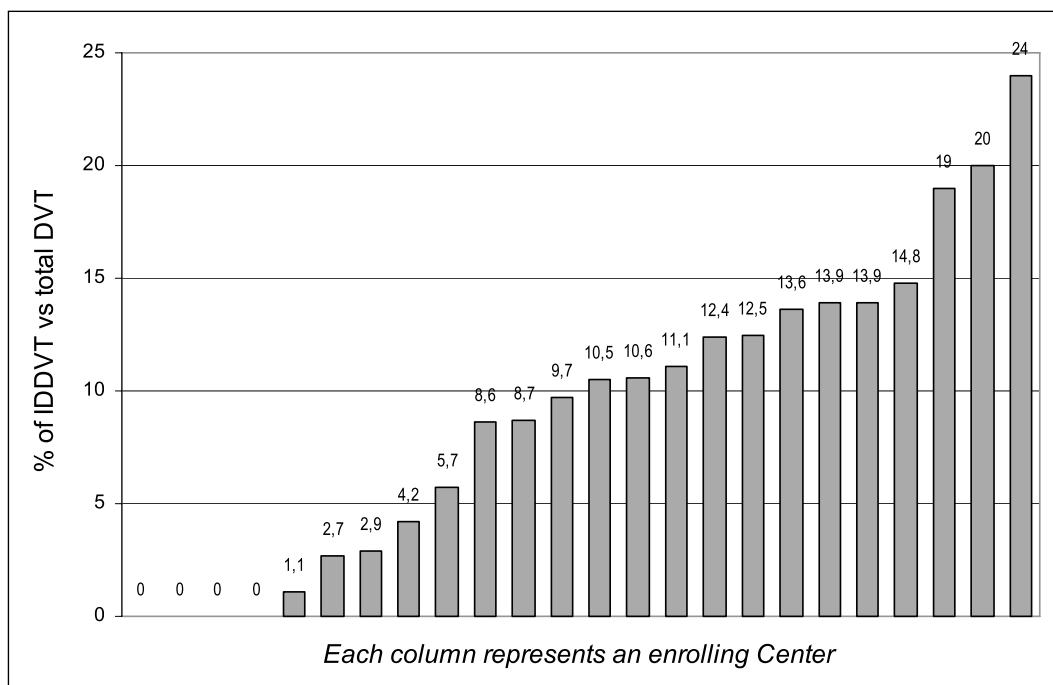
Received June 6, 2007

Accepted after minor revision November 18, 2007

Prepublished online December 5, 2007

doi:10.1160/TH07-06-0393

**Thromb Haemost 2008; 99: 241–244**



**Figure 1: Rate of isolated calf deep vein thrombosis (IDDVT) versus the total deep vein thrombosis (DVT) diagnosed in the MASTER enrolling centers.**

however, that the diagnostic yield of IDDVT varied greatly even among the vascular centers that screened for IDDVT, ranging from < 10% to 24%. This wide diagnostic range can unlikely be explained by differences in characteristics of the patients referring to the centers, since all the enrolled patients were symptomatic for venous thromboembolism. It is more likely that marked inter-operator variability in the diagnostic techniques used accounts for this wide difference.

It should be considered that the clinical results of the serial and comprehensive CUS diagnostic procedures differ in important ways. While serial CUS does not diagnose IDDVT, comprehensive CUS allows the diagnosis of a high rate of IDDVT (from 31% to 47%) (5–8), much higher than that reported in studies using venography (12%) (11). Though clear evidence of the risks associated with this condition is not available, recent clinical guidelines recommend treating distal DVT with anticoagulants for a three-month period (12)). The adoption of the comprehen-

sive CUS strategy therefore leads to a much higher number of subjects requiring anticoagulation, with a not insignificant risk of bleeding complications, which is known to be higher exactly during the first three months of treatment (13). The risks and discomforts of anticoagulation are therefore given to a potentially high number of patients with diagnosed IDDVT, including cases with small thrombi that might have resolved spontaneously without any clinical effects, as well as some false-positive results, due to the lower specificity of CUS in the calf veins (4).

Whether all distal DVTs should be diagnosed and treated or not is still a debatable issue. A recent review analysis (1) has calculated a similar and very good safety profile for both the procedures, with a pooled estimate of the three-month rate of thromboembolic complications of 0.6% (95% CI: 0.4–0.9%) and 0.4% (95% CI: 0.1–0.6%) for the serial and comprehensive CUS, respectively. These data seem to indicate that it is safe to not diagnose and to not treat calf DVT that do not spread to proximal veins.

At first sight, the high rate of PE recorded in the MASTER patients with IDDVT seems to be at odds with this conclusion. This result is also in contrast with what might be expected on the basis of available studies that have consistently shown a higher prevalence of PE in association with proximal versus distal DVT. In line with previous data (14), a recent epidemiological study reported rates of 29% and 46% of associated PE in distal and proximal DVT, respectively (8). Different explanations can be tentatively put forward for this unexpected finding from the MASTER study. First of all, it can be assumed that a DVT confined to the calf is “per sé” a dangerous condition leading to a relatively high PE rate. If this were true, however, many more complications would be recorded when the serial CUS strategy is adopted. Second, many of the IDDVT associated with PE may have formerly been proximal DVT, diagnosed after they had lost

**Table 1: The MASTER registry.** Distribution of centers according to classes of the percentages of isolated distal deep vein thrombosis (IDDVT) versus the total number of diagnosed deep vein thrombosis (DVT).

% of IDDVT	Number of centers	Total number of DVT patients enrolled in the study
0%	5	98
1%-5%	5	496
6%-11%	6	488
12%-20%	8	611
> 20%	1	79

their proximal part. This can obviously occur; however, it is hard to believe that this phenomenon could occur in more than one fourth of the Master patients with IDDVT. Finally, this frequent association may be the result of a more thorough ultrasound investigation by examiners who, being aware of the presence of a PE, are determined to detect a source of emboli and finding nothing in the proximal tract look extra carefully for distal thrombi so as not to leave what would be otherwise unexplained cases with PE. The data described by Masuda et al. (15) support this interpretation. They reported that PE was detected in 15% of patients with IDDVT (diagnosed by ultrasound). All those patients, however, were first seen with PE, the majority of them having no symptoms of DVT in the legs and receiving ultrasound examination in search of a source of the emboli. It can be concluded in this regard that only prospective and blind studies will give us reliable answers about the risk of PE associated with DVT confined to the calf.

In conclusion, our study showed that the Italian vascular centers operate differently with regards to the adoption of the ser-

ial or comprehensive CUS diagnostic procedures to be used in symptomatic patients with suspected leg DVT. A lack of standardization in the diagnostic ultrasound procedures and a high inter-observer variability leads to quite different rates of diagnosed IDDVT even among centers that adopt the comprehensive CUS strategy. Unfortunately, a direct clinical comparison between the two diagnostic strategies is still missing, and how to deal with subjects with suspected or diagnosed calf thrombus is therefore an important issue still open to debate. Prospective, well designed studies on the clinical risks of IDDVT and the advantages/disadvantages of the two diagnostic procedures are urgently needed.

**Table 2: Demographic and clinical characteristics of patients with isolated distal or proximal (with or without distal) deep vein thrombosis (DVT) of the lower limbs enrolled in the MASTER registry.**

	Isolated distal DVT (no. 170)	Proximal DVT (no. 1602)	p
	%	%	
Sex (males)	52.4	50.7	ns
Age Mean age ( $\pm$ SD), y	54.4 (16.1)	60.5 (18.2)	<0.0001
Leg Left (%)	44.1	42.7	ns
Symptoms/signs at presentation:			
Edema	57.1	82.2	<0.0001
Pain	67.6	75.8	<0.05
Erythema	12.4	28.5	<0.0001
None of the above	15.9	5.8	<0.001
Presence of pulmonary embolism at presentation	26.5	19.9	<0.05
Risk factors:			
Cancer	8.8	20.2	<0.001
Surgery	19.4	13.4	<0.05
Pregnancy/puerperium	0.6	3.1	ns
Oral contraceptives	7.1	4.9	ns
Trauma	18.8	8.6	<0.0001
At least one risk factor	48.2	41.6	ns
Treatment:			
Heparin or LMWH	98.2	88.8	<0.001
Heparin or LMWH + VKA	64.7	69.2	ns

### Appendix Members of the MASTER group

**Coordinating Center:** G. Agnelli, M. Verso, R. Rossi (Perugia).  
**Investigator Centers:** W. Ageno: Dipartimento di Medicina Clinica, Università degli studi dell'Insubria, Ospedale di Circolo(Varese); M. Bellisi: Chirurgia Vascolare, Policlinico Paolo Giaccone (Palermo); M. Bianchi: Medicina Generale, Ospedale Valduce(Como); V. Brancaccio: Unità Emostasi-Trombosi, Divisione di Ematologia, Azienda Ospedaliera Cardarelli (Napoli); C. Caponi: Divisione di Medicina Interna e Cardiovascolare, Azienda Ospedaliera S. Maria della Misericordia(Perugia); A. Ciampa: U.O.S.S. "Centro Emostasi", AORN "S. G. Moscati" (Avellino); C. Cimminiello: Ambulatorio di diagnostica vascolare non invasiva U.O.C. Medicina 2, Azienda Ospedaliera "Ospedale Civile" (Vimercate- Milano); A. Dragani: Dipartimento di Ematologia, Servizio delle malattie emorragiche e trombotiche, Ospedale Civile dello Spirito Santo (Pescara); S. Grifoni: DEA, Ospedale Careggi (Firenze); D. Imberti: Centro Trombosi, Medicina Interna-Area Critica, Ospedale di Piacenza (Piacenza); A. M. Impagliatelli: Dipartimento Cardiovascolare U.O.S. Angiologia, IRCCS Casa del Sollievo e della Sofferenza (S. Giovanni Rotondo-Foggia); G. Iovane: Reparto di Chirurgia d'Urgenza, Day-Surgery, Angiologia-ambulatorio di diagnostica e terapia vascolare, Azienda Ospedaliera Bianchi Melacrino Morelli (Reggio Calabria); R. Margheriti: U.O.C. Medicina Generale, Ospedale G. B. Grassi (Rome); M. Moia: Centro Emofilia e Trombosi Bianchi Bonomi, Fondazione IRCCS Ospedale Maggiore Policlinico, Mangiagalli e Regina Elena di Milano (Milan); S. Musumeci: Clinica Chirurgica, Sezione di Patologia Vascolare, Ospedale di Vittorio Emanuele II (Catania); G. Palareti: U.O. Angiologia e Malattie della Coagulazione "Marino Golinelli" (Bologna); M. Pini: Medicina II, Ospedale di Fidenza (Fidenza-PR); P.A. Pittaluga: Medicina Generale II, Ospedale di Galliera (Genova); V. Prisco: U.O. Angiologia Medica, ASL SA/2 c/o Ospedale di Mercato San Severino (Salerno); S. Rupoli: Clinica ematologia, Azienda Ospedaliero-Universitaria, Ospedali Riuniti (Ancona); G. Scannapieco: S.C. Qualità, Piani e Programmi, Azienda ULSS 9 (Treviso); S.S. Signorelli: U.O. Angiologia Medica, Dipartimento di Medicina Interna e Patologie Sistemiche, Ospedale Garibaldi (Catania); M. Silingardi: U.O. I° Medicina Interna, Centro Emostasi e Trombosi, Azienda Ospedaliera S. Maria Nuova (Reggio Emilia); S. Siragusa: U.O. di Ematologia con trapianto, Policlinico Universitario (Palermo); V. Virgilio: S. C. di Chirurgia Vascolare, Ospedale Garibaldi-Nesima (Catania).

### References

- Righini M, Paris S, LeGal G, et al. Clinical relevance of distal deep vein thrombosis – Review of literature data. *Thromb Haemost* 2006; 95: 56–64.
- Kearon C. Natural history of venous thromboembolism. *Circulation* 2003; 107: 122-130.
- Lensing AWA, Prandoni P, Brandjes D, et al. Detection of deep-vein thrombosis by real-time B-mode ultrasonography. *N Engl J Med* 1989; 320: 342–345.
- Kearon C, Julian JA, Newman TE, et al. Noninvasive diagnosis of deep venous thrombosis. *Ann Intern Med* 1998; 128: 663–677.
- Elias A, Mallard L, Elias M, et al. A single complete ultrasound investigation of the venous network for the

diagnostic management of patients with a clinically suspected first episode of deep venous thrombosis of the lower limbs. *Thromb Haemost* 2003; 89: 221–227.

6. Schellong SM, Schwarz T, Halbritter K, et al. Complete compression ultrasonography of the leg veins as a single test for the diagnosis of deep vein thrombosis – A prospective clinical outcome study. *Thromb Haemost* 2003; 89: 228–234.

7. Stevens SM, Elliott CG. Single complete compression ultrasonography for suspected deep venous thrombosis: Ideal in routine clinical practice? Response. *Ann Intern Med* 2004; 141: 889.

8. Seinturier C, Bosson JL, Colonna M, et al. Site and clinical outcome of deep vein thrombosis of the lower

limbs: an epidemiological study. *J Thromb Haemost* 2005; 3: 1362–1367.

9. El Kheir D, Buller H. One-time comprehensive ultrasonography to diagnose deep venous thrombosis: is that the solution? *Ann Intern Med*. 2004;140:1052–3.

10. Agnelli G, Verso M, Ageno W, et al. The MASTER registry on venous thromboembolism: Description of the study cohort. *Thromb Res* 2007, [in print].

11. Cogo A, Lensing AWA, Prandoni P, et al. Distribution of thrombosis in patients with symptomatic deep vein thrombosis – implications for simplifying the diagnostic process with compression ultrasound. *Arch Intern Med*. 1993; 153: 2777–2780.

12. Buller HR, Agnelli G, Hull RD, et al. Antithrombotic therapy for venous thromboembolic disease. *Chest* 2004; 126: 401S–28S.

13. Palareti G, Leali N, Coccheri S, et al. Bleeding complications of oral anticoagulant treatment: an inception- cohort, prospective collaborative study (ISCOAT). *Italian Study on Complications of Oral Anticoagulant Therapy*. *Lancet* 1996; 348: 423–438.

14. Girard P, Musset D, Parent F, et al. High prevalence of detectable deep venous thrombosis in patients with acute pulmonary embolism. *Chest* 1999; 116: 903–908.

15. Masuda EM, Kessler DM, Kistner RL, et al. The natural history of calf vein thrombosis: lysis of thrombi and development of reflux. *J Vasc Surg* 1998; 28:67–74.

---