

Case report

Open Access

Acute median nerve palsy due to hemorrhaged schwannoma: case report

Mehmet Dumlu Aydin*¹, Dilcan Kotan² and Muzaffer Keles³

Address: ¹Department of Neurosurgery, Medical Faculty, Ataturk University, Erzurum, Turkey, ²Neurology Clinic of Batman State Hospital, Batman, Turkey and ³Department of Pathology, Medical Faculty, Ataturk University, Erzurum, Turkey

Email: Mehmet Dumlu Aydin* - nmda11@hotmail.com; Dilcan Kotan - dilcankotan@yahoo.com; Muzaffer Keles - mkeles@atauni.edu.tr

* Corresponding author

Published: 24 September 2007

Received: 17 June 2007

Journal of Brachial Plexus and Peripheral Nerve Injury 2007, **2**:19 doi:10.1186/1749-7221-2-19

Accepted: 24 September 2007

This article is available from: <http://www.JBPPNI.com/content/2/1/19>

© 2007 Aydin et al; licensee BioMed Central Ltd.

This is an Open Access article distributed under the terms of the Creative Commons Attribution License (<http://creativecommons.org/licenses/by/2.0>), which permits unrestricted use, distribution, and reproduction in any medium, provided the original work is properly cited.

Abstract

Schwannomas are common, benign nerve tumors originating from the sheath of peripheral nerves. In this article, a 54 year old woman suffered from sudden onset motor and sensory deficit at her first radial three fingers on her right hand. Radiological investigations were normal. Electromyography diagnosed a median nerve entrapment neuropathy and urgent surgery was performed. Interestingly, a hemorrhaged mass was detected in the median nerve at the proximal end of the carpal ligament and was resected totally. Histopathological diagnosis was Schwannoma. The patient maintained a healthy status for five years.

Background

Although peripheral nerve tumors are rare, the median nerve (MN) is one of the most affected peripheral nerves [1]. Schwannomas arising from Schwann cells are usually benign tumors and comprise 0.8% to 2% of all hand tumors [2]. The tumor is usually seen as a painless, asymptomatic mass. Pain, paresthesias and motor weakness may occur when the tumor reaches sufficient size. They are easily separated from surrounding tissues [3]. Lipoma, lipofibroma, hamartoma and intraneuronal hemangioma should be considered in differential diagnosis [4]. Electromyography (EMG) [5], computed tomography (CT), magnetic resonance imaging (MRI) and ultrasonography are very useful in diagnosis [6,7]. Surgical therapy results in excellent results in 90% of patients [1].

Case Presentation

A 54-year old woman was admitted with a history of abrupt weakness and sensory loss at her radial three fin-

gers on her right hand. She had suffered from pain, aching, burning, tingling, numbness, weakness and clumsiness in the first fingers of her right hand for two months. In neurological examination, sensory loss and flexion paralysis were detected in her radial three fingers. Tinel's sign and Phalen's wrist flexion test were positive. EMG indicated mild median nerve compression at the carpal tunnel with a 4.10 ms distal motor latency and 33.2 m/s sensory nerve conduction velocity of the index finger. MRI did not show a lesion at the course of MN. Carpal tunnel syndrome was considered, and urgent operation was planned. The patient underwent standard carpal tunnel exploration. After release of the transverse carpal ligament, the median nerve was explored. Interestingly, a pulsatile and fusiform bulging was observed on the MN just proximal to the carpal ligament. When the MN sheath was incised along the bulging segment, black cherry juice like fluid leaked spontaneously and a reddish tumoral mass, 2 × 3 mm in diameter, was observed and resected completely without neural lesioning (Fig. 1). Histopatho-

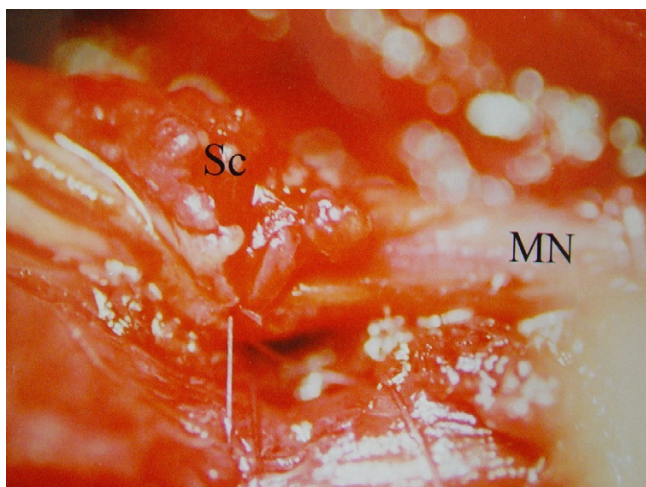


Figure 1
Median nerve (MN) and Schwannoma mass (Sc) are seen intraoperatively.

logical analysis was Schwannoma (Fig. 2). The patient healed completely three months after surgery.

Discussion

Tumors of the peripheral nerves are rare [8,9]. Schwannomas arise sporadically and also occur with some forms of neurofibromatosis [8]. Schwannomas are benign, slowly growing, encapsulated neoplasms and are easily separated from the surrounding tissues. Some forms may be localised within nerve trunk or bundles of neurofibrils spreading over the surface of the tumor. Schwannomas can compress the motor and sensorial branches of the MN

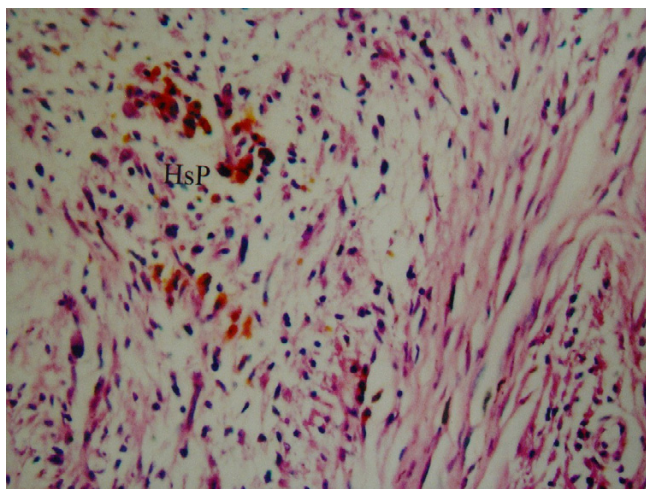


Figure 2
Hypercellular-hypocellular regions, hyalinised blood vessels and hemosiderin pigment (HsP) collections are observed (LM, H&E, ×100).

and may cause aching, burning, tingling, numbness, weakness and clumsiness in the radial half of the hand and radial three digits [10]. They may be easily resected nearly in all cases without causing any complication [3,8].

Schwannomas may be benign or malignant [4]. Histologically, they are composed of two types of cells: The Antony A, which are dense spindle cells, and the Antony B, which are loosely arranged cells [8]. The MN may show hemorrhagic necrosis in some malignant forms of Schwannoma [11]. However, the cause of acute MN palsy in the present case was bleeding of a benign Schwannoma.

In the differential diagnosis, lipoma, lipofibroma, hamartoma and intraneuronal hemangioma must be considered [4]. EMG studies may reveal prolonged sensory latency and diminished or absent sensory evoked potentials [5]. CT and MRI also give useful information regarding tumor extent, anatomical location, tumor size, relationship of peripheral nerve and for appropriate planning of surgical therapy and preoperative diagnosis. Schwannoma is a slightly hypodense, solid tumor with no vascular contrast enhancement on CT. T1-W MRI shows intermediate signals, and T2-W imaging shows high signal intensity with some heterogeneity [6,12]. Although CT and MRI can provide useful information about morphological data on the MN tumors, they cannot provide dynamic information. Conversely, ultrasonography gives detailed informative images of MN during static and dynamic positions such as active and passive flexion and extension maneuvers, showing the nerve in relation to the surrounding musculotendinous structures [7].

Surgical excision is the most effective method of therapy, and total recovery is about 90%, though Plexiform neural tumors may exhibit recurrence and malignant transformation in some cases [1,13]. Paresthesia is the most frequent postoperative complication in these patients [1]. Nerve grafting may also be required in some malignant forms of these tumors [11].

Conclusion

In the presented case, intratumoral hemorrhage was responsible for the acute MN palsy. In carpal tunnel syndrome cases, tumoral lesions should be considered in differential diagnosis. To our knowledge, acute median nerve palsy due to intratumoral Schwannoma hemorrhage has not previously been reported in the literature. This should be added to the list of differential diagnoses of acute MN palsy.

Competing interests

The author(s) declare that they have no competing interests.

Authors' contributions

MDA performed surgery, played role in clinical evaluation and treatment protocol. DK conducted electromyography and interpreted results. MK evaluated histopathology. All authors read and approved the final manuscript.

References

1. Lee SH, Jung HG, Park YC, Kim HS: **Results of neurilemoma treatment: a review of 78 cases.** *Orthopedics* 2001, **24**:977-80.
2. Harkin JC, Reed RS: **Tumors of the peripheral nervous system.** Washington DC, Armed Forces Institute of Pathology 1968:110-6.
3. Phalen G: **Neurilemmomas of the forearm and hand.** *Clin Orthop* 1976, **114**:212-22.
4. Louis D: **Peripheral nerve tumors of the upper extremity.** *Hand Clin* 1987, **3**:311-8.
5. MacDonell RAL, Schwartz MS, Swash M: **Carpal Tunnel Syndrome: Which finger should be tested? An analysis sensory conduction in digital branches of the median nerve.** *Muscle Nerve* 1990, **13**:601-6.
6. Hems TE, Burge PD, Wilson DJ: **The role of magnetic resonance imaging in the management of peripheral nerve tumours.** *J Hand Surg* 1997, **22**:57-60.
7. Kuo YL, Yao WJ, Chiu HY: **Role of sonography in the preoperative assessment of neurilemoma.** *J Clin Ultrasound* 2005, **33**:87-9.
8. Mintz A, Carneiro R: **Schwannoma associated with anomalous division of the median nerve. Case report.** *Neurosurgery* 1989, **25**:965-8.
9. Charitides J, Charisopoulos G, Tsakonas A: **Neurilemoma of the median nerve in a child. Case report.** *Chir Organi Mov* 2000, **85**:281-3.
10. Josty IC, Sykes PJ: **An unusual Schwannoma of the median nerve: effects on the motor branch.** *Br J Plast Surg* 2001, **54**:71-3.
11. Haussmann P: **Malignant Schwannoma of the median nerve.** *Handchir Mikrochir Plast Chir* 1988, **20**:147-9.
12. Zingale A, Consoli V, Tigano G, Pero G, Albanese V: **CT morphology of a median nerve neurilemoma at the arm. Case report and review.** *J Neurosurg Sci* 1993, **37**:57-9.
13. Williams GD, Hoffman S, Schwartz IS: **Malignant transformation in a plexiform neurofibroma of the median nerve.** *J Hand Surg* 1984, **9**:583-7.

Publish with **BioMed Central** and every scientist can read your work free of charge

"BioMed Central will be the most significant development for disseminating the results of biomedical research in our lifetime."

Sir Paul Nurse, Cancer Research UK

Your research papers will be:

- available free of charge to the entire biomedical community
- peer reviewed and published immediately upon acceptance
- cited in PubMed and archived on PubMed Central
- yours — you keep the copyright

Submit your manuscript here:
http://www.biomedcentral.com/info/publishing_adv.asp

