For surgical treatment of postoperative lymphocels after surgery for recurrent varicosis

P.-M. Baier; Z. T. Misczcak
Venen-Clinic Bad Neuenahr, Chirurgische Abteilung

Keywords
Lymphatic complications, recurrent varicosis, postoperative lymphocysts, surgical therapy

Summary
The case reports are presented by two patients who had to undergo surgery for severe recurrent varicosis. In the postoperative course, large and clinically relevant lymphocysts developed. Despite intensive conservative therapy, it progressed. Due to the pronounced findings, the indication for operative cyst resection was asked. The subsequent postoperative course was uncomplicated and there was complete restitution. In principle, operations with recurrent varicosis are expected to be twice as likely to cause postoperative lymphatic complications.

Schlüsselwörter
Lymphatische Komplikationen, Rezidivvarikose, postoperative Lymphozelen, chirurgische Therapie

Zusammenfassung
Es werden die Kasuistiken von zwei Patienten dargestellt, die wegen einer ausgeprägten Rezidivvarikose operiert werden mussten. Im postoperativen Verlauf entwickelten sich große und klinisch relevante Lymphozelen im Bereich der Innenseite des Ober- beziehungsweise Unterschenkels. Trotz intensiver konservativer Therapie kam es zur Progredienz. Aufgrund der ausgeprägten klinischen und sonographischen Befunde wurde die Indikation zur operativen Zystenresektion gestellt. Der anschließende postoperative Verlauf gestaltete sich komplikationslos und es kam zur vollständigen Restitution. Prinzipiell ist bei Operationen wegen einer Rezidivvarikose mit einem doppelt so hohem Risiko an postoperativen lymphatischen Komplikationen zu rechnen.

Correspondence to:
Dr. med. Peter-Matthias Baier
Chirurgische Abteilung
Venen-Clinic
Hochstraße 23
53474 Bad Neuenahr
E-Mail: drbaier309@gmail.com

Zur operativen Therapie postoperativer therapieresistenter Lymphozelen nach Eingriffen wegen einer Rezidivvarikose
Phlebologie 2018; 47: 127–131
https://doi.org/10.12687/phleb2403-3-2018
Received: 10. November 2017
Accepted: 31. Januar 2018

Postoperative lymphoceles (synonym: lymphatic pseudocysts) are very common after operations for recurrent varicose veins. They are a usually harmless complication and often unpleasant and bothersome only in the immediate postoperative period (1, 2, 5, 7, 11, 12). In the majority of cases they are self-limiting and treated simply by wearing compression stockings; other simple conservative measures such as local compression bandages may sometime be needed for compete healing. On the other hand, if they become very large or develop in areas where they threaten other structures, ultrasound-guided aspiration of the lymphocele may be required.

In isolated cases, the postoperative course may be complicated and a second surgical intervention needed once all conservative measures have been exhausted.

We are reporting two cases of patients whom we have seen in the last two years, where we were forced to resect the cysts during revision surgery.

Case report 1

The 57-year-old patient with a body mass index (BMI) of 36 developed bilateral multiple recurrences of varicose veins with convoluted inguinal veins, an incompetent lateral accessory saphenous vein (LASV), and dermatolipofasciosclerosis (C5 of the CEAP classification). He required revision surgery in both groins to eliminate the pathological inguinal reflux and remove the varicose veins, with proximal ligature of the LASV. Varicose tributaries were removed in the same session, and areas of phlebitis, phlebosclerosis and fat necrosis in the lower leg were excised, with transfascial ligation of the incompetent perforators. The operation was carried out under general anaesthetic with a laryngeal mask airway (LMA); the mean operating time (skin-to-skin) was 125 min. Fondaparinux was given as thromboprophylaxis for 14 days after surgery. The patient's physical status was classed as American Society of Anesthesiologists (ASA) II. In addition, he had grade I chronic primary lymphoedema of both legs. His immediate postoperative recovery was unremarkable and he was discharged on day 2 postop. with normal wound healing and flat-knit class II compression hosiery (size A-G). When he returned for outpatient follow-up on day 10, both clinical and ultrasound examinations showed a lymphocele in the proximal medial aspect of the left lower leg. This was treated with a local compression bandage

Dieses Dokument wurde zum persönlichen Gebrauch heruntergeladen. Vervielfältigung nur mit Zustimmung des Verlages.

© Schattauer 2018

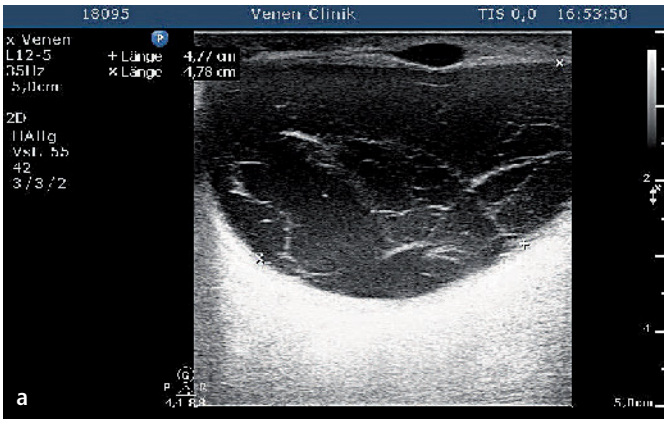

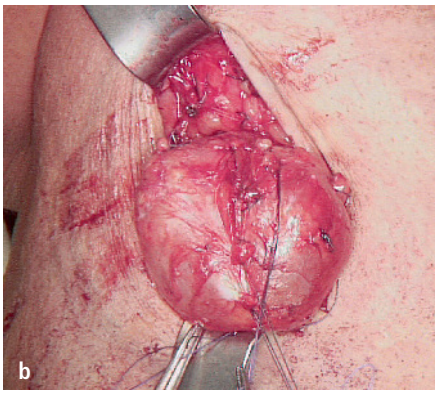

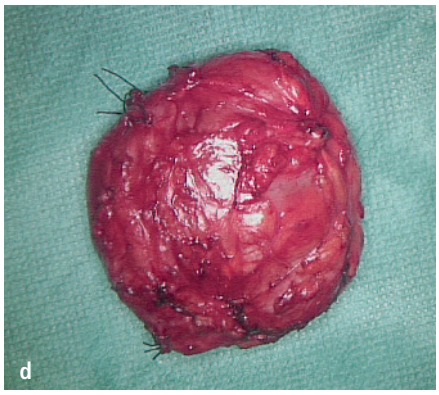

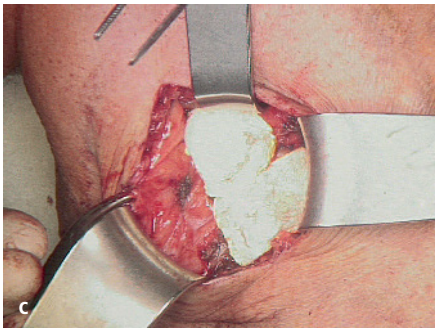

Fig. 1a-d
Ultrasound findings (a) with an indication for surgical cystectomy (b). A fibrinogen/thrombin/collagen sealant matrix (TachoSil) was inserted to aid tissue sealing (c). Macroscopic examination showed a regularly shaped nodular cystic structure weighing 58 g and measuring 5 cm across (d).

in addition to the compression stocking. Four days later, the patient came back with severe pain, signs of local inflammation, and an expanding lymphocele. There was no leucocytosis or raised C-reactive protein (CRP) levels. Ultrasound scanning showed an epifascial lymphocele measuring 4 x 5 cm. We aspirated 80 ml serous fluid and applied a local compression bandage. A short time later, the cyst had refilled, so that we aspirated a further 40 ml serous fluid on day 20 postop. There were still no signs of infection; the full blood count and CRP were in the normal range. In addition to the flat-knit compression stockings, a local compression bandage was applied and manual lymphatic drainage performed twice a week.

Three weeks later, the patient developed erysipelas of the distal left leg, associated with fever, shaking chills, swelling and erythema; there was leucocytosis and the CRP rose to 59 mg/l (normal range: 0.1–5.0 mg/l). He was admitted to hospital. His leg was placed in a Braun's splint and local antiseptic dressings with Povidone iodine solution were applied. He was given antibiotic therapy with intravenous aminopenicillin, thromboprophylaxis with fondaparinux and analgesic/anti-inflammatory medication. The tissue inflammation regressed completely on this treatment and the patient left hospital with a normal CRP and no fever. Colour duplex ultrasound showed an unchanged 4 x 4 cm lymphocele, with no signs of inflammation, on the medial aspect of the proximal leg: the conservative treatment with flat-knit class II compression stockings was therefore continued. Despite this treatment, the lymphocele did not regress.

Six months after the primary intervention, the patient returned because of pain and swelling in the left lower leg. Ultrasound showed no change in the approximately 4 x 4 cm chambered cystic mass on the medial aspect of the proximal leg. The clinical symptoms and ultrasound findings provided an indication for surgical cystectomy. The operation was performed in hospital under general anaesthetic (LMA); the operating time was 95 minutes. At operation, a 5 x 6 cm lymphocele was gradually dissected out until completely resected. The feeder lymphatic vessels in the proximal part were separated and tied with suture ligatures. In addition to a Redon drain, a fibrinogen/thrombin/collagen sealant matrix (TachoSil) was inserted into the former cyst bed to aid tissue sealing. Primary wound closure and a compression bandage followed. The patient was given antibiotic therapy with i.v. aminopenicillin for three days; thromboprophylaxis with fondaparinux was continued until day 14 postop.

Macroscopy showed a regular nodular cystic structure weighing 58 g and measuring 5 cm across. Immunohistochemistry confirmed the diagnosis of a lymphocele.

The postoperative recovery was uneventful. Repeat ultrasound after 6 weeks was unremarkable apart from discrete residual scarring in the surgical field (▶ Figs. 1a to 1d).

Case report 2

The 76-year-old ASA III patient with a BMI of 26 was on long-term anticoagulation therapy with phenprocoumon for atrial fibrillation. She had to have surgery for recurrent varicose veins with pathological inguinal reflux due to an incompetent LASV, varicose tributaries, and convoluted varicose veins in the thigh and lower leg, CEAP class C4. Under general anaesthetic

Dieses Dokument wurde zum persönlichen Gebrauch heruntergeladen. Vervielfältigung nur mit Zustimmung des Verlages.

© Schattauer 2018

(LMA), she had revision surgery in both groins with removal of the inguinal varicose veins, proximal LASV ligature, and hook phlebectomy of the varicose tributaries and larger varicose veins. Operating time was 95 min. She was given thromboprophylaxis with weight-adapted low molecular weight heparin (Nadroparin 0.8 twice daily) for two days postop. She was then restabilised on phenprocoumon according to a bridging schedule. The immediate postoperative recovery was uneventful and the patient was discharged home two days after surgery with normal wound healing and round-knit class II compression stockings (size A-G). After day 10, a firm painful induration developed on the medial aspect of the distal thigh. Ultrasonography showed a 2.5 x 3.5 cm lymphocele with no signs of inflammation. At first, a local compression bandage was applied in addition to the compression stocking and manual lymphatic drainage was prescribed. Four weeks later, the patient presented with persistent local pain associated with swelling in the left thigh. Colour duplex ultrasound showed a 2.5 x 3.5 cm lymphocele on the medial aspect of the distal thigh, unchanged from the previous examination, with a normal appearance of the deep vein system. Given the clinical symptoms, we aspirated 30 ml serous fluid under ultrasound guidance and applied a local compression bandage. Nevertheless, the cyst refilled a week later, causing the same clinical picture. Conservative treatment was continued at first, with the patient wearing compression stockings consistently and receiving twice-weekly sessions of manual lymphatic drainage.

Four months after the primary operation, the painful indurated swelling on the medial aspect of the distal left thigh was unchanged. Ultrasound also confirmed a refractory lymphocele measuring 2.5 x 3.5 cm, with the lymphatic drainage now being disrupted and increased lymph channels developing distal to the lesion. Based on the clinical and ultrasound findings, there was an indication for surgical resection of the cyst.

The operation was performed under general anaesthetic (LMA); the operating time was 75 minutes. At operation, a 3.5 x 3.0 cm encapsulated lymphocele was completely resected from the medial aspect of the left thigh. The feeder lymphatic vessel was identified in the proximal section and tied with a suture ligature. In addition to a Redon drain, a fibrinogen/thrombin/collagen sealant matrix (TachoSil) was inserted into the former cyst bed to accelerate tissue sealing. Primary wound closure and compression bandaging followed. Thromboprophylaxis with weight-adapted low molecular weight heparin (Nadroparin 0.8 twice daily) was gradually switched to phenprocoumon according to a bridging schedule starting on day 2.

Macroscopy showed a structure filled with clear cystic fluid-weighing 36 g and measuring 3.5 x 3.5 x 3.0 cm; the inner and outer wall surfaces were smooth. Immunohistochemistry confirmed the diagnosis of a lymphocele.

The postoperative recovery was uneventful. The patient had no symptoms at follow-up 6 weeks later. Ultrasound showed only isolated residual scarring in the former cyst bed (▶ Figs. 2a to 2c).

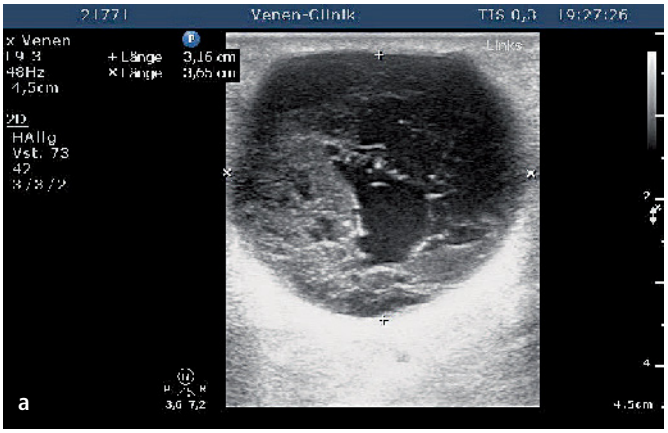

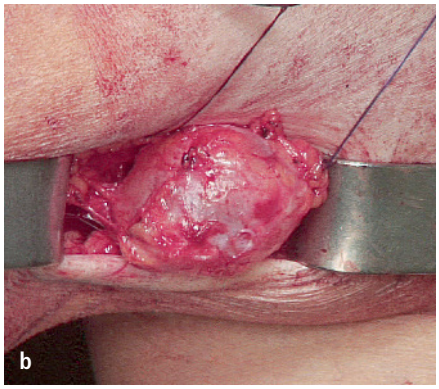

Fig. 2a-c Ultrasound scanning consistently showed a refractory lymphocele measuring 2.5 x 3.5 cm (a), during surgery (b), complete resection of a 3.5 x 3.0 cm encapsulated cyst from the medial aspect of the distal left thigh (c).

Discussion

At a time when alternative forms of treatment and especially endovenous ablation procedures are becoming increasingly popular, varicose vein surgery is today considered easy to learn, quick and straightforward to perform, inexpensive, and carrying only few postoperative risks. But this view is in no way justified by actual clinical practice. Despite all the technical advances and trends towards minimally invasive procedures, the surgery of varicose veins is still very tedious and time-consuming; it requires great surgical skill especially when there are extensive findings, recurrent varicose veins, complications of varicose disease, and progressive chronic venous insufficiency (CVI). These patients are also the ones who also tend to have postoperative complications, thus causing problems for all concerned. Major complications are not the real problem, as they occur in only a few isolated cases; it is the less essential minor complications, especially of lymphatic origin, that are unpleasant and troublesome for the patient and sometimes

Dieses Dokument wurde zum persönlichen Gebrauch heruntergeladen. Vervielfältigung nur mit Zustimmung des Verlages.

require further surgery (1, 2, 4, 5, 7, 9, 12, 13).

Although lymphatic complications of varicose vein surgery are common, this is not really reflected in the literature. Lymphatic complication rates between 0.15% (11) and 6.2% (3) have been reported. In a prospective study published in Phlebologie 3/2018, our rate was 4.5%. Patients with recurrent varicose veins experienced postoperative complications twice as often as patients undergoing primary varicose vein surgery (1).

Postoperative lymphoceles occur frequently and develop when the continuity of the lymphatic channels is disrupted; the lymph cannot flow from a damaged vessel and a pseudocapsule is formed. The course of the anteromedial bundle is at particularly high risk of injury on the medial aspect of the distal leg; this risk increases significantly when advanced CVI, postthrombotic syndrome or pronounced recurrent varicose veins with adhesions are present preoperatively (1, 4, 5, 11–13).

In the majority of cases, employing the full extent of conservative measures – local compression bandages combined with manual lymphatic drainage – leads to adhesion of the damaged lymph vessel, cessation of lymph secretion, and hence complete recovery. Blanket antibiotic prophylaxis is unnecessary. Ultrasound-guided cyst aspiration under aseptic conditions with a local compression dressing should be reserved for large mechanically bothersome cysts, because of the possibility of introducing micro-organisms (5, 11).

Instilling polidocanol foam into persistent refractory lymphoceles seems to be successful in some cases (10). An injection of the antibiotic doxycycline has also been rated positively in the literature. These procedures induce a local inflammatory reaction that leads to extravasation of fibrin, which causes the cyst walls to adhere, thus drying up lymph secretion (6, 8).

If all conventional conservative treatment fails, surgical measures are indicated for persistent or progressive clinically relevant lymphoceles.

Like Hach (5), we are of the opinion that secondary surgery for refractory lymphoceles should generally be performed as an inpatient procedure. Every effort should be made to resect the lesion completely, identifying and dealing with the secretory lymph vessel by either electrosurgical means or ligation. In addition to a Redon drain, we insert a fibrinogen/thrombin/collagen sealant matrix (TachoSil) into the former cyst bed, activating both fibrinogen and thrombin and thus accelerating local tissue sealing. We always strive for primary wound closure and consider it essential to apply a compression bandage.

Conclusions

Postoperative lymphoceles are common after varicose vein surgery; they are mostly harmless and require no special treatment apart from compression.

Only when the full range of conservative treatment options has been exhausted should revision surgery be considered for persistent refractory lymphoceles.

Revision procedures carry more than twice the risk of postoperative lymphatic complications. This fact should be remembered when consenting the patient for operation.

A gentle atraumatic surgical technique with electrosurgical haemostasis is essential, particularly for revision surgery. The surgeon also needs to be experienced and familiar with the anatomy and topography of the lymphatic system.

In areas that are particularly at risk – the anterior aspect of the distal leg and the medial aspect of the knee – recurrent varicose veins should not be treated by hook phlebectomy. Exposure and resection of the varicose veins under direct vision though small longitudinal incisions is less harmful to the lymphatic vessels.

Access routes, surgical strategies, and surgical techniques therefore need to be standardised in-house and reflected in an internal standard operating procedure (SOP).

Conflict of interest

The authors declare that they have no conflicts of interest.

Ethical guidelines

Data used in this manuscript were obtained in compliance with national laws and the current version of the Declaration of Helsinki. The patients gave their informed consent.

References

1. Baier PM, König N, Miszczak ZT, Stark HJ. Lymphatische Komplikationen nach Varizenoperationen bei fortgeschrittener chronisch-venöser Insuffizienz. Phlebologie 2008; 37: 227–282.
2. Balzer K. Komplikationen bei Varizenoperationen. Zentralbl Chir 2001; 126: 537–542.
3. Disselhoff BC, der Kinderen DJ, Moll FL. Is there a risk for lymphatic complications after endovenous Laser treatment versus cryostripping of the great saphenous vein? A prospective study. Phlebology 2008; 23: 4–10.
4. Fischer R, Früh G. Die Varizenoperation beim Vorliegen eines Lymphödems – wann ist sie sinnvoll? Phlebologie 1998; 27: 181–184.
5. Hach W. Venenchirurgie. Stuttgart: Schattauer 2006; S. 155.
6. Hackert T, Werner J, Loos M, Büchler MW, Weitz, J. Successful doxycycline treatment of lymphatic fistula: Report of five cases and review of the literature. Langenbecks Arch Surg 2006; 391: 435–438.
7. Hofer T. Komplikationen nach varizenchirurgischen Eingriffen. Phlebologie 2001; 30: 26–30.
8. Juntermanns B, Cyrek AE, Bernheim J, Hoffmann JN. Manegment von Lymphfisteln in der Leistenregion aus chirurgischer Sicht. Chirurg 2017; 88: 582–586.
9. Kröger K, Lulay G, Miller A. Lymphödeme in der Gefäßchirurgie. Gefäßchirurgie 2016; 21: 572–579.
10. Moritz RKC, Reich-Schupke S, Altmeyer P, Stücker M. Polidocanol – Schaumsklerosierungstherapie von persistierenden postoperativen Seromen nach Varizenoperationen. Vasomed 2013; 25: 199–201.
11. Nüllen H, Noppeney T. Lymphgefäßläsionen bei der Varizenbehandlung. In: Noppeney T, Nüllen H. Diagnostik und Therapie der Varikose. Springer Heidelberg 2010; S 386–388.
12. Öhlbauer M, Mildner A, Brenner E, Hilbe G. Lymphzysten und Fisteln nach Varizenoperationen. Lymphologie in Forschung und Praxis 2000; 4: 11–13.
13. Ouvry PA, Guenneguez H, Ouvry PAG. Les complications lymphatiques de la chirugie des varices. Phlebologie 1993; 46: 563–568.

Dieses Dokument wurde zum persönlichen Gebrauch heruntergeladen. Vervielfältigung nur mit Zustimmung des Verlages.

© Schattauer 2018