

Superficial phlebitis and venous thrombosis of the upper extremity – trivial or not?

A. L. Recke; B. Kahle

Klinik für Dermatologie, Venerologie und Allergologie, UKSH Campus Lübeck

Keywords

Venous thrombosis, upper extremity thrombosis, varicose veins, superficial phlebitis

Summary

Background: In contrast to venous thromboembolism in the lower limbs, reports of thrombosis or phlebitis in the arm are rare.

Methods: A review of different data bases was performed using the following keywords: venous thrombosis, upper extremity, venous catheter, pulmonary embolism, thoracic outlet, varicose veins in upper limbs, superficial phlebitis upper extremity/limb.

Results: Upper extremity thrombosis is often caused by catheters or in accordance to malignancies.

Conclusion: Upper extremity thrombosis is more frequent than supposed and should be examined using duplex ultrasound.

Schlüsselwörter

Phlebitis, Armvenen, Varizen, oberflächliche Thrombophlebitis, Armvenenthrombose

Zusammenfassung

Hintergrund: Armvenenthrombosen (AVT) und oberflächliche Phlebitiden der oberen

Extremität spielen in der phlebologischen Literatur eher eine Nebenrolle.

Fragestellung: Werden AVT und oberflächliche Phlebitiden der Armvenen im klinischen Alltag unterschätzt?

Methodik: Literaturrecherche in medizinischen Datenbanken unter Verwendung folgender Stichworte: venous thrombosis, upper extremity, venous catheter, pulmonary embolism, thoracic outlet, varicose veins in upper limbs, superficial phlebitis upper extremity/limb

Ergebnisse: AVT treten bevorzugt nach Anlage von Venenkathetern oder Venenverweilkanülen auf. Malignome sind an zweiter Stelle als ätiologisch relevant zu nennen. Neurovaskuläre Kompressionssyndrome spielen eine untergeordnete Rolle. Oberflächliche Phlebitiden der Armvenen finden in der Literatur wenig Erwähnung, die Erkenntnisse sind heterogen.

Zusammenfassung: AVT sind häufiger als erwartet und oft klinisch stumm. Phlebitiden, die in Verbindung mit einer Venenverweilkanüle auftreten, sollten duplexsonographisch abgeklärt werden. Weitere Studien, insbesondere zur Rolle der oberflächlichen, katheterassoziierten Phlebitiden, wären wünschenswert.

Oberflächliche Phlebitis und Venenthrombose der oberen Extremität – banal oder nicht?

Phlebologie 2018; 47: 335–337

<https://doi.org/10.12687/phleb2447-6-2018>

Received: 24. August 2018

Accepted: 24. August 2018

Correspondence to:

Prof. Dr. med. B. Kahle
Klinik für Dermatologie, Venerologie und Allergologie
UKSH Campus Lübeck
Ratzburger Allee 160
23538 Lübeck
E-Mail: Birgit.Kahle@uksh.de

Introduction

The current guidelines on thrombosis (1) reflect the enormous growth in knowledge regarding the diagnosis and treatment of deep vein thrombosis and pulmonary arterial embolism. Deep vein thrombosis of the legs has a predominant position here – in stark contrast to thrombosis of the upper extremities. In addition, no clear diagnostic algorithm has been described to clarify a suspected thrombosis of an arm vein (AVT).

The section of the guidelines that discusses thrombophlebitis deals with superficial thrombosis of the legs, varicophlebitis of the legs, but not phlebitis of the superficial arm veins (1). In everyday clinical practice, this often occurs as phlebitic irritations associated with the insertion of a short indwelling venous catheter. Thromboses are more commonly described after insertion of a central venous catheter into the preferred internal jugular vein, rather than the rarely used arm veins.

Bleker et al. (2) describe thromboses in the basilic and cephalic veins as superficial vein thrombosis in the arm and differentiate these from the deep AVTs in the brachiocephalic, jugular, subclavian, brachial, ulnar and radial veins.

Regarding the anatomy of the arm veins, it is worth mentioning that the deep sections of the brachial vein are only relatively short compared to the superficial cephalic and basilic veins, that are often of a larger calibre (3) (► Fig. 1). This means that a superficial vein thrombosis (SVT) in the arm veins can also trigger a pulmonary arterial embolism directly – and not via perforators in the deep vein.

The following questions arise concerning superficial phlebitis and venous thrombosis of the upper extremity:

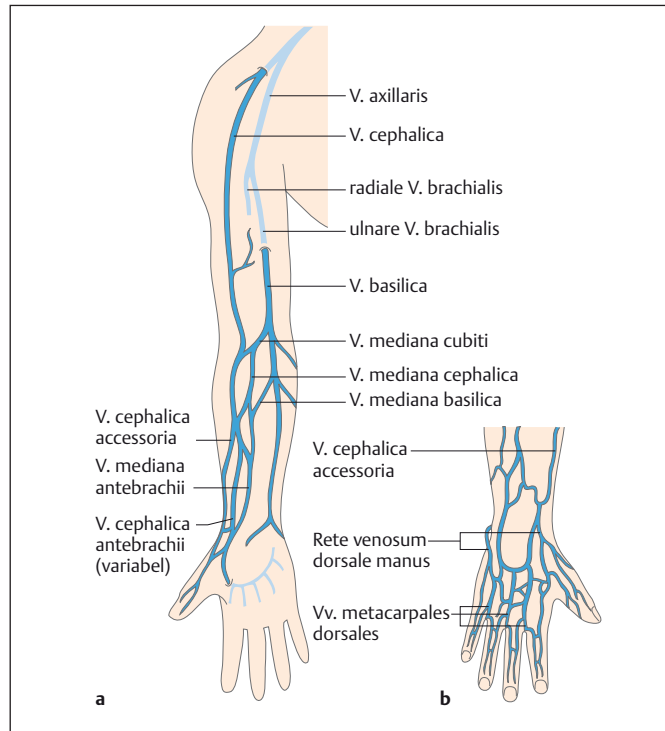


Fig. 1

Superficial veins of the arm and hand (Source: Voß R. Der venöse Blutabfluss. In: Bommas-Ebert U, Teubner P, Voß R, Eds. *Kurzlehrbuch Anatomie und Embryologie*. 3. Edition. Stuttgart: Thieme; 2011. doi:10.1055/b-002-21536).

Are superficial phlebitis and venous thromboses of the upper extremity underestimated in routine clinical practice?

Is catheter-associated phlebitis of the superficial arm veins a relevant and serious condition that needs further diagnosis and treatment?

Methods

We performed a literature search in the databases PubMed, EMBASE and the Cochrane Library with the search terms “venous thrombosis”, “upper extremity”, “venous catheter”, “pulmonary embolism”, “thoracic outlet”, “varicose veins in upper limbs”, “superficial phlebitis upper extremity/limb”. In addition we also entered the search terms in the indices and archives of the journals *Phlebologie* and *Vasomed*.

Results

12 publications could be identified whose results could be evaluated in terms of the research question.

Epidemiology

According to the data of Isma (4) and Cote (5), the percentage of arm vein thromboses (AVT) in all annually occurring deep vein thromboses is 5–6.1% (3, 4). Analysis of the data of the Registro Informatizado de Enfermedad Trombo Embólica (RIETE), revealed that 6.1% of thromboses were AVT, 3.6% non-catheter-associated and 2.5% catheter-associated (4).

A recent systematic review showed an incidence of deep vein thrombosis (DVT) of 1/1000, of which 4–10% were AVTs (6). An up-to-date analysis from France recorded an even higher rate of 14% AVTs within all deep thromboses of the extremities (7). Overall, the incidence of AVT has risen in recent years through the increased use of central venous catheters and other foreign material (e.g. heart pacemakers) (6).

The respective figures for incidence relate to thromboembolic events in the arm veins in general, with phlebitis of the superficial arm veins not shown separately. The type of catheter (short or long, puncture site) is usually not systematically recorded in catheter-associated phlebitis either.

Aetiology

Idiopathic or primary arm vein thromboses (AVT) are counted separately from those of the Paget-von Schroetter syndrome (thoracic inlet and outlet syndrome). However, whether an AVT following neurovascular compression should be better described as secondary, is a matter for debate. The primary or idiopathic form of AVT is somewhat rare, accounting for approx. 20% of all AVTs (6, 8).

In 80% of cases, arm vein thromboses occur secondarily (6,8). The most common cause of secondary AVTs is foreign material, i.e. central venous catheters (CVC), peripherally inserted CVC and other foreign material such as heart pacemakers. Malignant diseases are another important aetiological factor for AVT. For example, in a study by Lee et al., a malignant tumour was present in 48% of patients with ATV (n = 94), and 93% had a central venous catheter (9). The extent to which the malignancy itself or the associated more frequent and longer-lasting catheter insertions are of aetiological relevance, is unclear. Surgical operations are the third most common cause of AVTs (6).

A high percentage of AVTs are asymptomatic. Frequencies vary from 10–60%, but a high number of unreported cases is likely (8, 10).

The data on pulmonary arterial embolisms (LAE) as a result of an arm vein thrombosis is heterogeneous. Recent reviews state the frequency of LAE as 3–36% (6); subclinical LAEs appear to have a higher proportion at 33% (11).

Discussion

Due to the fundamentally different anatomy and haemodynamics with higher blood flow and the lack of venous stasis, thromboses in the arm veins – which account for 4–10% of all venous thromboses – are considerably less common than in veins of the lower extremity.

There are no standard recommendations for the diagnosis and treatment of superficial and deep thromboses of the arm veins. If AVT is suspected, Doppler ultrasonography should be performed. If the re-

sults are unclear, imaging techniques can be used as well. Treatment is based on the corresponding recommendations for the lower extremity.

Findings concerning the procedure for superficial phlebitis are few and inconsistent. Prospective studies on catheter-associated phlebitis after insertion of peripheral, rather than central, venous catheters (PVC) would be desirable. From a phlebological perspective as well as in terms of infections, indwelling venous catheters should be closely inspected. Diagnostic duplex ultrasonography should be performed if reddening and/or induration occur. Particular attention should be paid to patients with cancer and those who are immobilised. There are no standard criteria for the choice of a puncture site of the PVC and few systematically recorded data can be found in the literature.

Whereas Cicolini et al. observed fewer cases of phlebitis after PVC insertion into the cubital fossa compared to veins of the hand or forearm (12), Dunda et al. reported the opposite result and observed even particularly severe courses of phlebitis when it originated from PVCs in the cubital fossa (13).

From the perspective of hospital hygiene, the Committee for Hospital Hygiene and Infection Prevention at the Robert Koch Institute (KRINKO) recommends that PVCs inserted during emergency treatment should be replaced within 24 hours and PVCs inserted preferably in veins of the hand or forearm, but not of the elbow (14). Daily inspection – and palpation if necessary – plus daily evaluation of the need for a PVC should detect catheter-associated infections (and hence also phlebitis) at an early stage. There is insufficient data from a hospital hygiene point of view to recommend routine changes of the PVC after 72–96 hours as a compulsory preventative measure (14). However several quoted studies (14) have shown an increased rate of phlebitis when the PVC is left in place for >72–96 hours.

From the few publications that are devoted to superficial phlebitis, it should be remembered that mechanical (manipulation, irritation through the catheter itself), chemical (through the administered medication) and also trigger factors caused by infections with microbial colonisation or catheter infection are of aetiological significance.

Summary

Arm vein thrombosis (AVT) is a serious condition that carries the risk of a pulmonary arterial embolism. The main risk factors for an AVT are venous catheters or foreign material and the presence of a malignancy. Due to the proximity of the superficial arm veins to the deep vein system, phlebitis of the arm veins should not be dismissed as trivial – however, the current sparse data concerning this probably underestimated disease prevents any conclusive assessment.

Peripheral venous catheters should be closely inspected and if phlebitis of the superficial arm veins is suspected, further diagnosis and treatment should be undertaken.

Conflict of interests

The authors state that there is no conflict of interests.

Ethical guidelines

Preparation of the manuscript did not involve any studies on humans or animals.

References

1. Hach-Wunderle V. S2-Leitlinie Diagnostik und Therapie der Venenthrombose und der Lungenembolie. AWMF-Leitlinien-Register Nr. 065/002, Klasse S2k, Stand: 10. Oktober 2015 <http://www.awmf.org/leitlinien/detail/II/065-002.html>
2. Bleker SM, vanEs N, Kleinjan A, Büller HR, Kamphuisen PW et al. Current management strategies and long term clinical outcome of upper extremity

3. Voß R. Der venöse Blutabfluss. In: Bommas-Ebert U, Teubner P, Voß R, Hrsg. *Kurzlehrbuch Anatomie und Embryologie*. 3. Auflage. Stuttgart: Thieme; 2011. doi:10.1055/b-002-21536
4. Isma N, Svensson PJ, Gottsäter A, Lindblad B. Upper extremity deep vein thrombosis in the population based Malmö thrombophilia study (MATS). *Epidemiology, risk factors, recurrence risk and mortality*. *Thromb Res* 2010; 125: e335–8
5. Cote LP, Greenberg S, Caprini JA, Tafur A, Choi C et al., RIETE investigators. Comparisons between upper and lower extremity deep vein thrombosis. *Clin Appl Thromb Hemost* 2017;23:748–54
6. Heil J, Miesbach W, Vogl T, Bechszlein WO, Reinisch A. Deep vein thrombosis of the upper extremity – a systematic review. *Dtsch Arztebl Int* 2017; 114:244–9
7. Delluc A, Le Mao R, Trommeur C, Chambry N, Rault-Nagel H et al. Incidence of upper extremity deep vein thrombosis in Western France: a community based Study. *Haematologica* 2018;103:
8. Sajid MS, Ahmed N, Desai M, Baker D, Hamilton G. Upper limb deep vein thrombosis: a literature review to streamline the protocol for management. *Acta Haematol*. 2007;118(1):10–8. Epub 2007 Apr 10.
9. Lee JA, Zierler BK, Zierler RE. The risk factors and clinical outcomes of upper extremity deep vein thrombosis. *Vasc Endovascular Surg*. 2012 Feb;46(2):139–44. doi: 10.1177/1538574411432145. Epub 2012 Feb 9.
10. Luciani A, Clement O, Halimi P, Goudot D, Portier F et al. Catheter-related upper extremity deep venous thrombosis in cancer patients: a prospective study based on Doppler US. *Radiology*. 2001 Sep;220(3):655–60.
11. Mustafa J, Asher I, Sthoeger Z. Upper Extremity Deep Vein Thrombosis: Symptoms, Diagnosis, and Treatment. *Isr Med Assoc J*. 2018 Jan;20(1):53–57.
12. Cicolini G, Bonghi AP, Di Labio L, Di Mascio R. Position of peripheral venous cannulae and the incidence of thrombophlebitis: an observational study. *J Adv Nurs*. 2009 Jun;65(6):1268–73. doi: 10.1111/j.1365-2648.2009.04980.x. Epub 2009 Apr 3.
13. Dunda SE, Demir E, Mefful OJ, Grieb G, Bozkurt A et al. Management, clinical outcomes, and complications of acute cannula-related peripheral vein phlebitis of the upper extremity: A retrospective study. *Phlebology*. 2015 Jul;30(6):381–8. doi: 10.1177/0268355514537254. Epub 2014 May 20.
14. Empfehlung der Kommission für Krankenhaushygiene und Infektionsprävention beim Robert-Koch-Institut: Prävention von Infektionen, die von Gefäßkathetern ausgehen. Teil 2 – Periphervenöse Verweilkatheter und arterielle Katheter Bundesgesundheitsbl 2017 – 60:207–215, DOI 10.1007/s00103-016-2488-3, Online publiziert: 16. Januar 2017, Springer-Verlag 2017.