

Finger-Thumb Technique for Elephant Trunk Retrieval

Bulat A. Ziganshin, MD, John A. Elefteriades, MD*

Aortic Institute at Yale-New Haven Hospital, Yale University School of Medicine, New Haven, Connecticut, USA

Abstract

In this report we present a brief video illustrating the “Finger-Thumb Technique” that we have used extensively at our institution for elephant trunk retrieval during second stage elephant trunk procedures. Although only safe in experienced hands, this technique is a viable option in the arsenal of a cardiothoracic surgeon, especially in cases when proximally surrounding a massively enlarged aorta is unappealing.

Copyright © 2013 Science International Corp.

Key Words

Descending aorta · Thoracic aortic aneurysm · Surgical treatment · Stage II elephant trunk procedure

Staged open surgical treatment of aneurysms of the aortic arch and descending aorta was first described by Borst [1], and then modified by Crawford [2] and Svensson [3]. The essence of the two-stage procedure is in the “elephant trunk” graft that is inserted into the descending aorta during arch replacement surgery. The elephant trunk graft is left hanging in the lumen of the descending aorta in anticipation of the second stage intervention (performed usually a few weeks or months later), during which another graft will be attached to this elephant trunk. Anastomosing the descending aortic graft to the preplaced elephant trunk is often preferable to anastomosing to a dilated distal aortic arch under deep hypothermic arrest. Identifying and retrieving the elephant trunk graft safely during the second stage intervention is key to making this operation successful, perhaps its most critical step. Retrieval of the elephant trunk for

performance of a Stage II procedure is not trivial, especially because the elephant trunk is often left short, in order to discourage paraplegia due to coverage of many pairs of intercostal arteries. Often the elephant trunk terminates just beyond the aortic arch.

There are several technical options for elephant trunk retrieval:

1. The aorta and the contained elephant trunk can be surrounded above the terminus of the elephant trunk as described previously [3]. However, this is not entirely benign, as the aorta may be very large at that level and there will be local inflammation from the Stage I procedure. Aortic, esophageal, or recurrent laryngeal injury may be incurred.
2. A second alternative is that the entire procedure may be done under deep hypothermic circulatory arrest (DHCA), but that defeats the rationale of the elephant trunk procedure, which is meant to facilitate conduct of Stage II. Once the elephant trunk is safely controlled, there is no need for any DHCA.
3. A third alternative is to use high-dose adenosine [4,5] (or rapid ventricular pacing) to produce transient cardiac standstill, during which the aorta may be opened without exsanguination.
4. The Finger-Thumb technique.

In this report we present the fourth alternative, illustrated in this brief video (<http://dx.doi.org/10.12945/j.aorta.2013.13.064.vid.01>). We call this technique the “Finger-Thumb” technique. As the name implies, the index finger and the thumb enter the



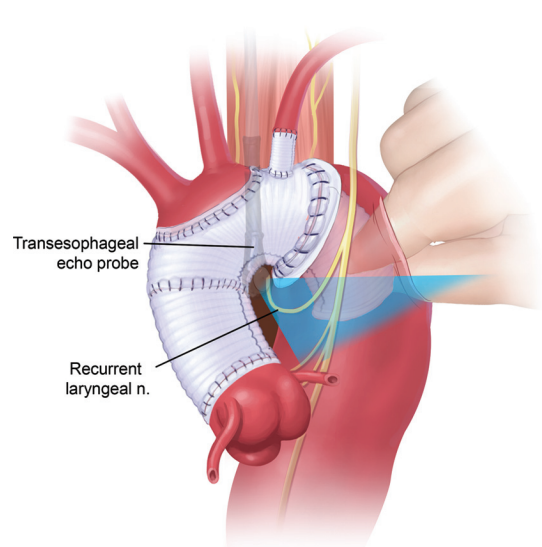


Figure 1. Illustrated is the transesophageal echocardiography-guided approach to the elephant trunk graft. Please note the location of the recurrent laryngeal nerve, which can be injured while encircling the proximal descending aorta.

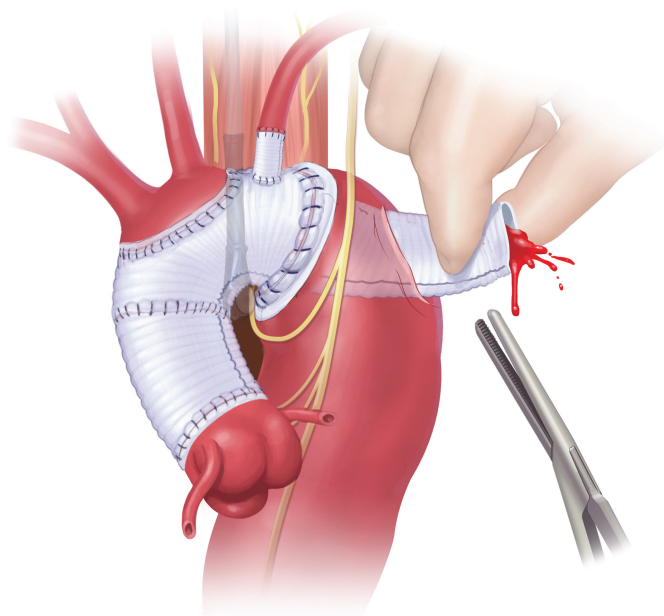


Figure 2. Schematic illustration of elephant trunk graft retrieval in preparation for clamping.

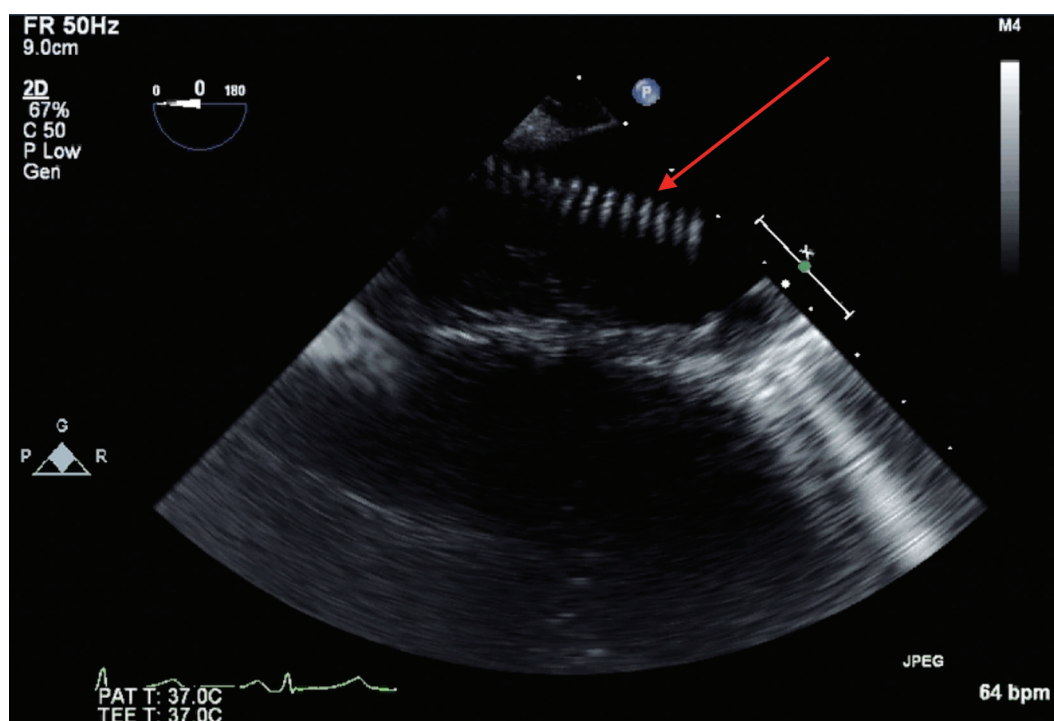


Figure 3. Intraoperative transesophageal echocardiography image showing the elephant trunk graft (indicated by red arrow) in the lumen of the descending aorta. Transesophageal and direct epi-aortic echocardiography confirm appropriate location of the incision for the Finger-Thumb technique.

descending aorta via a small vertical incision on the aorta and locate and retrieve the elephant trunk graft by direct palpation (Fig. 1 and Fig. 2). We always identify the end of the elephant trunk by intraoperative transesophageal and epi-aortic echocardiography (Fig. 1 and Fig. 3), so that an incision in the aorta can be made at the ideal level.

Here are a few practical tips that we would like to share:

- There is no margin for error, as the patient can exsanguinate in seconds if this procedure goes awry.
- The graft may adhere to the wall of the aorta, making identification and retrieval more difficult. It can be teased away during Finger-Thumb retrieval process.
- In dissection cases, one must be certain to

explore for the graft in the true lumen (the aorta will have been fenestrated as far as possible during Stage I).

- When the aorta is ultimately opened after control of the elephant trunk, high intercostal arteries may be hard to identify if they originate at the top of the elephant trunk.

In conclusion, we believe that the “Finger-Thumb” is an extremely useful technique for elephant trunk retrieval during a second stage procedure. Although only safe in experienced hands, this technique is a viable option in the arsenal of a cardiothoracic surgeon, especially in cases when proximally surrounding a massively enlarged aorta is unappealing.

Comment on this Article or Ask a Question

References

1. Borst HG, Walterbusch G, Schaps D. Extensive aortic replacement using “elephant trunk” prosthesis. *Thorac Cardiovasc Surg.* 1983;31: 37–40. [10.1055/s-2007-1020290](https://doi.org/10.1055/s-2007-1020290)
2. Crawford ES, Coselli JS, Svensson LG, Safi HJ, Hess KR. Diffuse aneurysmal disease (chronic aortic dissection, Marfan, and mega aorta syndromes) and multiple aneurysm. Treatment by subtotal and total aortic replacement emphasizing the elephant trunk operation. *Ann Surg.* 1990;211:521–537. [10.1097/00000658-199005000-00002](https://doi.org/10.1097/00000658-199005000-00002)
3. Svensson LG. Rationale and technique for replacement of the ascending aorta, arch, and distal aorta using a modified elephant trunk procedure. *J Cardiac Surg.* 1992;7:301–312. [10.1111/j.1540-8191.1992.tb01020.x](https://doi.org/10.1111/j.1540-8191.1992.tb01020.x)
4. Plaschke K, Bockler D, Schumacher H, Martin E, Bardenheuer HJ. Adenosine-induced cardiac arrest and EEG changes in patients with thoracic aorta endovascular repair. *Br J Anaesth.* 2006;96:310–316. [10.1093/bja/ael002](https://doi.org/10.1093/bja/ael002)
5. El-Menyar A, Gehani A. Adenosine-induced tachyarrhythmia and cardiac arrest. *Future Cardiol.* 2010;6:433–436. [10.2217/fca.10.66](https://doi.org/10.2217/fca.10.66)

Cite this article as: Ziganshin BA, Elefteriades JA. Finger-Thumb Technique for Elephant Trunk Retrieval. *Aorta* 2013;1(6):286–288. DOI: <http://dx.doi.org/10.12945/j.aorta.2013.13-064>