

# Establishment of Extracorporeal Circulation under Local Anesthesia in a Patient with an Acute Type A Aortic Dissection Complicated by Cardiac Tamponade

Roman Gottardi, MD<sup>1\*</sup>, Michaela Resetar, MD<sup>1</sup>, Otto Strassl, MD<sup>2</sup>, Bernhard Bacher, MD<sup>2</sup>, Niuscha Taheri, MD<sup>1</sup>, Catharina Schreiber, MD<sup>1</sup>, Johannes Steindl, MD<sup>1</sup>, Rainald Seitelberger, MD<sup>1</sup>

<sup>1</sup>University Clinic for Cardiac Surgery, Paracelsus Medical University Salzburg, Salzburg, Austria; and <sup>2</sup>University Clinic for Anesthesia and Intensive Care, Paracelsus Medical University Salzburg, Salzburg, Austria

## Abstract

**We report the case of an 82-year-old female who presented in a hemodynamically unstable condition to the emergency department of our institution. Transthoracic echo showed a hemodynamically relevant pericardial effusion and the suspicion of an intimal flap in the ascending aorta. The subsequent computed tomography scan revealed a Type A dissection that was limited to the ascending aorta. To prevent hemodynamic deterioration the patient was prepped and draped awake and underwent femoral cannulation for extracorporeal circulation under local anesthesia. After commencing extracorporeal circulation the patient was anesthetized and intubated. During this whole time period no relevant drop in mean arterial pressure was observed. The patient underwent routine replacement of the ascending aorta and was extubated the day after surgery without any neurologic sequelae. Awake cannulation and inception of extracorporeal circulation can prevent the hemodynamic deterioration and cardiac arrest often seen during induction of anesthesia in patients with cardiac tamponade.**

Copyright © 2014 Science International Corp.

## Key Words

**Type A aortic dissection · Pericardial tamponade · Extracorporeal circulation**

## Introduction

Cardiac tamponade is a life-threatening complication in acute Type A aortic dissection and is an important predictor of death in these patients [1]. Further hemodynamic deterioration and cardiac arrest during induction of anesthesia is a common complication of cardiac tamponade [2].

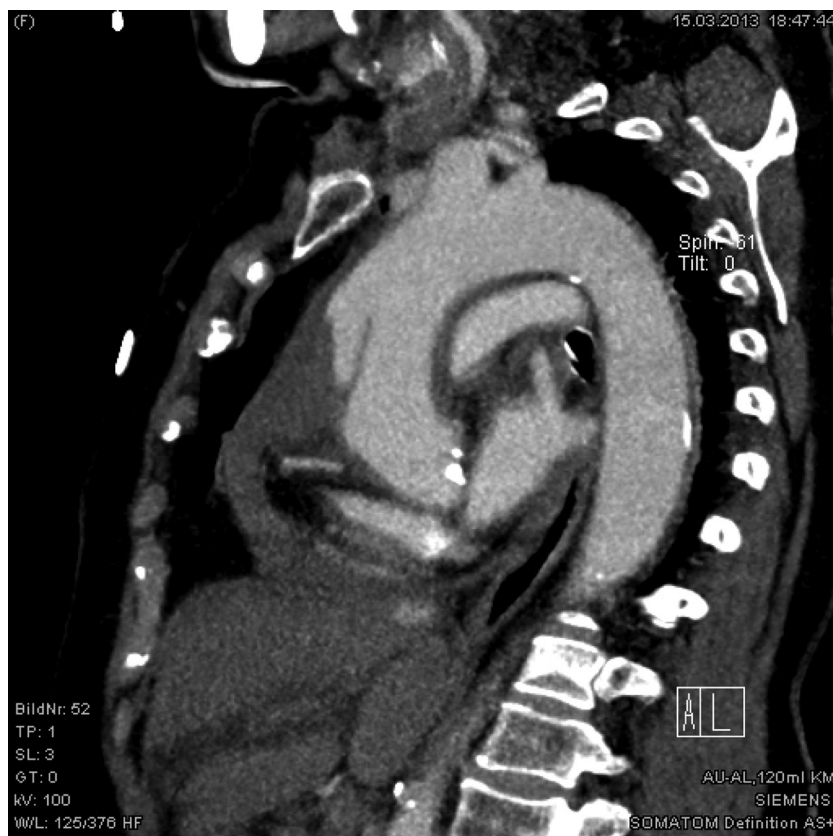
## Case Report

An 82-year-old woman was admitted to the emergency department of our institution in hemodynamic instability. Transthoracic echo revealed a hemodynamically relevant pericardial effusion. Noninvasive blood pressure at this time was between 80 and 90 mm Hg systolic and the patient was conscious. An immediately performed computed tomography (CT) scan showed an acute Type A dissection limited to the ascending aorta, beginning above the sinotubular junction and ending before the brachiocephalic trunk

\*Corresponding author:

Roman Gottardi, MD  
University Clinic for Cardiac Surgery  
Paracelsus Medical University Salzburg  
LKH Salzburg  
5020 Salzburg, Austria  
Tel: +43 662 4482 57512, Fax: +43 662 4482 3374  
E-Mail: [roman.gottardi@gmail.com](mailto:roman.gottardi@gmail.com)





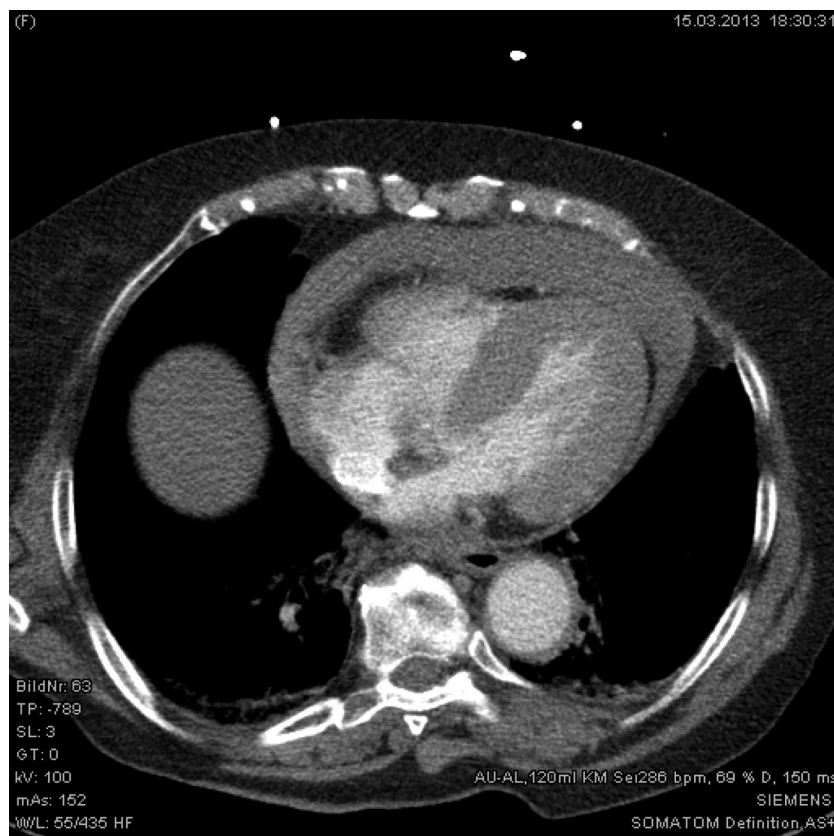
**Figure 1.** CT scan of the dissection membrane limited to the ascending aorta.

(Figs. 1 and 2). During preparation of the operating theater the patient received an arterial line and a central venous catheter in the emergency department. On arrival in the operating theater the patient required increasing vasopressor support with norepinephrine and suprenen to maintain a systolic blood pressure between 60 and 70 mm Hg. The patient was prepped and draped awake and underwent exposure and dissection of the right femoral vessels awake under local anesthesia. A purse string suture was placed on the femoral artery and vein and the patient was heparinized with 300 IU/kg. After measurement of the activated clotting time the venous cannula was placed in the right atrium and the arterial cannula in the iliac artery. Then extracorporeal circulation was established, anesthesia was induced, and the patient was intubated. Retrospective examination of the automatic anesthesia protocol showed no drop in mean arterial pressure below 55 mm Hg between the beginning of the monitoring in the operating room and the beginning of extracorporeal

circulation. Then sternotomy was performed and the patient underwent replacement of the ascending aorta. No cooling and hypothermic arrest was needed as the dissection only involved the ascending aorta and clamping of the aorta was possible proximal to the brachiocephalic trunk in nondissected tissue. This was verified with a brief circulatory arrest, declamping of the aorta, and visual inspection. The aorta was replaced with a supra-coronary 28 mm Dacron® graft. The rest of the procedure was uneventful. The patient was extubated the following day and did not show any neurologic complications. A postoperative CT scan showed a good surgical result and the patient was discharged on postoperative day 10.

### Discussion

Several prior reports describe emergency establishment of cardiopulmonary bypass before induction of general anesthesia in a variety of threatening



**Figure 2.** CT scan of the pericardial effusion (PE) and the compression of the heart.

circumstances [3–5]. Acute Type A dissection with cardiac tamponade is associated with an increased risk of mortality [1]. Surgical or interventional sub-xiphoidal drainage is risky in an acute Type A dissection, as this may lead to exsanguination of the patient due to free rupture of the aorta. Also, due to clot formation, sufficient decompression of the heart may not be achieved. An interesting technique to deal with this situation was described by Hayashi et al. [6]. They percutaneously inserted a pigtail catheter in the pericardium and controlled the drainage volume by intermittent withdrawal to keep the systolic blood pressure around 90 mm Hg [6]. The risk of hemodynamic deterioration during induction of anesthesia was very high in this patient as she already required vasopressor support and, under this support, had a systolic blood pressure between 60 and 70 mm Hg. Emergency sternotomy in the case of acute hemodynamic deterioration during induction of anesthesia and cannulation of the aorta would have been extremely risky due to the aortic dissection. In a case report published in

1989, Norman et al. [7] described two patients with aortic dissection and cardiac tamponade. In one patient they induced anesthesia and performed sternotomy as usual. This patient died due to aortic rupture and exsanguination after opening of the pericardium. In the other patient the first surgical procedure performed after induction of anesthesia was femoral cannulation and establishing of extracorporeal circulation to prevent a sudden increase of cardiac output and blood pressure during opening of the pericardium [7]. This patient survived surgery and was discharged from the hospital.

We chose to cannulate the femoral vessels under local anesthesia and initiate extracorporeal circulation while the patient was awake to minimize the risk of complications associated with induction of anesthesia. Additionally, as the dissection was limited to the ascending aorta, we did not have to fear the potential risks of femoral cannulation in patients with an acute Type A dissection [8].

In summary, our approach avoids the risk of hemodynamic deterioration during induction of anesthesia.

Also, our approach avoids the sudden increase of cardiac output and blood pressure after opening of the pericardium, which can produce free rupture and exsanguination. Finally, our approach preserves circulation in patients presenting with cardiac tamponade resulting from an acute Type A aortic dissection.

### Conflict of Interest

The authors have no conflict of interest relevant to this publication.

[Comment on this Article or Ask a Question](#)

### References

1. Gilon D, Mehta RH, Oh JK, Januzzi JL, Bossone E, Cooper JV, et al. Characteristics and in-hospital outcomes of patients with cardiac tamponade complicating type A acute aortic dissection. *Am J Cardiol.* 2009; 103:1029–1031. [10.1016/j.amjcard.2008.12.013](#)
2. Grocott HP, Gulati H, Srinathan S, Mackensen GB. Anesthesia and the patient with pericardial disease. *Can J Anaesth.* 2011;58:952–966. [10.1007/s12630-011-9557-8](#)
3. von Segesser LK. Peripheral cannulation for cardiopulmonary bypass. *Multimed Man Cardiothorac Surg.* 2006;Jan 1. [10.1510/mmcts.2005.001610](#)
4. Erdil N, Cetin L, Nisanoglu V, Sener E, Demirkiliç U. Cardiopulmonary bypass before general anesthesia in prosthetic valve thrombosis. *Asian Cardiovasc Thorac Ann.* 2002;10: 83–84. [10.1177/021849230201000125](#)
5. Jensen V, Milne B, Salerno T. Femoral-femoral cardiopulmonary bypass prior to induction of anaesthesia in the management of upper airway obstruction. *Can Anaesth Soc J.* 1983;30: 270–272. [10.1007/BF03013806](#)
6. Hayashi T, Tsukube T, Yamashita T, Haraguchi T, Matsukawa R, Kozawa S, et al. Impact of controlled pericardial drainage on critical cardiac tamponade with acute type A aortic dissection. *Circulation.* 2012;126(11 Suppl 1): S97–S101. [10.1161/CIRCULATIONAHA.111.082685](#)
7. Norman PH, Mycyk T. Dissection of ascending thoracic aorta complicated by cardiac tamponade. *Can J Anaesth.* 1989;36:470–472. [10.1007/BF03005351](#)
8. Tiwari KK, Murzi M, Bevilacqua S, Glauber M. Which cannulation (ascending aortic cannulation or peripheral arterial cannulation) is better for acute type A aortic dissection surgery? *Interact Cardiovasc Thorac Surg.* 2010;10:797–802. [10.1510/icvts.2009.230409](#)

**Cite this article as:** Gottardi R, Resetar M, Strassl O, Bacher B, Taheri N, Schreiber C, Steindl J, Seitelberger R. Establishment of Extracorporeal Circulation under Local Anesthesia in a Patient with an Acute Type A Aortic Dissection Complicated by Cardiac Tamponade. *Aorta* 2014;2(4): 152–155. DOI: <http://dx.doi.org/10.12945/jaorta.2014.14-009>

### EDITOR'S COMMENT

This is a valuable technique to have in the armamentarium. Another tool we use in such circumstances is to anesthetize the patient, perform sternotomy, and make a small pericardial opening—letting fluid out slowly, to avoid rebound hyperten-

sion and free rupture. The anesthesiologist controls the blood pressure with medications as hemodynamics improves during gradual relief of tamponade.

Concurrently, we have exposed the femoral artery for cannulation, which we use routinely in Type A dissection [1].

### REFERENCES

1. Fusco DS, Shaw RK, Tranquilli M, Kopf GS, Eleftheriades JA. Femoral cannulation is safe for type A dissection repair. *Ann Thorac Surg.* 2004;78:1285–1289. [10.1016/j.athoracsur.2004.04.072](#)

### EDITOR'S COMMENT

*Dr. Scott A. LeMaire, Professor, Baylor College of Medicine, Houston, Texas, USA.*

The authors are to be congratulated for successfully managing a challenging emergency situation involving

an elderly patient with acute dissection. Although the concept of establishing cardiopulmonary bypass via the peripheral vessels during local anesthesia in patients with severe cardiopulmonary instability is not new, the current report serves to remind readers that this can be a very useful approach in patients with acute dissection (particularly DeBakey type II dissection) and severe tamponade.