

Iatrogenic Aortic Transection in a Child

Ram Chandra Sherawat, MS*, Anil Sharma, Mch, Sunil Dixit, Mch, Mohit Sharma, MS, Sidarth Lukaram, MS

Department of Cardio-Thoracic and Vascular Surgery, Sawai Man Singh Medical College, Jaipur, Rajasthan, India

Abstract

The accepted treatment for aortic injury has been repair of the injury as soon as possible. Delayed repair is not generally fruitful, but in our case report, delay in the repair of a ligated and transected abdominal aorta is safe and has a potential positive impact on survival and vascular stability/integrity. This case seems worth reporting.

Copyright © 2015 Science International Corp.

Key Words

Transected • Abdominal aorta • Superior mesenteric artery • Inferior mesenteric artery

Introduction

No documentation of a case of ligation and transection of the abdominal aorta with delayed repair is available. Sir Astley Cooper in 1817 originally reported ligation of the abdominal aorta if an aneurysm was present. In this case report, the patient was referred to our center because of intensive pain in the legs with numbness following radical nephrectomy. Color Doppler showed minimal flow in both common femoral arteries. No flow was seen in either superficial femoral artery. We found a ligated and totally transected aorta from the level below the origin of the right renal artery to the level just proximal to the bifurcation of aorta. We performed an interposition replacement of the aorta using a 10mm GoreTex graft (Gore Medical, Flagstaff, Arizona, USA) and re-implanted the inferior mesenteric artery (IMA) into the new graft.

Case Report

The patient was a 7-year-old girl. She presented with a history of left radical nephrectomy 3 days earlier for Wilm's tumor. The patient was referred to our center because of intensive pain in the legs with numbness.

On physical examination, the pulse was 86 bpm, and the blood pressure was 100/60 mm Hg. The legs were cool and mottled, but not cold (Figure 1). The patient was unable to move her legs. There was no sensation. No pulses were palpable in any lower limb arteries. There was no motor power (0/5) in the lower limbs (paraplegia). Color Doppler showed minimal flow in both common femoral arteries. A completely occluding thrombus was visualized by Doppler in both femoral arteries. Computed tomography showed an abrupt termination of the aorta below the right renal artery. The superior mesenteric artery (SMA) was seen intact. The IMA was not seen (Figure 2).

Under general anesthesia and via a previous incision (Chevron), the abdomen was explored and the aorta was exposed. We found a ligated and totally transected aorta from below the origin of the right renal artery to just proximal to the bifurcation of the aorta. The IMA was found ligated. The transected segment gap was approximately 10 cm. The gut was normal with no signs of ischemia. We performed the interposition aortic replacement and re-implanted the IMA into the new graft.

Postoperatively, the patient was maintained on thromboprophylaxis with low-molecular weight heparin. Bilateral femoral pulses were present immediately.



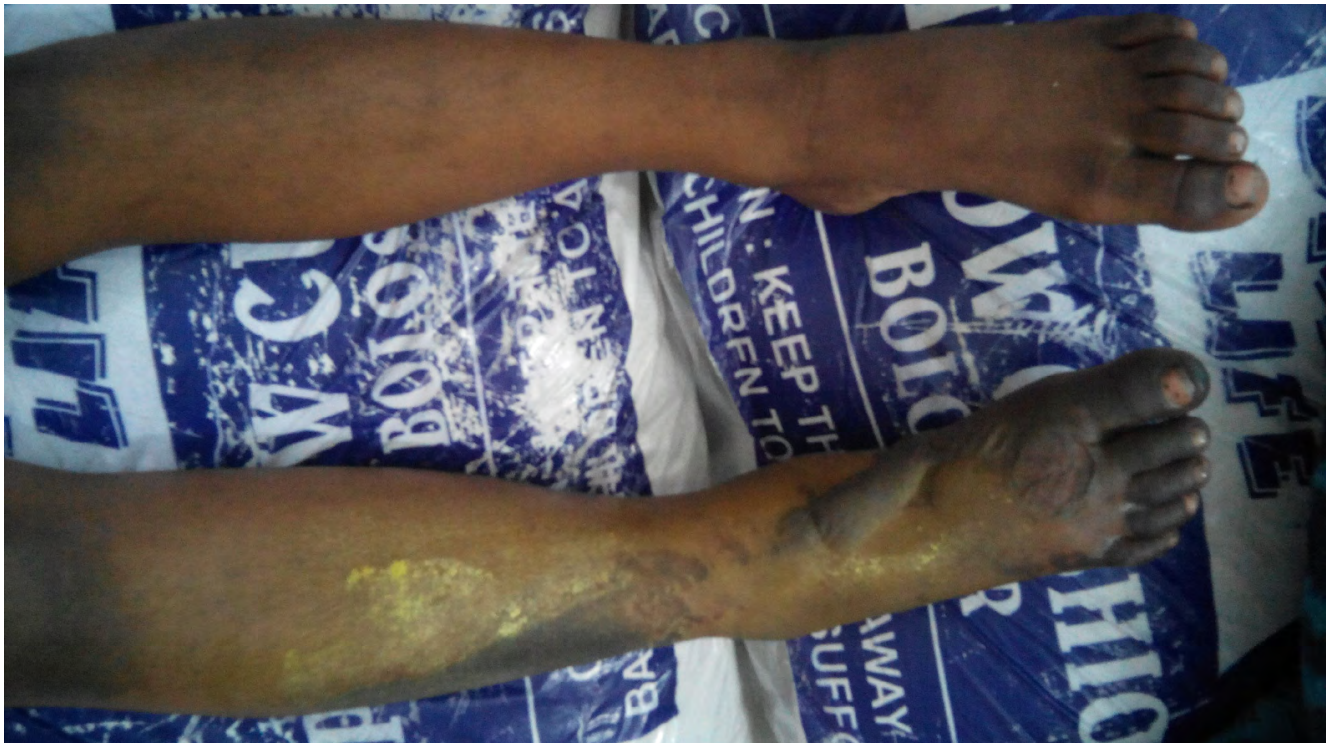

Figure 1. Preoperative findings show cool and mottled legs.

The lower limbs were warm by postoperative day (POD) 1. Sensation returned to both lower limbs on POD 2. Motor power (2/5) returned to both lower limbs on POD 3. Bowel and bladder functions were intact.

The patient was discharged before ambulating to rehabilitation. As of the most recent follow up, the patient has regained motor strength (4/5) bilaterally.

Discussion

Because the patient was very young, we decided to operate to perform an aortic repair even with a late presentation (> 72 hours). We were concerned about operating on a patient with a single kidney. We expected enhanced resistance due to her young age. No post-operative complications occurred.

The severity of tissue ischemia depends not only on its duration but on both the level of arterial injury and the efficiency of collateral circulation [1-3]. Additionally, the amount of time since the injury may not necessarily reflect the actual period of ischemia, especially in a closed vessel injury [4,5].

This is not to suggest that delays in revascularization should not be minimized. Conventional logic dictates that the longer the period of ischemia, the higher the chance of limb loss. However, this case illustrates that to condemn limbs as unsalvageable purely on the basis of ischemia time alone is not prudent.

Finally, it must be stressed that both limb salvage and long-term functionality must be considered. Nevertheless, in Asian societies like ours where the physical integrity of limbs often takes precedence over functionality, maintaining even a nonfunctional limb may be desired.

This case illustrates the delayed repair of a ligated and transected abdominal aorta with good outcome.

Conflict of Interest

The authors have no conflict of interest relevant to this publication.

[Comment on this Article or Ask a Question](#)

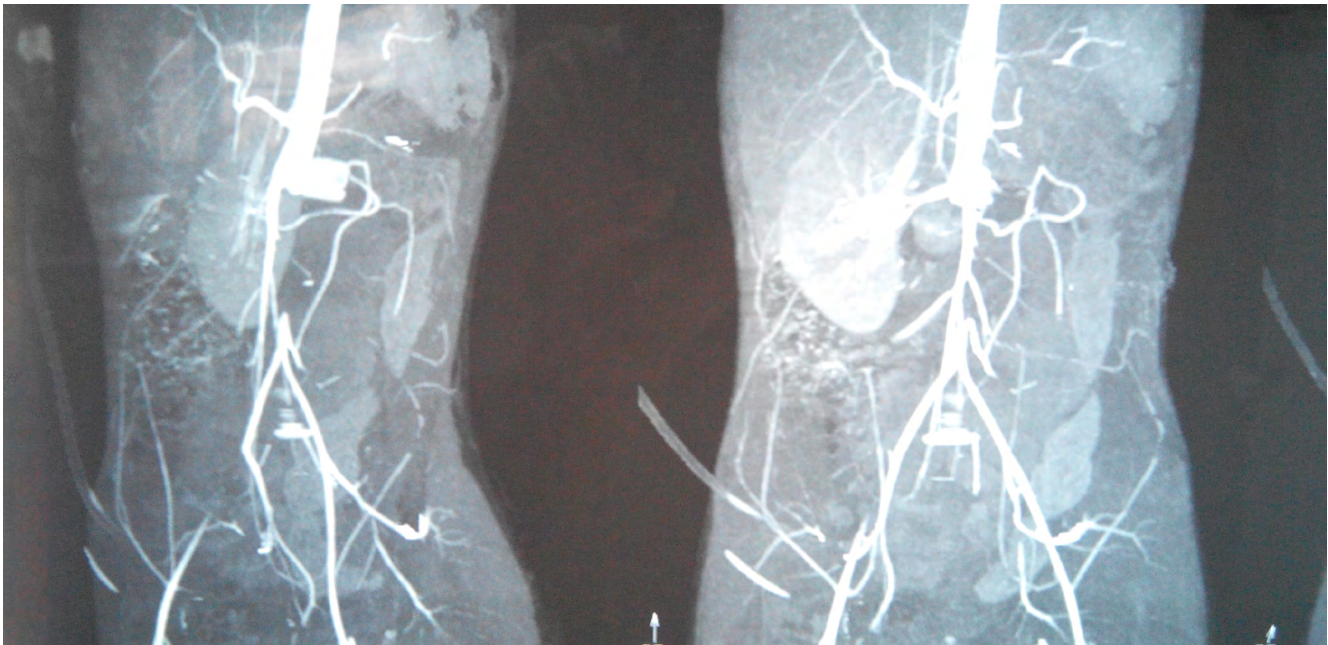


Figure 2. Pre and post operative computed tomography (2a) preoperative CT Shows an abrupt termination of the aorta below the right renal artery (2b) post operative CT shows normal blood flow.

References

1. Hafiz HM, Woolgar J, Robbs JV. Lower extremity arterial injury: Results of 550 cases and review of risk factors associated with limb loss. *J Vasc Surg.* 2001;33:1212-1219. DOI: [10.1046/j.1365-2168.2000.01420-2.x](https://doi.org/10.1046/j.1365-2168.2000.01420-2.x).
2. Wani S , Dev B, Dang H, Singh G. Pattern, management, results and complication of vas injury of the extremities. Report from a hospital in Jammu. *Internet J Orthop Surg.* 2009;17:2339-2341. Retrieved from <https://ispub.com/IJOS/17/2/11929>.
3. Silva De WDD, Ubayasiri RA, Weerasinghe CW, Wijeyaratne SM. Challenges in the m/m of extremities vas injuries. A warfare experience from a tertiary centre in Sri Lanka. *World J Emerg Surg.* 2011;6:24. DOI: [10.1186/1749-7922-6-24](https://doi.org/10.1186/1749-7922-6-24).
4. Mavioglu I, Veli Dogan O, Ozeren M, Dolgun A, Yucel E. Surgical management of chronic total occlusion of abdominal aorta. *J Cardiovasc Surg (Torino).* 2003;44:87-93. PMID: [12627078](https://pubmed.ncbi.nlm.nih.gov/12627078/).
5. Symbas PN, Sherman AJ, Silver JM, Symbas JD, Lackey LJ. Traumatic rupture of the aorta. *Ann Surg.* 2002;235:769-802. PMID: [PMC12035035](https://pubmed.ncbi.nlm.nih.gov/12035035/)
6. Menakuru SR, Behara A, Jindal R, Kaman L, Doley R, Venkatesan R. Extremity vascular trauma in civilian population: A seven-year review from north India. *Injury, Int J Care Injured.* 2005;36:400-406. DOI: [10.1016/j.injury.2004.06.017](https://doi.org/10.1016/j.injury.2004.06.017)
7. Cooper, A. *Principles and Practice of Surgery.* Vol. 2. Wells and Lilly Boston. 1825;56

Cite this article as: Sherawat RC, Sharma A, Dixit S, Sharma M, Lukaram S. Iatrogenic Aortic Transection in a Child. *AORTA* 2015;3(Issue 1): 38-40. DOI: <http://dx.doi.org/10.12945/j.aorta.2015.14-043>