J Am Acad Audiol 28:80–90 (2017)

Case Report

Detailed Audiological Evaluation of a Patient with Xeroderma Pigmentosum with Neural Degeneration

DOI: 10.3766/jaaa.15112

Danielle Mercer*
Annette Hurley†
Fern Tsien*

Abstract

Background: Xeroderma pigmentosum (XP) is a rare autosomal recessive condition characterized by extreme sensitivity to ultraviolet light. Individuals with XP lack the ability to repair DNA (deoxyribonucleic acid) damage caused by ultraviolet radiation, leading to sunburn and increased susceptibility to skin cancers. Approximately 25% of patients also exhibit neural degeneration, which includes progressive mental deterioration, cortical thinning, and sensorineural hearing loss.

Purpose: Herein, we describe the audiological and genetic findings in a patient with XP subtype D with neural degeneration and hearing loss.

Research Design: This is a case report of a patient with XP subtype D, type 1 diabetes, and some clinical features typical of Charcot-Marie-Tooth disease.

Data Collection and Analysis: We obtained audiological evaluations over a course of 11 yr, including serial audiograms, auditory processing disorders evaluations, and electrophysiological testing.

Results: Hearing sensitivity has progressed from a unilateral mild high-frequency sensorineural hearing loss to a bilateral sloping moderate to severe/profound sensorineural hearing loss. In addition to the dramatic decline in hearing sensitivity, the patient demonstrates global auditory processing deficits, indicating a central component to his hearing loss.

Conclusion: These findings emphasize the importance of the contribution of audiological evaluations to the diagnosis of a genetic disorder. Periodic evaluations of hearing sensitivity and auditory processing can provide information on disease progression in patients with XP with neural degeneration.

Key Words: auditory brainstem response, central auditory processing disorder, Charcot-Marie-Tooth disease, genetic hearing loss, type 1 diabetes, xeroderma pigmentosum

Abbreviations: ABR = auditory brainstem response; CMT = Charcot-Marie-Tooth disease; DNA = deoxyribonucleic acid; FM = frequency modulation; LEP = late event potentials; MLD = masking-level difference; MLR = middle-latency response; SD = standard deviation; XP = xeroderma pigmentosum

*Department of Genetics, Louisiana State University Health Sciences Center, New Orleans, LA; †Department of Communication Disorders, Louisiana State University Health Sciences Center, New Orleans, LA

Corresponding author: Danielle Mercer, Department of Genetics, Louisiana State University Health Sciences Center, New Orleans, LA 70112; E-mail: dmerc2@lsuhsc.edu

This study was presented as a poster at the American Society of Human Genetics conference in Boston, MA, October 24, 2013; and the American Academy of Audiology conference in Orlando, FL, March 28, 2014.

This document was downloaded for personal use only. Unauthorized distribution is strictly prohibited.

INTRODUCTION

Xeroderma Pigmentosum

Xeroderma pigmentosum (XP) is a rare autosomal recessive condition characterized by defects in DNA (deoxyribonucleic acid) nucleotide excision repair (Lehmann et al, 2011). Nucleotide excision repair is a mechanism necessary to correct damage incurred to DNA, most notably due to photoproducts produced via exposure to ultraviolet radiation (Mareddy et al, 2013). Common clinical features of XP include extreme sensitivity to sunlight, substantially increased susceptibility to skin cancers, and ocular anomalies, such as photophobia and corneal changes (Halkud et al, 2014; Bowden et al, 2015). In 60% of cases, the disease first presents as extreme sunburn upon minimal sun exposure (Bradford et al, 2011). The remaining 40% of cases do not show this extreme sunlight sensitivity, though multiple lentigines (freckle-like pigmentation) appear on sun-exposed areas (Lehmann et al, 2011). Reported incidence ranges as high as 1 in 20,000 in Japan (Hirai et al, 2006) and as low as 2.3 per million in Western Europe (Kleijer et al, 2008). Incidence in the United States has been estimated at 1 in 250,000 to 1 in 1,000,000 (Robbins et al, 1974; Kraemer and DiGiovanna, 2014). Like other autosomal recessive diseases, incidence increases in areas of high consanguinity (Lehmann et al, 2011). There are eight subtypes of XP (A through G and V/variant), which are caused by mutations in various genes involved in DNA repair (Lehmann et al, 2011).

Approximately 25% of patients with XP also exhibit progressive neural degeneration, which includes intellectual deterioration, cortical thinning, and progressive sensorineural hearing loss (Bradford et al, 2011). Patients with XP with neural degeneration have reduced lifespans, with life expectancy typically in the third or fourth decade of life (Bradford et al, 2011). Cases of neural degeneration are associated with subtypes A, B, D, F, and G, though not every patient with one of these subtypes will be afflicted with neural degeneration (Totonchy et al, 2013). Aside from proper diagnosis of subtype, the appearance of neural degeneration in any given patient is difficult to predict (Totonchy et al, 2013). An early sign that may be an indicator of the development of neural degeneration in a patient with XP is the absence or reduction of deep tendon reflexes (Mareddy et al, 2013). Once neural degeneration develops, progression of sensorineural hearing loss parallels neural decline (Totonchy et al, 2013).

Charcot-Marie-Tooth Disease

Charcot-Marie-Tooth disease (CMT) consists of a group of heritable neurological disorders characterized by motor and sensory neuropathies, distal muscle weakness and atrophy, and orthopedic abnormalities (Rance et al, 2012; Jani-Acsadi et al, 2015). Its prevalence in the United States is estimated at 1 in 2,500 (NINDS, 2015). More than 50 genes have been implicated in the etiology of CMT (Siskind et al, 2013), making genetic diagnosis complicated. Depending on the gene involved, autosomal dominant, autosomal recessive, and X-linked patterns of inheritance are all possible (Patzkó and Shy, 2011). Because of this heterogeneity, genetic confirmation is impossible in many patients, and diagnosis may be based on clinical presentation alone (Saporta et al, 2011).

CMT is grouped based on inheritance pattern and type of neuropathy (demyelinating or axonal), with each category containing several subtypes (Patzkó and Shy, 2011). CMT1A, an autosomal dominant demyelinating neuropathy, is the most common form of CMT (Patzkó and Shy, 2011). Life expectancy is usually not affected (NINDS, 2015). Hearing loss is not uncommon in patients with CMT (Rance et al, 2012), though exact estimates of hearing loss in this population are unavailable. In the literature, many cases of CMT with hearing loss are reported as an auditory neuropathy or deficits of the auditory nerve (Satya-Murti et al, 1979; Starr et al, 1996; Butinar et al, 1999; Kovach et al, 2002; Starr et al, 2003; Butinar et al, 2008), and have been observed in both demyelinating and axonal types (Rance et al, 2012). Temporal processing deficits have been described in patients with CMT, including deficits in gap detection (Starr et al, 2003; Butinar et al, 2008) and amplitude modulation detection (Starr et al, 2003; Rance et al, 2012).

Herein, we describe a patient with three disparate clinical diagnoses: XP with neural degeneration, CMT, and type 1 diabetes. We provide retrospective audiometric data spanning several years, which demonstrate the dramatic progression of hearing loss in this patient. Chromosome analysis was performed to rule out a chromosomal rearrangement as the underlying etiology in one or more of these diagnoses.

CASE STUDY

Audiological History

The patient is an 18½-yr-old male who initially presented to an audiology clinic at 7 yr of age after a failed hearing screening. At that time, the patient was receiving speech–language therapy and was using a frequency modulation (FM) system in the classroom. He had a reported history of academic difficulty. He had tried Earobics auditory training with no subjective benefit. Initial audiological evaluation performed by another audiology clinic when the patient was 7 yr old indicated a unilateral mild high-frequency sensorineural hearing loss in the left ear with a configuration

This document was downloaded for personal use only. Unauthorized distribution is strictly prohibited.

suggestive of noise exposure. The patient lived in a rural area, reporting a history of noise exposure that included hunting, fireworks, and use of all-terrain vehicles. He was counseled on hearing conservation practices. He was subsequently referred to our clinic for an auditory processing evaluation at 8 yr of age.

We continued to follow this patient for audiological evaluations up to 18½ yr of age. Hearing loss progressed to a bilateral sloping moderate to severe/profound sensorineural hearing loss. He began wearing binaural behind-the-ear hearing aids at 11 yr of age. The patient noted improvements in sound quality in the classroom with the use of hearing aids and an FM system, though he continued to struggle academically. Intelligence testing at an age of 8 yr using the Wechsler Intelligence Scale for Children-III indicated borderline mild mental handicap. Repeat testing at 11 yr of age demonstrated no significant decline in intellectual functioning. An Individualized Education Program was in place at his school beginning at 7 yr of age, which allowed him to receive classroom accommodations, special instruction, and speech–language therapy. A summary of all audiological evaluations, genetic testing, and clinical data relevant to this case is presented in Table 1.

Medical History

In addition to progressive sensorineural hearing loss, this patient had a complex medical history. He was diagnosed clinically by the neurologist with CMT at 9 yr of age. Clinical features seen in this patient that are consistent with CMT include hearing loss, reduced deep tendon reflexes, peripheral neuropathy, impairment in temporal processing deficits, and a "claw-toe" deformity. For several years the progressive hearing loss was thought to be attributable to CMT, although the typical CMT presentation of auditory neuropathy was not present. At 13 yr of age, he was diagnosed with type 1 diabetes.

A clinical diagnosis of XP was made at 16 yr of age. Patient history supported this diagnosis, as the patient's mother reported he experienced severe sunburn with minimal sun exposure as an infant. After this incident, the family became vigilant regarding sun protection/avoidance. He also had multiple lentigines. At 14 yr of age, he had two melanomas removed and began the first of several surgeries on his feet, including bilateral tendon releases and revisions to address the foot deformity.

The patient underwent several molecular tests for genetic diagnosis of XP and CMT. XP complementation testing performed using sequence analysis revealed compound heterozygous missense mutations (G1847C and C2047T) in the *ERCC2* gene. This corresponds to XP complementation group D (XP-D), one of the XP subtypes associated with neural degeneration and sensorineural hearing loss. Mutation analysis was performed on several different CMT-causing genes, including *PMP22*, *CX32*, *MPZ*, *EGR2*, *NEFL*, *PRX*, *GDAP1*, *LITAF*, and *MFN2*. CMT mutation analysis was negative for the genes tested.

There was some overlap between the clinical features of XP and CMT, including reduced deep tendon reflexes, peripheral neuropathy, and hearing loss. There were no other family members with XP, CMT, or type 1 diabetes, although a first cousin was reported to have had a melanoma. The patient struggled with learning disabilities throughout his educational history. Speech–language evaluation at 18 yr of age showed mild-to-moderate cognitive-linguistic disorder. He had complained of progressively worsening fatigue and difficulty with cognitive tasks. He continues to be followed up for CMT-related issues, including pain management, physical therapy, occupational therapy, and surgical intervention.

METHODS

Audiological Evaluations

Audiometry

Audiological evaluations were performed using standard testing protocols. Testing consisted of pure-tone presentation via air and bone conductions, 226-Hz tympanometry, speech discrimination using recorded presentation of the Northwestern University Test No. 6 monosyllabic words at 40 dB SL, ipsilateral and contralateral acoustic reflex thresholds, and transient-evoked or distortion product otoacoustic emissions. Audiometry was performed at 11, 11½, 13, 18, and 18½ yr of age.

Auditory Processing Disorder Evaluations

The SCAN-3C Test for Auditory Processing Disorders in Children-Revised was administered at comfortable listening levels of 50 dB HL at 8 yr of age and 75 dB HL at 11 yr of age. The SCAN-3C consists of four subtests: filtered words, auditory figure ground, competing words, and competing sentences. Masking-level difference (MLD) comparing thresholds of binaural signals embedded in background noise was measured at 8 yr of age. MLD was obtained by subtracting signal threshold while signal and noise were out of phase (antiphasic condition) from signal threshold while signal and noise were in phase (homophasic condition).

Electrophysiological Assessments

Electrophysiological assessment was performed with conventional electrode montage using Cz site (vertex) for the noninverting electrode and two-channel recordings.

This document was downloaded for personal use only. Unauthorized distribution is strictly prohibited.

Table 1. Summary of Audiological, Clinical, and Genetic Data Obtained from Patient between 7 and 18½ yr of age

	Audiological Evaluations							Genetic Evaluations	
Age (Year)	Audiometry*	APD	ABR	MLR	LEP	IQ testing	Clinical Diagnoses	Molecular	Cytogenetic
7	R: WNL L: Mild SNHL 3–4 kHz Speech R: 96%; L: 100%	FW: >2 SD AFG: >2 SD CW: >2 SD CS: >2 SD							
8		FW: >1 SD AFG: >2 SD CW: >1 SD CS: >2 SD MLD: WNL	R/L: Wave latencies and amplitudes WNL	R/L: Absence of all waves but Na	R/L: P300 slightly delayed	Borderline mild mental handicap			
9							CMT		
11	R/L: Mild-to-moderate SNHL 1–8 kHz Speech R: 96%; L: 92%	FW: 1 SD AFG: >2 SD CW: >2 SD CS: >2 SD	R/L: Waves I, V, and I–V WNL; poor morphology	R/L: All latencies WNL	R/L: P300 slightly delayed	Borderline mild mental handicap		Negative for mutations in 9 CMT genes	
11½									
13	R: Moderate SNHL 1–8 kHz L: Mild-to-moderate SNHL 1–8 kHz Speech R: 88%; L: 84%		R/L: Waves I, V, and I–V WNL; poor morphology				Type 1 diabetes		
16							XP with neural degeneration		
17								Positive for XP subtype D	
18	R: Mild-to-profound SNHL 0.25–8 kHz L: Mild-to-severe SNHL 0.25–8 kHz Speech R: 76%; L: 84%	RGDT R: 15 msec; L: 20 msec	Could not be obtained	Could not be obtained	R/L: poor morphology				Normal karyotype
18½	R: Moderate-to-profound SNHL 0.25–8 kHz L: Moderate-to-severe SNHL 0.25–8 kHz Speech R: 60%; L: 76%								

Notes: Audiological evaluations from 8 to 18½ yr of age and cytogenetic testing were performed at our facility. APD = auditory processing disorders; AFG = auditory figure ground; CS = competing sentences; CW = competing words; FW = filtered words; IQ = intelligence quotient; L = left ear; R = right ear; RGDT = random gap detection test; SNHL = sensorineural hearing loss; WNL = within normal limits.

*Tympanometry, ipsilateral and contralateral acoustic reflex thresholds, and otoacoustic emissions (OAEs) are not shown. Tympanometry was WNL at every evaluation. Acoustic reflexes and OAEs were consistent with hearing loss. See text for more details.

This document was downloaded for personal use only. Unauthorized distribution is strictly prohibited.

Auditory brainstem responses (ABRs) were obtained at 8, 11, and 13 yr of age using 100-μsec clicks. Clicks were presented at rates of 7.7 clicks/sec and intensities of 80 dB nHL at 8 yr of age and 95 dB nHL at 11 and 13 yr of age. Middle-latency responses (MLRs) were obtained at 8 and 11 yr of age to 75 dB nHL clicks. Late event potentials (LEPs) were obtained to clicks at stimulus intensities of 75–95 dB nHL. P300 responses were recorded at 8 and 11 yr of age using a low-frequency (500 Hz) tone and an "oddball" high-frequency tone (2000 Hz). LEP was repeated at 18 yr of age using 750 Hz as the high-frequency tone due to the severity of the patient's hearing loss. ABR and MLR were attempted at 18 yr of age, but could not be obtained.

Cytogenetic Testing

We performed cytogenetic analysis to rule out any chromosomal abnormality. Chromosome analysis was performed on a peripheral blood sample using standard cytogenetic cell culture, harvest, and slide-dropping techniques (Barch et al, 1997; Howe et al, 2014). Using a light microscope (Olympus BX60; Olympus Optical Co., Tokyo, Japan), 20 cells were analyzed, and metaphase cells were karyotyped using a cytogenetics software platform (CytoVision; Leica Biosystems, Richmond, IL).

RESULTS

Audiological Evaluations

Audiometry

Hearing loss progressively worsened to a moderate-to-profound sensorineural hearing loss in the right ear and a moderate-to-severe sensorineural hearing loss in the left ear (Figure 1). There was an especially significant drop in hearing thresholds and speech discrimination over the 6-mo span between his last two evaluations at 18 and 18½ yr of age. Speech discrimination scores declined, with the most recent scores obtained at 60% in the right ear and 76% in the left ear. Tympanometry was within normal limits at every evaluation. Acoustic reflex thresholds were within normal limits at initial evaluation, but began showing elevation or absence at 11 yr of age. At the final evaluation (18½ yr of age), acoustic reflexes were elevated at 500–1000 Hz and absent at 2000–4000 Hz. Transient-evoked otoacoustic emissions were present bilaterally (1–5 kHz) at 8 yr of age, but absent bilaterally beginning at 11 yr of age. Distortion product otoacoustic emissions tested at 18 yr of age were absent at all frequencies (1–8 kHz) bilaterally, consistent with hearing loss.

Auditory Processing Disorder Evaluations

Auditory processing difficulties were apparent via initial behavioral testing at 8 yr of age, with auditory figure-ground and competing sentences scores falling >2 standard deviations (SD) below the mean. Abnormal results were symmetrical between ears. An MLD of 13 dB was obtained, which was within normal limits. Auditory processing evaluations were repeated at 11 yr of age. Improvement was seen in the filtered words subtest, indicating better auditory closure ability. However, auditory figure ground, competing words, and competing sentences subtest scores were each >2 SD below the mean (Table 2). Three-interval forced-choice random gap detection at 18 yr of age yielded shortest detection at 15 msec in the right ear and at 20 msec in the left ear (normal defined as ≤6 msec), consistent with poor temporal processing.

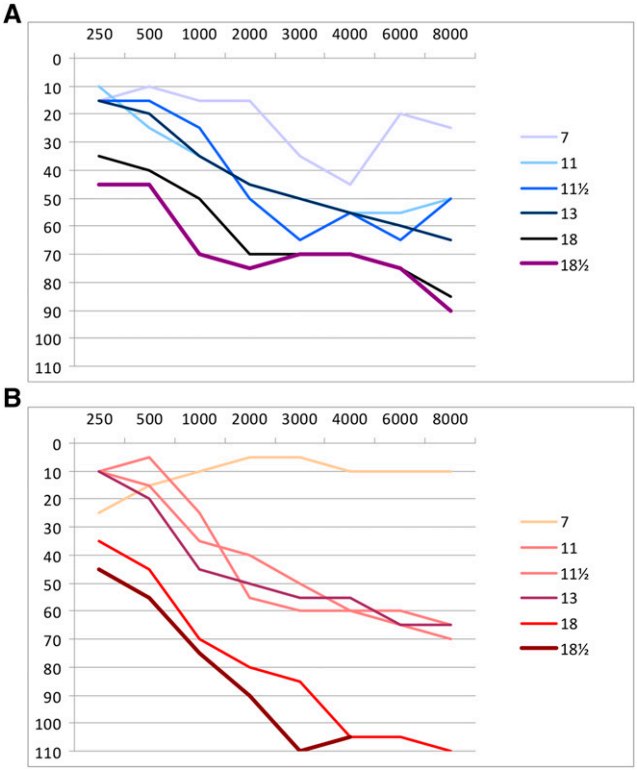

Figure 1. Serial audiograms depicting pure-tone air-conduction thresholds of the (A) left ear and (B) right ear obtained from our patient over the course of 11 yr. Ages are depicted in the legend to the right of each graph. (Frequencies depicted in Hz on *x* axis; intensities depicted in dB HL on *y* axis.)

Electrophysiological Assessments

An ABR collected at 8 yr of age indicated wave latencies and amplitudes within normal limits. Waveform morphology of the ABR deteriorated substantially from 8 to 13 yr of age, though it is unclear whether this deterioration can be attributed solely to the decline in hearing sensitivity (Figure 2). For MLRs obtained at 8 yr of age, wave Na was the only identifiable wave. MLR collected at 11 yr of age was within

This document was downloaded for personal use only. Unauthorized distribution is strictly prohibited.

Table 2. SCAN-3C Subtest and Composite Percentile Scores Obtained from Patient at 7, 8, and 11 yr of Age

Age (Year)	FW	AFG	CW	CS	Composite
7	2	1	2	5	1
8	9	1	16	2	2
11	16	1	5	5	2

Notes: Improvements were observed in performance on the FW subtest, but performance on the other three subtests remained ≥2 SD below the mean. Testing at 7 yr of age was not performed at our facility. AFG = auditory figure ground; CS = competing sentences; CW = competing words; FW = filtered words.

normal limits (not shown). Late event potentials (LEP) recordings were similar at 8 and 11 yr of age: all late potential waves were present, though P300 responses were slightly delayed. At an age of 18 yr, LEP responses were notably poorer in morphology (Figure 3).

Cytogenetics

Cytogenetic analysis revealed a 46,XY karyotype, consistent with a normal male chromosome complement (Figure 4).

DISCUSSION

We describe a patient with genetically confirmed XP subtype D with neural degeneration. Audiological data obtained over many years showed a bilateral progressive sensorineural hearing loss with a configuration consistent with that described in the literature for patients with XP with neural degeneration (Totonchy et al, 2013). Auditory processing testing performed when the patient was a child indicated significant deficits. Auditory-evoked potentials demonstrate worsening waveform morphology in brainstem responses.

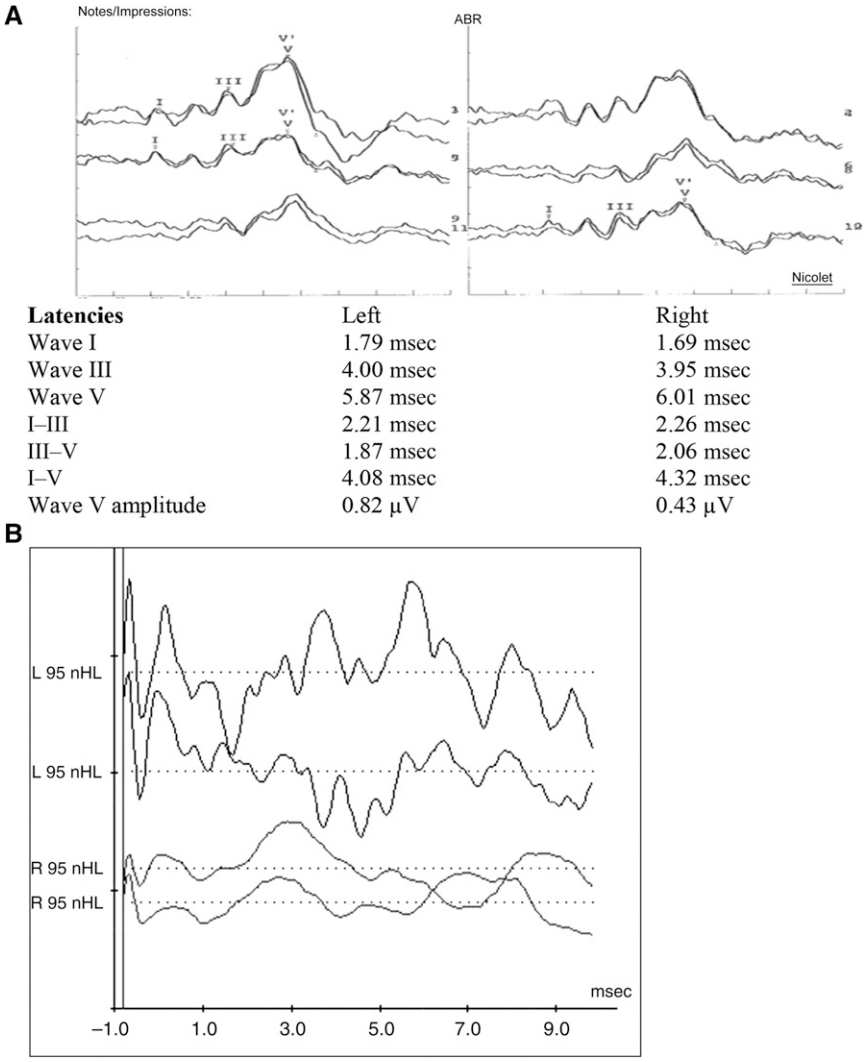

Latencies	Left	Right
Wave I	1.79 msec	1.69 msec
Wave III	4.00 msec	3.95 msec
Wave V	5.87 msec	6.01 msec
I–III	2.21 msec	2.26 msec
III–V	1.87 msec	2.06 msec
I–V	4.08 msec	4.32 msec
Wave V amplitude	0.82 μV	0.43 μV

Figure 2. ABRs obtained at (A) 8 yr of age presented at 80 dB nHL and (B) 11 yr of age (left ear waveforms at top of image and right ear waveforms at bottom of image) presented at 95 dB nHL. Note the decline in waveform morphology.

This document was downloaded for personal use only. Unauthorized distribution is strictly prohibited.

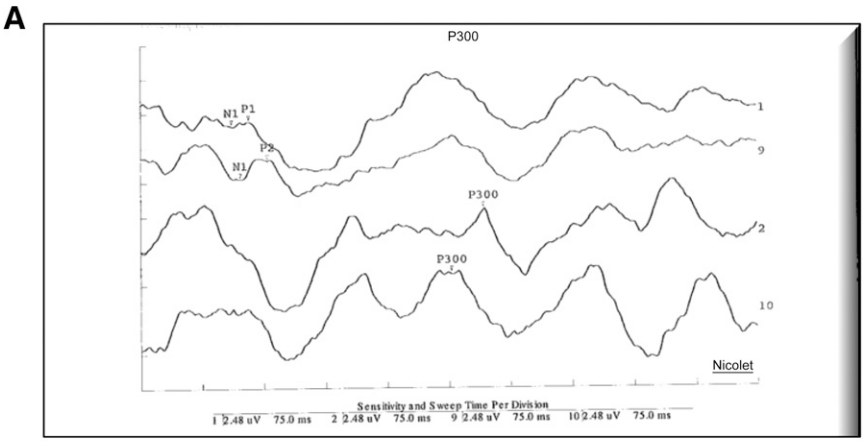

Latencies	Left	Right
N1	111.00 msec	121.50 msec
P2	154.50 msec	132.00 msec
P300	417.00 msec	378.00 msec

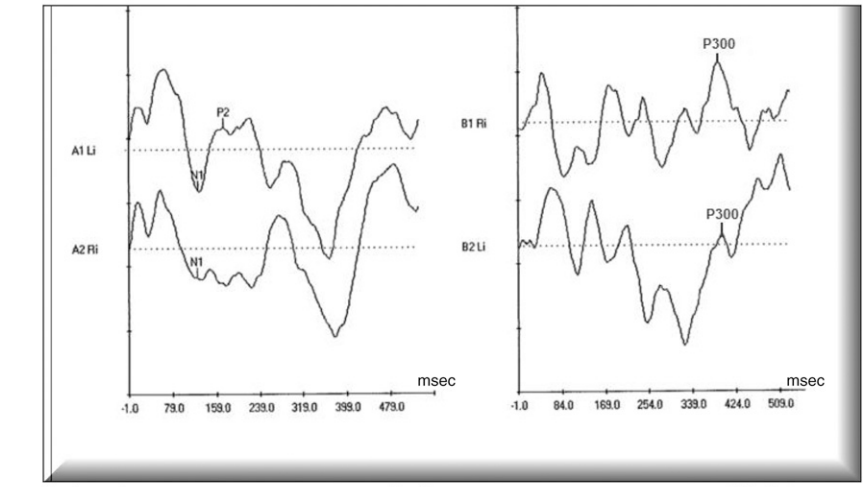

Latencies	Left	Right
N1	130.37 msec	124.12 msec
P2	170.97 msec	148.07 msec
P300	387.49 msec	390.78 msec

Figure 3. LEPs obtained at (A) 8 yr of age presented at 75 dB nHL and (B) 18 yr of age presented at 95 dB nHL. Waveform morphology deteriorated with age, along with peripheral hearing loss.

The significance of these findings is unclear, as some deterioration is to be expected with a decline in hearing loss. We obtained a normal ABR on this patient at 8 yr of age in the presence of a unilateral high-frequency hearing loss. This is not surprising given research reporting acquisition of normal ABRs in adults with 4000 Hz thresholds up to 60 dB HL (Jerger and Johnson, 1988) and in children with significant hearing handicap due to loss at specific frequencies (Balfour et al, 1998). No detailed audiological reports of patients with XP with neural degeneration could be found in the literature, beyond basic audiometric data. A small study evaluated ABR responses of 20 children with XP subtype A (Sugimoto et al, 1999). The authors reported worsening waveform morphology with age, with no identifiable waves in patients >10 yr of age (Sugimoto et al, 1999). However, it is unclear how many participants were affected by neural degeneration or hearing loss.

Information on auditory processing in patients with XP with neural degeneration could not be found in the literature. Our patient exhibited auditory processing deficits in all areas of the SCAN-3C (Keith, 2009), which suggests a global deficit. Although peripheral hearing loss can contribute to poor performance on auditory processing tests, the auditory processing deficits were observed before hearing loss had declined significantly and were symmetrical even in the presence of a unilateral hearing loss. Auditory processing testing was repeated on the patient at 11 yr of age due to his continued difficulties with speech understanding in the classroom, despite consistent use of verified hearing

This document was downloaded for personal use only. Unauthorized distribution is strictly prohibited.

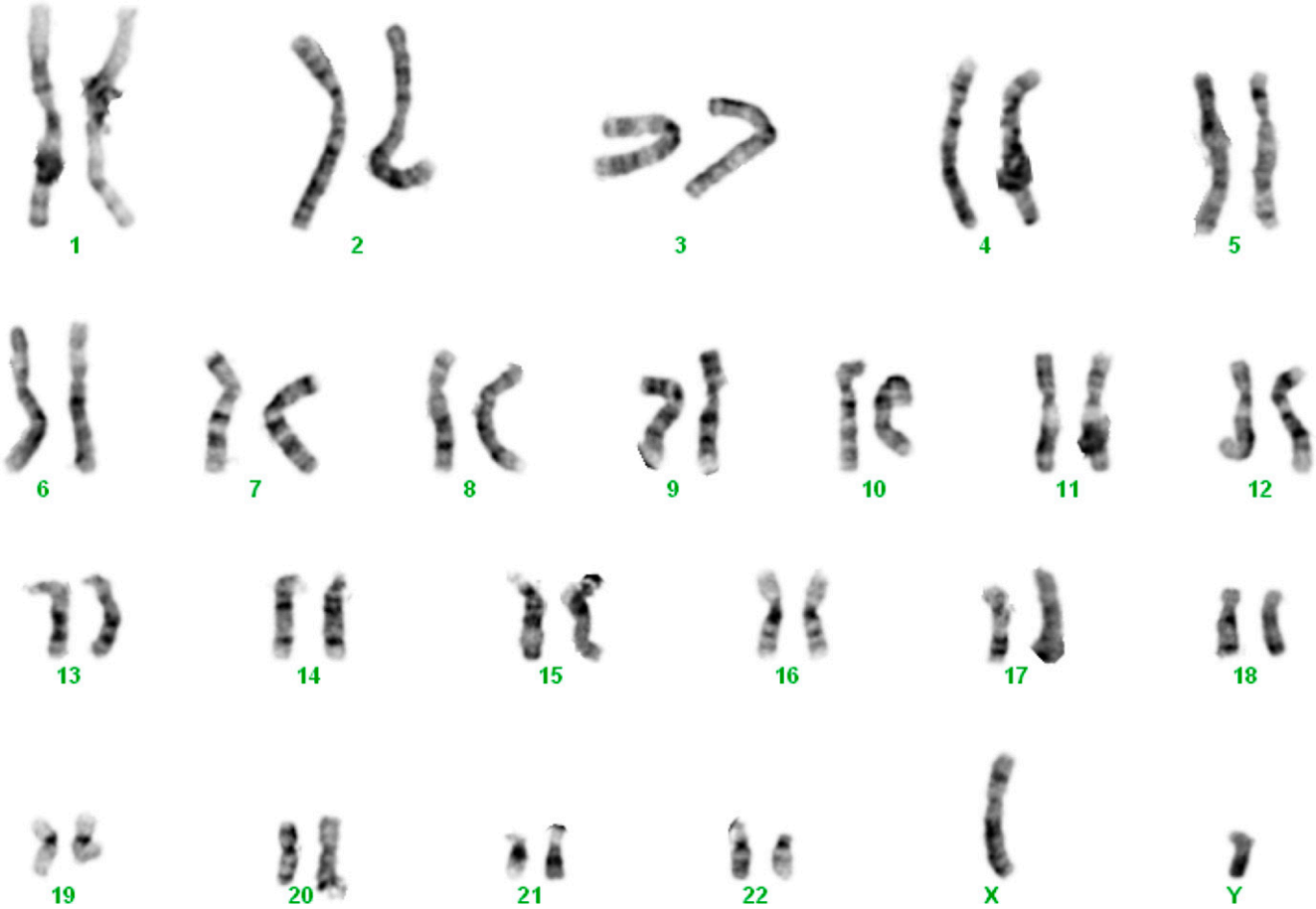

Figure 4. Cytogenetic analysis of patient revealed a normal male karyotype of 46,XY.

aids and FM system. By this time hearing sensitivity had declined, but interaural configuration was symmetrical. Presentation level was increased to patient's most comfortable listening level in an attempt to mitigate effects of peripheral hearing loss on test performance. Lai et al (2013) reported autopsies performed on four patients with XP, two of which had neural degeneration either due to XP-A or XP-D. Numerous brain abnormalities were observed, particularly in the patient with XP-D. Among these were diffuse brain atrophy, cortical sclerosis, thin corpus callosum, and neuronal loss in the outer cortex, hippocampus, basal ganglia, and cerebellum (Lai et al, 2013). The cortical and corpus callosum findings are of particular relevance to the auditory findings of our patient. Our patient demonstrated considerable difficulty in the dichotic subtests of competing words and sentences, and his scores did not improve with age. Performance on these tests relies on interhemispheric transfer facilitated by the corpus callosum in the integration (competing words) and separation (competing sentences) of dichotic material (Bellis, 2003).

Temporal bone histopathology has been reported in one patient with XP-A and one patient with XP-D, both with neural degeneration, to assess pathological processes in the inner ear (Viana et al, 2013). Numerous abnormalities were observed in both patients, with the patient with XP-D showing a more severe inner ear presentation. These included severe atrophy or absence of the organ of Corti, scattered atrophy of the stria vascularis, and severe atrophy of the cochlear neurons and spiral ganglia (Viana et al, 2013). These findings indicate both sensory and neural components to the hearing loss in these patients. Taken together with the autopsy findings in the brain, a central component can be added to the picture. Chronological audiometric data obtained on our patient display sensory, neural, and central components to his hearing loss. Audiological tests may overlap in the auditory processes assessed. For example, the auditory figure-ground subtest may be impaired with sensory, neural, or central hearing loss. Although auditory closure ability did improve in our patient with age, as evidenced by improvement in performance in the filtered words subtest, auditory figure-ground abilities remained very poor.

Our patient was diagnosed clinically with CMT prior to the XP diagnosis. It is difficult to assess which clinical features to assign to each disorder. Clearly, there is

This document was downloaded for personal use only. Unauthorized distribution is strictly prohibited.

some overlap between the two disorders, including reduced deep tendon reflexes, peripheral neuropathy, and hearing loss. The characterization of his hearing loss appears to align more closely with what has been reported for patients with XP with neural degeneration. Auditory deficits commonly associated with CMT include auditory neuropathy and impaired MLD (Rance et al, 2012), neither of which were evident in our patient. However, it is possible that MLD had not been affected at the time of assessment. Impairment in gap detection, also reported in CMT (Rance et al, 2012), was seen in our patient, though it is possible the results of this test were confounded by the degree of his hearing loss at that time. Because of the severity of the patient's hearing loss, presentation intensity was increased to most comfortable listening level, but we cannot rule out a peripheral contribution to the gap detection test results. It should be noted that hearing loss is not always observed in patients with CMT (Rance et al, 2012).

Although the hearing loss appears to be attributable to XP with neural degeneration, the presence of CMT cannot be ruled out. The patient has had surgery for a foot deformity, described as a "claw-toe" deformity characteristic of CMT. To our knowledge, there is no report in the literature of a patient with XP with such a deformity. The negative genetic test results do not exclude a diagnosis of CMT. With over 50 genes associated with CMT (Siskind et al, 2013), there are still many genes that were not investigated in this patient. Furthermore, the tests performed were analyses of specific mutations in several known CMT genes. This does not exclude the presence of rarer mutations, deletions, or duplications in the genes tested. Therefore, the possibility of CMT in this patient still exists. Genetic testing for CMT was abandoned subsequent to the XP diagnosis because of the large costs of continued testing and the supplantation of XP as the predominant health concern. He continues to be followed up for CMT-related issues, including pain management, physical therapy, occupational therapy, and surgical intervention.

The prognosis for XP with neural degeneration is poor, with life expectancy estimated at the third or fourth decade of life (Bradford et al, 2011). Neural degeneration is progressive and is predicted to follow progression of hearing loss (Totonchy et al, 2013). Otherwise, the clinical course and rate of progression is somewhat unpredictable. The progression of hearing loss in our patient appears to be more rapid than such patients reported in the literature (Totonchy et al, 2013). It is unclear whether this represents individual variability, or if the patient's other diagnoses have a synergistic effect on the course of his hearing loss. The possibility of auditory effects due to CMT contributing to his presentation cannot be ruled out.

His development of type 1 diabetes at 13 yr of age further complicates the clinical picture. Interestingly, XP-D genetic expression was found to be inhibited in vitro when cells were exposed to prolonged high concentrations of glucose (Liu et al, 2015). Since our patient has a history of poorly controlled blood glucose levels, it is feasible that diabetes may accelerate the progression of XP-associated neural degeneration by further reducing residual DNA repair. There are many genes associated with type 1 diabetes, though its etiology is not necessarily genetic (Kharroubi and Darwish, 2015).

The presence of three distinct diagnoses with genetic associations is highly unusual. We hypothesized that a chromosomal aberration could be the underlying mechanism for all three disorders, and therefore performed chromosome analysis on a peripheral blood sample from this patient. Chromosomal rearrangements occur on a larger scale than a single-gene disorder. Therefore, chromosomes can be examined microscopically at the cellular level. A section of a chromosome can be deleted, duplicated, or inverted, which can affect multiple genes that are located on the same chromosome. Alternatively, genetic material can be exchanged between non-homologous or homologous chromosomes, known as translocation. Genes can sometimes be deleted or duplicated when a translocation occurs. Chromosome analysis was normal in this patient.

In summary, here we described an adult male with XP subtype D with neural degeneration. Our serial audiological evaluations up to 18½ yr of age showed a rapidly progressive bilateral sensorineural hearing loss with poor electrophysiological waveform morphology and global auditory processing deficits. He had additional diagnoses of type 1 diabetes and CMT, which may contribute to the auditory findings exhibited by this patient. We provided electrophysiological and auditory processing evaluations in conjunction with basic audiometric data. The use of MLR and LEP recordings may prove to be useful in some patients with XP with neural degeneration. Unfortunately, the rapid progression of hearing loss exhibited by our patient precluded continuous successful monitoring of these potentials. Though the MLR was abnormal at 8 yr of age, this may have been due to a lack of maturation in the central auditory pathway, as responses were normal at 11 yr of age. LEP recordings obtained when the patient was 18 yr of age showed poor morphology, which may be indicative of cortical thinning observed in patient autopsies (Lai et al, 2013). However, the severity of the patient's hearing loss may be responsible for this decline in waveform morphology.

This case expands on previously reported auditory findings for XP with neural degeneration and may indicate the need for an auditory processing evaluation in other young patients with this disease. Periodic audiological evaluations provide information on disease progression since hearing loss is an indicator of neural decline (Totonchy et al, 2013). Inclusion of early, middle,

This document was downloaded for personal use only. Unauthorized distribution is strictly prohibited.

and late evoked potentials may be useful in assessment of these patients, though insufficient data exist to make this determination. Our case demonstrates the value of the audiologist in the facilitation of an accurate diagnosis through referral of patients with unusual clinical findings to geneticists, as appropriate (Mercer, 2015). Hearing loss is part of the clinical presentation in over 400 genetic syndromes (Angeli et al, 2012), including XP with neural degeneration and CMT. The auditory findings were a valuable contribution to the ultimate diagnosis of this patient.

REFERENCES

Angeli S, Lin X, Liu XZ. (2012) Genetics of hearing and deafness. *Anat Rec (Hoboken)* 295(11):1812–1829.

Balfour PB, Pillion JP, Gaskin AE. (1998) Distortion product otoacoustic emission and auditory brain stem response measures of pediatric sensorineural hearing loss with islands of normal sensitivity. *Ear Hear* 19(6):463–472.

Barch M, Knutsen T, Spurbeck JL. (1997) *The AGT Cytogenetics Laboratory Manual*. 3rd ed. Philadelphia, PA: Lippincott-Raven.

Bellis T. (2003) *Assessment and Management of Central Auditory Processing Disorders in the Educational Setting: From Science to Practice*. 2nd ed. Clifton Park, NY: Delmar Learning.

Bowden NA, Beveridge NJ, Ashton KA, Baines KJ, Scott RJ. (2015) Understanding xeroderma pigmentosum complementation groups using gene expression profiling after UV-light exposure. *Int J Mol Sci* 16(7):15985–15996.

Bradford PT, Goldstein AM, Tamura D, Khan SG, Ueda T, Boyle J, Oh KS, Imoto K, Inui H, Moriwaki S, Emmert S, Pike KM, Raziuddin A, Plona TM, DiGiovanna JJ, Tucker MA, Kraemer KH. (2011) Cancer and neurologic degeneration in xeroderma pigmentosum: long term follow-up characterises the role of DNA repair. *J Med Genet* 48(3):168–176.

Butinar D, Starr A, Zidar J, Koutsou P, Christodoulou K. (2008) Auditory nerve is affected in one of two different point mutations of the neurofilament light gene. *Clin Neurophysiol* 119(2): 367–375.

Butinar D, Zidar J, Leonardis L, Popovic M, Kalaydjieva L, Angelicheva D, Sininger Y, Keats B, Starr A. (1999) Hereditary auditory, vestibular, motor, and sensory neuropathy in a Slovenian Roma (Gypsy) kindred. *Ann Neurol* 46(1):36–44.

Halkud R, Shenoy AM, Naik SM, Chavan P, Sidappa KT, Biswas S. (2014) Xeroderma pigmentosum: clinicopathological review of the multiple oculocutaneous malignancies and complications. *Indian J Surg Oncol* 5(2):120–124.

Hirai Y, Kodama Y, Moriwaki S, Noda A, Cullings HM, Macphee DG, Kodama K, Mabuchi K, Kraemer KH, Land CE, Nakamura N. (2006) Heterozygous individuals bearing a founder mutation in the XPA DNA repair gene comprise nearly 1% of the Japanese population. *Mutat Res* 601(1–2):171–178.

Howe B, Umrigar A, Tsien F. (2014) Chromosome preparation from cultured cells. *J Vis Exp* 83(83):e50203.

Jani-Acsadi A, Ounpuu S, Pierz K, Acsadi G. (2015) Pediatric Charcot-Marie-Tooth disease. *Pediatr Clin North Am* 62(3):767–786.

Jerger J, Johnson K. (1988) Interactions of age, gender, and sensorineural hearing loss on ABR latency. *Ear Hear* 9(4): 168–176.

Keith RW. (2009) *SCAN-3:C Tests for Auditory Processing Disorders for Children*. San Antonio, TX: Pearson Clinical Assessment Group.

Kharroubi AT, Darwish HM. (2015) Diabetes mellitus: the epidemic of the century. *World J Diabetes* 6(6):850–867.

Kleijer WJ, Laugel V, Berneburg M, Nardo T, Fawcett H, Gratchev A, Jaspers NG, Sarasin A, Stefanini M, Lehmann AR. (2008) Incidence of DNA repair deficiency disorders in western Europe: xeroderma pigmentosum, Cockayne syndrome and trichothiodystrophy. *DNA Repair (Amst)* 7(5):744–750.

Kovach MJ, Campbell KC, Herman K, Waggoner B, Gelber D, Hughes LF, Kimonis VE. (2002) Anticipation in a unique family with Charcot-Marie-Tooth syndrome and deafness: delineation of the clinical features and review of the literature. *Am J Med Genet* 108(4):295–303.

Kraemer KH, DiGiovanna JJ. (2014) Xeroderma pigmentosum. In: *GeneReviews (Internet)*. Seattle, WA: University of Washington. http://www.ncbi.nlm.nih.gov/books/NBK1397/. Accessed September 21, 2015.

Lai JP, Liu YC, Alimchandani M, Liu Q, Aung PP, Matsuda K, Lee CC, Tsokos M, Hewitt S, Rushing EJ, Tamura D, Levens DL, Digiovanna JJ, Fine HA, Patronas N, Khan SG, Kleiner DE, Oberholtzer JC, Quezado MM, Kraemer KH. (2013) The influence of DNA repair on neurological degeneration, cachexia, skin cancer and internal neoplasms: autopsy report of four xeroderma pigmentosum patients (XP-A, XP-C and XP-D). *Acta Neuropathol Commun* 1:4–20.

Lehmann AR, McGibbon D, Stefanini M. (2011) Xeroderma pigmentosum. *Orphanet J Rare Dis* 6:70–75.

Liu Z, Zhao W, Zhang Q, Lai L, Jiang S, Zhang J, Xu S. (2015) Increased oxidative damage and reduced DNA repair enzyme XPD involvement in high glucose-mediated enhancement of levobupivacaine-induced neurotoxicity. *Neurochem Res* 40(9):1919–1928.

Mareddy S, Reddy J, Babu S, Balan P. (2013) Xeroderma pigmentosum: man deprived of his right to light. *ScientificWorldJournal* 2013:534752.

Mercer D. (2015) Guidelines for audiologists on the benefits and limitations of genetic testing. *Am J Audiol* 24(4):451–461.

National Institute of Neurological Disorders and Stroke (NINDS). *Charcot-Marie-Tooth disease fact sheet*. http://www.ninds.nih.gov/disorders/charcot_marie_tooth/detail_charcot_marie_tooth.htm. Accessed September 13, 2015.

Patzkó A, Shy ME. (2011) Update on Charcot-Marie-Tooth disease. *Curr Neurol Neurosci Rep* 11(1):78–88.

Rance G, Ryan MM, Bayliss K, Gill K, O'Sullivan C, Whitechurch M. (2012) Auditory function in children with Charcot-Marie-Tooth disease. *Brain* 135(5):1412–1422.

Robbins JH, Kraemer KH, Lutzner MA, Festoff BW, Coon HG. (1974) Xeroderma pigmentosum: an inherited diseases with sun sensitivity, multiple cutaneous neoplasms, and abnormal DNA repair. *Ann Intern Med* 80(2):221–248.

Saporta ASD, Sottile SL, Miller LJ, Feely SME, Siskind CE, Shy ME. (2011) Charcot-Marie-Tooth disease subtypes and genetic testing strategies. *Ann Neurol* 69(1):22–33.

This document was downloaded for personal use only. Unauthorized distribution is strictly prohibited.

Satya-Murti S, Cacace AT, Hanson PA. (1979) Abnormal auditory evoked potentials in hereditary motor-sensory neuropathy. *Ann Neurol* 5(5):445–448.

Siskind CE, Panchal S, Smith CO, Feely SM, Dalton JC, Schindler AB, Krajewski KM. (2013) A review of genetic counseling for Charcot Marie Tooth disease (CMT). *J Genet Couns* 22(4):422–436.

Starr A, Michalewski HJ, Zeng FG, Fujikawa-Brooks S, Linthicum F, Kim CS, Winnier D, Keats B. (2003) Pathology and physiology of auditory neuropathy with a novel mutation in the *MPZ* gene (Tyr145→Ser). *Brain* 126(7):1604–1619.

Starr A, Picton TW, Sininger Y, Hood LJ, Berlin CI. (1996) Auditory neuropathy. *Brain* 119(3):741–753.

Sugimoto J, Kohyama J, Shimohira M, Iwakawa Y. (1999) Auditory brainstem responses in group A xeroderma pigmentosum. *No To Hattatsu* 31(3):276–279.

Totonchy MB, Tamura D, Pantell MS, Zalewski C, Bradford PT, Merchant SN, Nadol J, Khan SG, Schiffmann R, Pierson TM, Wiggs E, Griffith AJ, DiGiovanna JJ, Kraemer KH, Brewer CC. (2013) Auditory analysis of xeroderma pigmentosum 1971–2012: hearing function, sun sensitivity and DNA repair predict neurological degeneration. *Brain* 136(1):194–208.

Viana LM, Seyyedi M, Brewer CC, Zalewski C, DiGiovanna JJ, Tamura D, Totonchy M, Kraemer KH, Nadol JB, Jr. (2013) Histopathology of the inner ear in patients with xeroderma pigmentosum and neurologic degeneration. *Otol Neurotol* 34(7):1230–1236.

This document was downloaded for personal use only. Unauthorized distribution is strictly prohibited.