

## Original Article

# Unfavourable results with distraction in craniofacial skeleton

**Rajiv Agarwal**

Department of Plastic Surgery and Burns, Sanjay Gandhi Postgraduate Institute of Medical Sciences, Lucknow, Uttar Pradesh, India

**Address for correspondence:** Dr. Rajiv Agarwal, A-15 Nirala Nagar, Lucknow - 226 020, Uttar Pradesh, India. E-mail: drrajivagarwal@gmail.com

### ABSTRACT

Distraction osteogenesis has revolutionised the management of craniofacial abnormalities. The technique however requires precise planning, patient selection, execution and follow-up to achieve consistent and positive results and to avoid unfavourable results. The unfavourable results with craniofacial distraction stem from many factors ranging from improper patient selection, planning and use of inappropriate distraction device and vector. The present study analyses the current standards and techniques of distraction and details in depth the various errors and complications that may occur due to this technique. The commonly observed complications of distraction have been detailed along with measures and suggestions to avoid them in clinical practice.

### KEY WORDS

Complications; distraction osteogenesis; unfavourable results

### INTRODUCTION

The discovery, results and success of distraction osteogenesis (DO) in the craniofacial skeleton has spurred many surgeons to undertake this technique for correcting craniofacial skeletal deformities. Many surgeons are however not formally trained in the intricacies of distraction and this may lead to a high number of complications.


Ilizarov, the architect of DO once said, 'There are no complications with the technique, there are only inexperienced surgeons causing problems for their patients'. The technique of distraction is comparatively new for the

craniofacial region when compared with the axial skeleton where the experience is more than 50 years old. The first report demonstrating the application of Ilizarov's principles to the craniofacial region appeared in 1973.<sup>[1]</sup> Although there are anatomic differences between the axial and craniofacial skeletons, the pattern of complications seen in craniofacial DO are quite similar to those seen with axial skeleton orthopaedic procedures. The analysis of the various complications and pitfalls may help to minimise the complications for the beginner endeavouring to perform DO.

This paper will review the pitfalls and complications associated with craniofacial DO in light of its biology, biomechanics and the hardware design of the distractors and would suggest methods to help minimise them in clinical practice.

### PHASES AND BIOMECHANICS OF DO

The sequential phases of DO are (a) osteotomy, (b) latency, (c) distraction, (d) consolidation and (e) remodelling.

Access this article online	
Quick Response Code:	Website: www.ijps.org
	DOI: 10.4103/0970-0358.118594

Surgical sectioning of the bone is called osteotomy and it should aim for completeness and maximum preservation of the periosteum. The latency period is the period from bone division to the onset of traction and represents the time allowed for reparative callus formation. The distraction commences after the latency period and is characterised by the application of traction forces to the osteotomised bone segments. The consolidation phase commences as soon as the distraction has been stopped. During this phase, the regenerate converts into bone by the process of mineralisation. Following consolidation phase, remodelling starts, which is the period from full functional loading to the complete remodelling of the newly formed bone. It takes a year or more before the structure of newly formed bone is comparable with that of pre-existing bone.

It is important to understand the above biomechanics of DO as this process causes changes in both the skeletal and soft-tissues. All the soft-tissues including the skin, nerve, muscle are affected by distraction in a particular way and this has bearings on the protocol and surgical technique of distraction<sup>[2-5]</sup> [Figure 1].

## PLANNING AND EVALUATION FOR DO

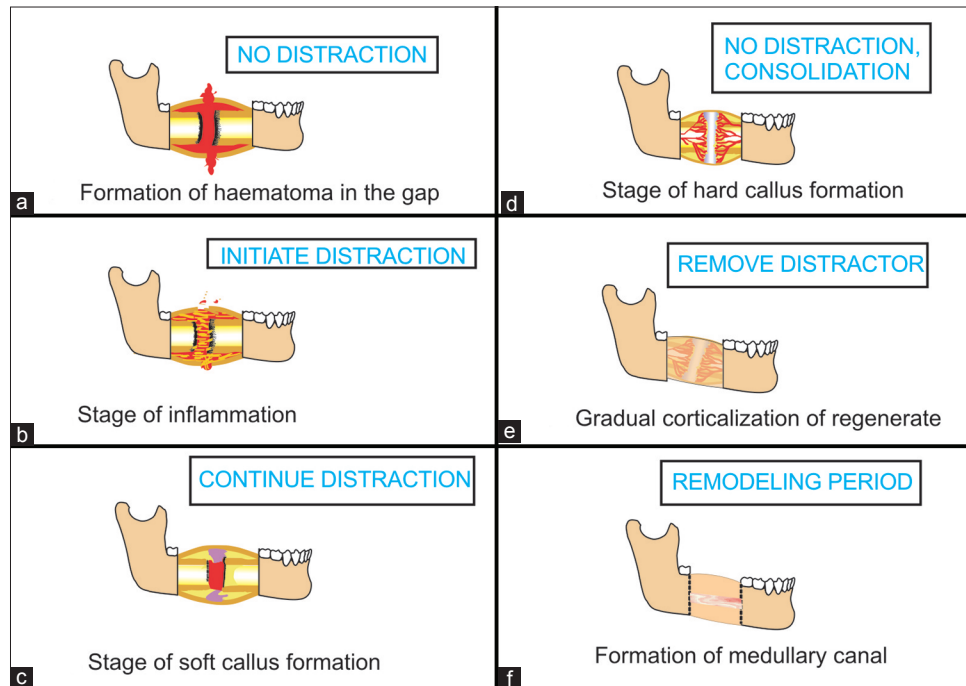
Treatment planning for DO requires a detailed clinical examination, cephalometric analysis, dental cast analysis and three dimensional computed tomographic (3D CT) analysis so that a treatment plan is developed based on occlusive and functional goals.

### Clinical examination

Patient is viewed in natural head position, lips relaxed, seated condyle position and first tooth contact. Important anteroposterior, vertical, midline, level and outline features of the face are recorded in an organised fashion [Table 1].<sup>[6]</sup> Once the facial asymmetry is evaluated objectively, the required surgical procedure is planned accordingly.

### Cephalometric analysis

A variety of cephalometric analyses are available to map the precise location and extent of the deformity. The lateral cephalometric radiographs along with the posteroanterior cephalogram offer an effective tool for evaluating the craniofacial structures in transverse and vertical directions.



**Figure 1:** The cascade of cellular events occurring in the osteotomy gap after the bone ends are gradually separated by incremental traction correlated clinically with surgical technique of distraction. The schematic drawings illustrating the events are the same for both axial and craniofacial skeleton. (a) A haematoma is the first event that occurs after an osteotomy. The haematoma is converted to a clot and bone necrosis occurs at the ends of the fracture segments. (b) There is an ingrowth of vasoformative elements and capillaries for the restoration of blood supply along with cellular proliferation. The clot is replaced with granulation tissue consisting of inflammatory cells, fibroblasts, collagen and invading capillaries. (c) The granulation tissue is converted to fibrous tissue by fibroblasts leading to the formation of soft callus with distinct zones. (d) The five zonal architecture of distraction regenerate contains radiolucent fibrous interzone, two radiodense mineralisation zones and two radiolucent zones of remodelling adjacent to the residual host bone segments. (e) Gradual corticalization of the remodelling zone. (f) Formation of the medullary canal

**Dental cast analysis**

Dental casts provide information on the shape of the arches, symmetry and amount of crowding, curve of

**Table 1: Three dimensional clinical facial evaluation form. Important parameters for clinical examination are listed which form the basis for planning the surgical management**

Clinical facial examination					
Name:	Age:	Diagnosis:			
Frontal view					
Vertical					
Overbite					
Upper lip height					
Interlabial gap					
Lower lip height					
Lower third height					
Maxillary incisor exposure (relaxed)					
Maxillary incisor exposure (smile)					
Maxillary incisor height					
Upper vermillion					
Lower vermillion					
Profile					
Orbital rim	Flat	Soft	Normal	Prominent	Depressed
Cheek bone	Flat	Soft	Normal	Prominent	Depressed
Facial levels		Side of deviation		Side of deviation	
Eyes	Right down		Left down		
Mx canine	Right down		Left down		
Md canine	Right down		Left down		
Chin level	Right down		Left down		
Outlines		Side of deviation		Side of deviation	
General	Wide		Narrow		
Zygomatic arch	Right down		Left down		
	Right up		Left up		
Md body	Right large		Left large		
	Right wide		Left wide		
Chin level	Wide		Narrow		
Midlines		Side of deviation		Side of deviation	
Nasal tip	Towards the right		Towards left		
Philtrum	Towards the right		Towards left		
Chin	Towards the right		Towards left		

Adapted from arnett and bergman (1993)<sup>61</sup>

spee, shape, number and size of the teeth, diastemata and rotations. Two main methods that are used for cast analysis are direct measurement and occlusogram analysis.

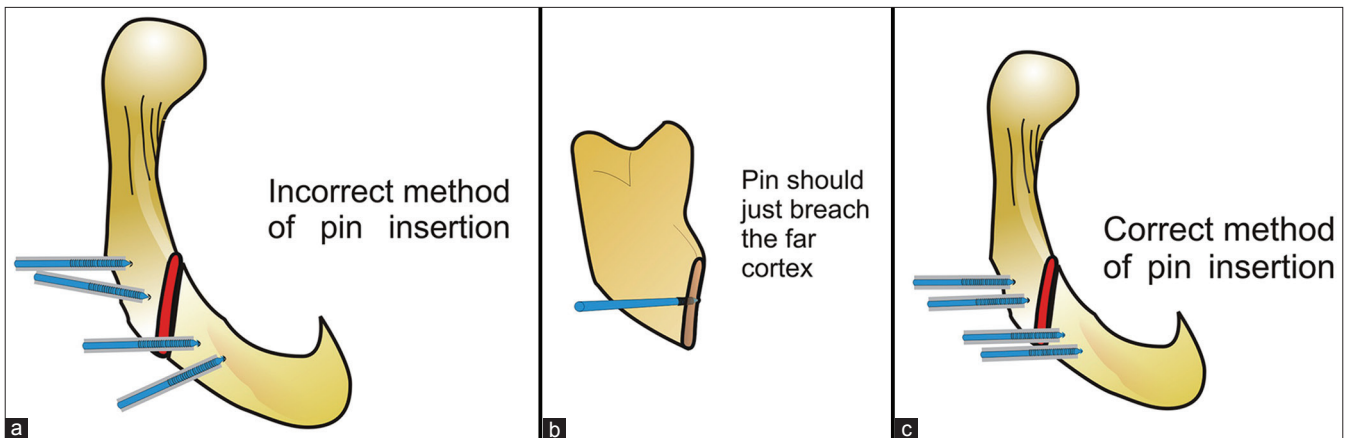
**3D CT**

3D CT allows precise and spatial orientation of the deformed bone, which can be measured and evaluated in all dimensions. Stereolithographic models further help in the precise surgical planning and placement of vector of distraction.

**TECHNIQUE AND DEVICES FOR DO**

The bone cut and sites of pin placement should be marked on either side of the osteotomy. Pin insertion should precede osteotomy making sure that the anchoring pins should be at a plane perpendicular to the surface of the bone. The sharp end of the pin should just breach the opposite cortex for good anchorage [Figure 2]. Complete osteotomy should be performed and due care should be taken not to violate underlying unerupted teeth, roots of teeth, neurovascular bundle and other vital structures. The distraction device should be secured using the anchoring pins and a test distraction should be performed intraoperatively to make sure that the fixation of the device and the osteotomy is complete. After a latency period of 3-5 days, distraction should be commenced at a rate of 1 mm/day. Following completion of distraction, the consolidation period of 4-8 weeks is required.

The distraction devices can be classified on the basis of location as external and internal. The external distractors



**Figure 2:** The incorrect and correct method of pin insertion into the bone. (a) Incorrect method as the pins are not parallel to each other and are also entering the bone at an angle. (b) The sharp end of the pin after correct insertion should just breach the far cortex of the bone. (c) The correct method of putting pins into the bones is that all the pins should be parallel to each other and should enter the bone at a right angle to the surface of the bone to maximise anchorage and purchase into the bone

are placed over the skin surface and common ones are the rigid external distractor and the mandibular external distractors.<sup>[7]</sup> The internal distractors are placed either submucosally (buried) or extramucosally (intraoral). There have been continuous advancements in the design of distractors for improvements in terms of stability on the bone and the versatility of distraction. The author has developed a three hole unidirectional distractor, which allows unmatched stability on the bone [Figure 3a] and a curved mandibular distractor, which allows stabilisation of the segmentally deficient mandible along with simultaneous distraction [Figure 3b].<sup>[8,9]</sup>

## ERRORS DURING DO

It is important to differentiate between errors and complications to better define the scope of complications in craniofacial distraction.<sup>[10]</sup> An error is an inattentive action that results in a deviation of the course of treatment thereby leading to the development of a complication. A complication is an unexpected deviation from the treatment plan that without appropriate correction will lead to worsening of the existing, development of a new or recurrence of the initial pathologic process. There is however no correlation between error and complications and one error can lead to many complications. For example, an inappropriately fast rate of distraction can lead to poor regenerate consolidation, non-union or even nerve palsy.

The errors that may occur during DO can be divided into two groups: (a) iatrogenic errors made by the treating

surgeon or other medical personnel and (b) patient related errors are those which are made by patients or their parents. The iatrogenic errors can be further subdivided into (a) primary or strategic errors, which are made during treatment planning, (b) secondary or tactical errors, which are usually made as a result of poor decisions when correcting a developing or previously developed complication. The technical errors are those that are made during a surgical procedure or during application of a distraction device [Table 2].<sup>[11]</sup>

## COMPLICATIONS OF DO

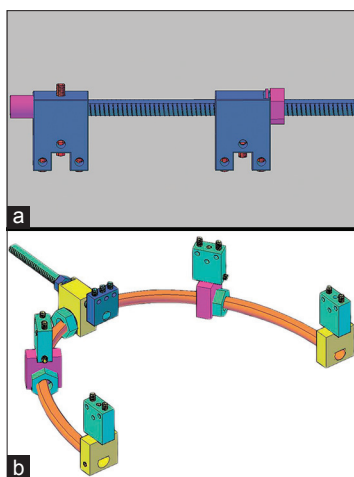
The complications of distraction can be studied by dividing them into two categories, technical complications and general complications. The technical complications relate to the quality of regenerate, axial deviations, soft-tissue components and infection [Table 3].

### Technical complications

Some of the common technical complications are described.

#### *Regenerate disorders*

This group of complications is the result of inadequate tension applied to the forming regenerate tissues. The regenerate bone formation is also influenced by the soft-tissue interposition or extensive bone segment motion. A hypotrophic regenerate is characterised by a delay in the formation of bone tissue and this type of regenerate may progress to delayed consolidation of the newly formed tissues. Development of partial or hypotrophic regenerate is difficult to control by manipulating the distraction parameters.<sup>[12]</sup> The technical errors that may lead to a hypotrophic regenerate include an inappropriately performed osteotomy with damage to the osteogenic tissue and instability of the distraction device, which in turn may also lead to recurring damage to the newly formed regenerate tissues.<sup>[13,14]</sup> A hypertrophic regenerate is characterised by an excessive rate of bone formation leading to premature consolidation. This may require a secondary osteotomy to continue with the distraction process.<sup>[15,16]</sup> The hypertrophic regenerate tendency can be diagnosed by progressively decreasing width of the interzone, uniform tissue density throughout the intersegmentary gap and a large volume of regenerate tissue. This type of regenerate such as a hypotrophic regenerate can be due to strategic error including use of normal distraction parameters for young children, excessive elevation of the periosteum and instability of the distraction device or application of



**Figure 3a:** The three-hole unidirectional external bone distractor. This allows controlled and graduated distraction of the bone utilising the stability and versatility of the three hole pattern of pin placement (patent pending).  
**(b)** The mandibular stabilisation and transport distraction system. This allows simultaneous stabilisation and transport distraction of the segmentally deficient mandible (patent pending)

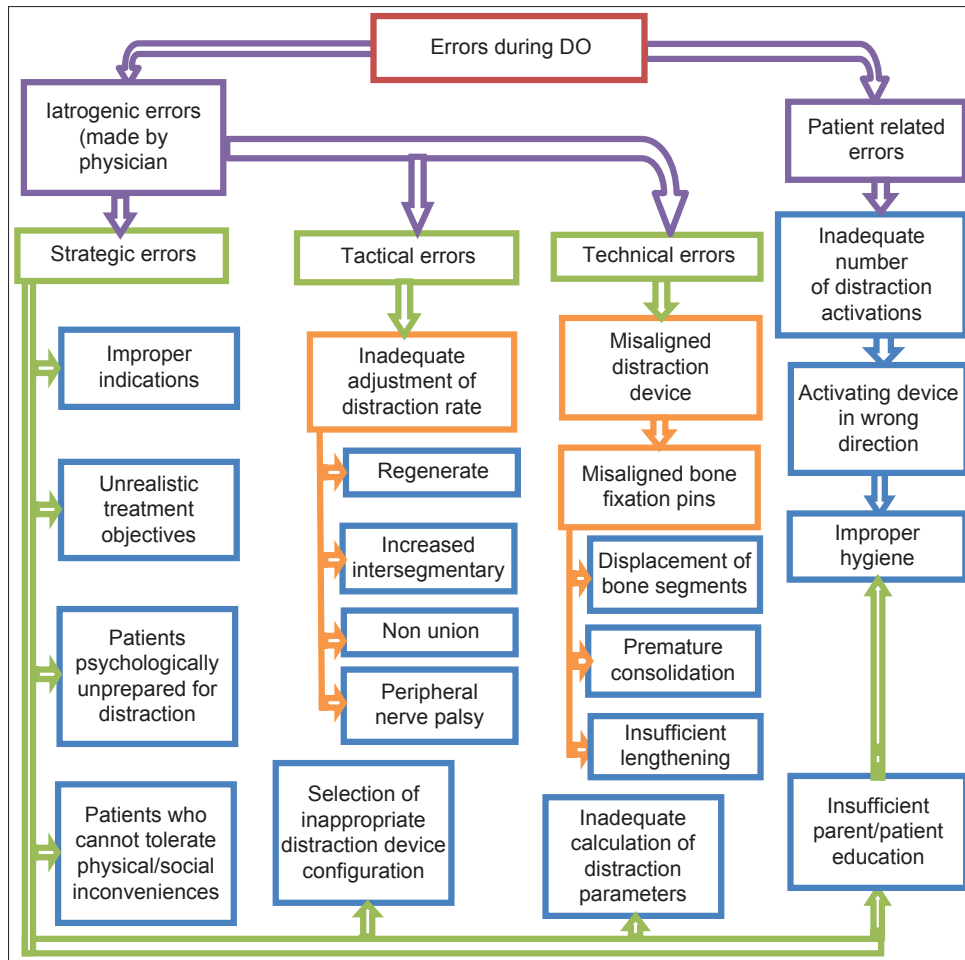


Table 2: Errors during distraction osteogenesis

compression forces between the bone segments during the latency period.

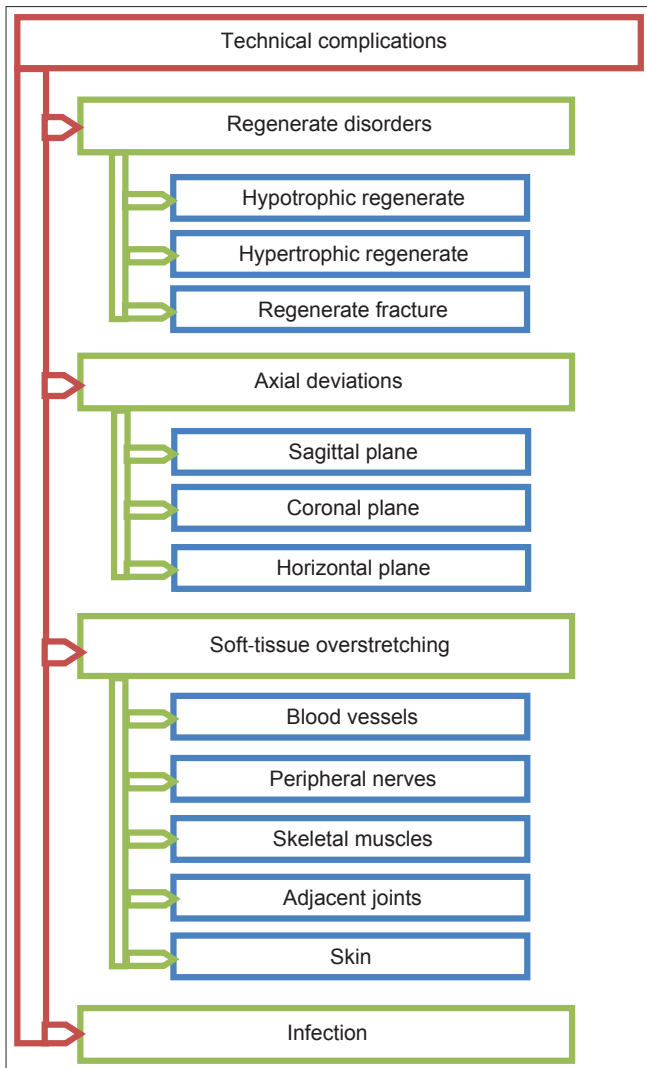
Fractures of the distraction regenerate usually occur during the remodelling period after removal of the distractor. The strategic errors that might lead to fracture include an inadequate duration of the consolidation period, an aggressive functional rehabilitation during remodelling or due to incorrect evaluation of the tissue maturity.

**Axial deviations**

Axial deviation of the distracted segment in any of the three axes may lead to complications commonly seen during DO.<sup>[17]</sup> Axial deviation of the distraction segment may occur due to strategic errors including use of inappropriate size and strength of the device, inadequate osteotomy level or inadequate device orientation. Technical and tactical errors leading to axial deviation include incorrect alignment of the distraction rod, insufficient anchorage of the distractor, over correction of the deformity and an incorrect rate of distraction.

**Soft-tissue overstretching**

The forces of distraction in addition to helping in distraction of the bone ends may also at times lead to soft-tissue overstretching. The anchoring pins of the distraction device may also cause focal gradual compression. The response of the soft-tissues varies for various types of tissue. Blood vessels have a high degree of adaptation to tension stress and are the ones to appear first in the distraction gap.<sup>[18]</sup> Stretching of the blood vessels may create ischaemia in some cases, but this is easily correctable. The incidence of peripheral nerves complications during DO varies between 2% and 15%.<sup>[19]</sup> The peripheral nerve damage may occur as a result of direct injury at the time of device application or it may happen due to progressive oedema. The nerves allow stretching up to 15-20% of their length before symptoms of loss of sensation and motor function appear. Muscles tolerate stretching if the amount of lengthening does not exceed beyond 20% of the original segment length.<sup>[20]</sup> The first signs of muscle overstretching are limited range of motion, tenderness, joint contracture and pain. In addition



**Table 3:** Technical complications during distraction osteogenesis

to these, other soft-tissues like adjacent joints may also be affected by overstretching. Focal areas of cartilage atrophy and necrosis may occur and lead to dystrophic changes and permanent damage to joint function.<sup>[21]</sup>

**Infection**

The rate of septic complications reported during the application of DO varies between 5% and 30%.<sup>[18]</sup> These complications are more due to the application of the external distraction devices and comprise of a range of problems from pin tract inflammation to osteomyelitis.

**Specific complications**

The specific complications of DO are categorised as intra-operative, intradistraction and post-distraction. This classification stems from the fact that the process of DO actually extends over a period of time when the bones and the soft-tissues are being manipulated and hence

complications may also arise in this period [Table 4]. The intraoperative complications seen during DO include bleeding, neurosensory defects, inadequate osteotomy, bone fracture and last, but not the least those associated with distraction device. The device associated complications include placement of the device or pins in an unsatisfactory position and complications associated with orientation of the fixation pins.

An incomplete osteotomy leads to failure to distract. The commonest sites of incomplete osteotomy are the postero-medial part of the maxillary tuberosity, the vertical plate of the palatine bone in the lateral nasal wall and the incomplete dysjunction of the pterygoids.<sup>[22]</sup> It is important to ensure completeness of the osteotomy before applying the distraction device. An incompletely performed osteotomy can be diagnosed by complaints of difficulty in distraction along with pain during distraction. Failure to recognise this leads to undue stress on the fixation pins culminating in either loosening of the pins at the site of bone anchorage or loosening of the pins at their site of distractor clamp anchorage.

Complications associated with the distraction and consolidation periods include inappropriate distraction vector, pin infections, device loosening, device failure, pin tract formation, soft-tissue entrapment, asymmetrical distraction, premature consolidation, dentigerous cyst formation, coronoid process interference, fibrous pseudoarthrosis, paresthesias and trismus. Loosening of the pins is a fairly common complication and is seen with the halo distractors, in which the pins holding the halo frame the skull come loose. Asymmetrical distraction is a troublesome complication of distraction. This occurs in cases where bilateral distraction devices have been applied to correct bone deficiency and one device fails to distract after some time. This commonly occurs in the setting of midface distraction for midface retrusion associated with congenital craniofacial syndromes where internal devices have been placed. The surgeon is left with only two options in this situation, one is to stop the procedure of distraction and let the patient consolidate and the other is to re-explore, diagnose the cause of device jamming and either rectify the cause or put in a new device. A very common cause is soft-tissue entrapment over the exposed threads of the distraction arm in the internal midface devices. The other causes of an asymmetrical distraction are improper adjustment of the device, asymmetric maxillary segments and dense fibrosis in a particular segment.

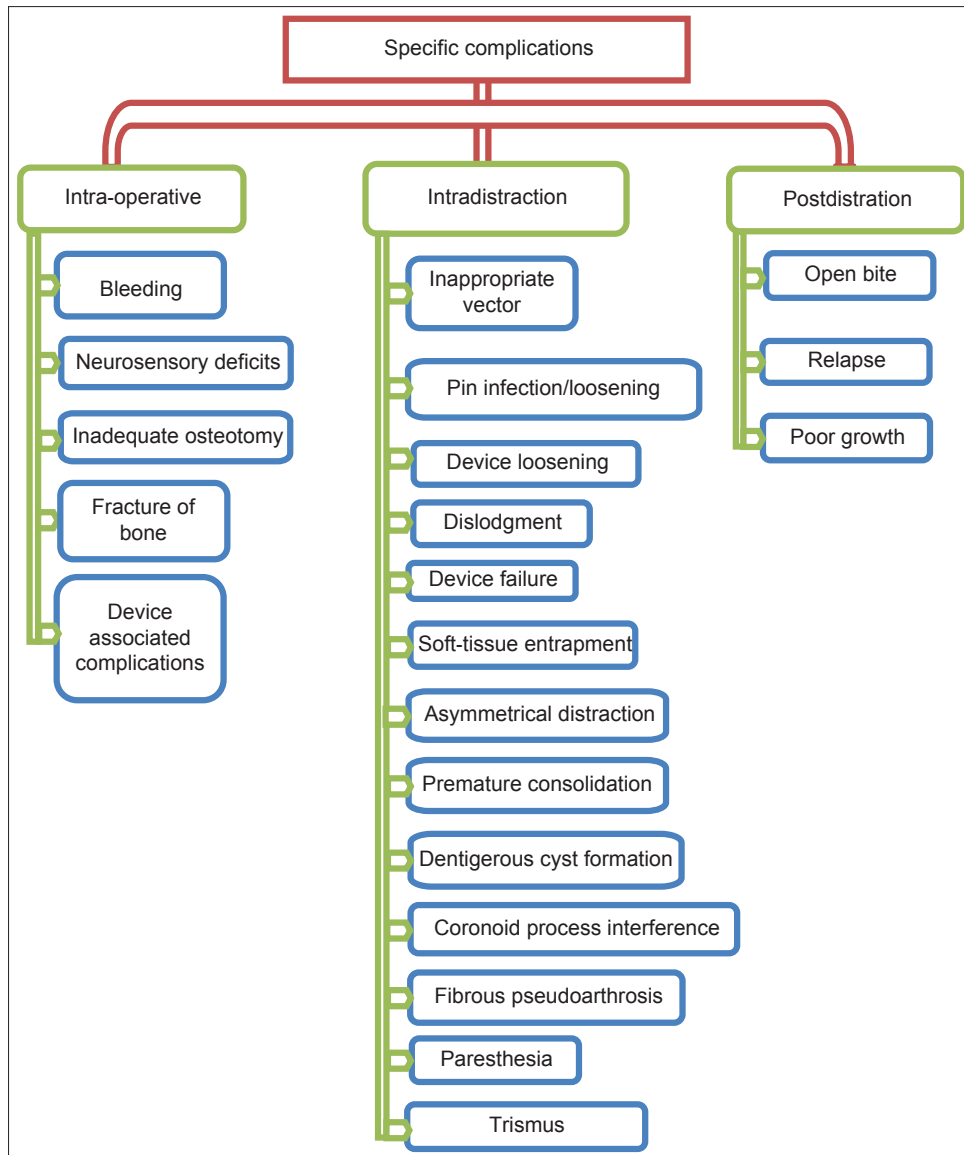


Table 4: Specific complications during distraction osteogenesis

The post-distraction complications centre around the failure to achieve the planned result. This may be due to appearance of malocclusion, early relapse and poor growth after distraction.

### AVOIDING COMPLICATIONS IN DO

Some of the common errors and complications with DO are being described with clinical photographs to illustrate the aetiology and clinicoradiologic presentation.

#### Hypotrophic regenerate

A hypotrophic regenerate is characterised by delay or lack of mineralisation of the distraction gap [Figure 4].

Radiologically, the first sign of this complication is radiolucency in the distraction gap, a wide radiolucent interzone and an irregular density of mineralising zones of the regenerate. Pseudoarthrosis may result as a result of these events during the late consolidation phase or remodelling phase. A hypotrophic regenerate can result from strategic errors including poor patient selection. Patients with vitamin deficiency, malnutrition, metabolic disorders or previous chemotherapy are more likely to end up with this type of regenerate pathology although it may occur in the absence of these preconditions. Hypotrophic regenerate can be prevented by improving the fixation method of the distractor, increasing the latency period, decreasing the rate of distraction and by increasing the consolidation period. Correction of

axial deviation of the distracted bone segment needs reversal of the cause of the deviation. This may include replacement of the distraction device, reorienting the entire distraction device, adjusting the parameters of distraction, elastic fixation or even surgical manipulation may also be required if the regenerate has mineralised.

### Cutaneous scars

Cutaneous scars are associated with external distractors and occur in the path of pin movement [Figure 5]. These scars can be minimised by pinching the skin between the transcutaneous pins along the trajectory of the device. Secondly, judicious placement of the sites of pins in less conspicuous areas can also reduce the stigma associated with these scars. Cutaneous scars with above precautions usually heal well, but in case of prominent scars they can be dealt the usual methods of pressure, triamcinolone injection therapy or scar revision. Cutaneous scars can be unacceptable sometimes with the external distractors while this complication can be minimised by using internal distractors.

### Misdirected vector of distraction

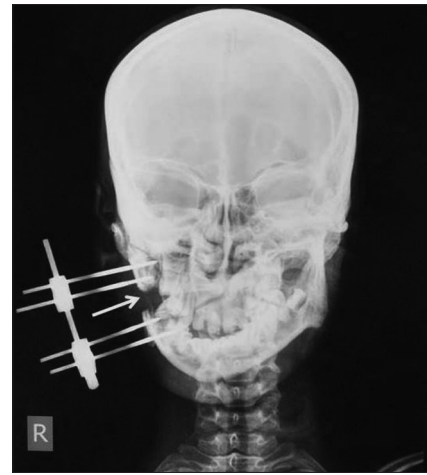
The vector of distraction needs to be carefully planned so as to maximise the beneficial effects of DO in terms of achieving the functional and occlusal goals. This determination of movement of the osteotomised bone segment is planned preoperatively with the help of clinical examination, cephalometry, model analysis and 3D CT. The vector of distraction also needs to be carefully evaluated during the process of distraction to make sure that the distracted bone is moving along predetermined path [Figure 6a and b]. More recently, medical modelling and syntheses offer the benefits of distraction software, which will show the effects of distraction in any desirable vector preoperatively. A model is produced with guides to allow precise pin placement and vector distraction. Vector errors can be greatly minimised in this approach.

### Anterior open bite

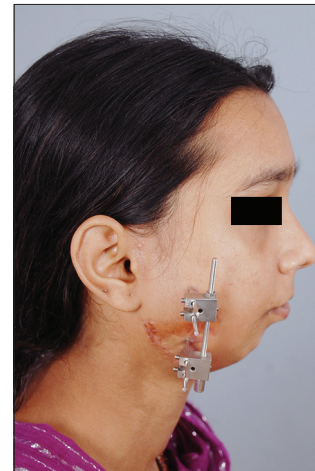Distraction devices for sagittal mandibular advancement if placed parallel to the mandibular plane commonly lead to an anterior open bite [Figure 7]. Numerous studies have determined that for sagittal mandibular distraction, the devices should be oriented depending upon the planned vector of distraction.<sup>[23]</sup>

### Fracture of bone

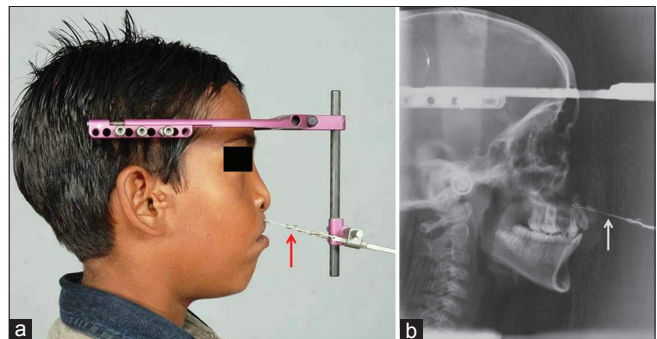
Fracture or splintering of the bone requiring DO is a relatively uncommon but a difficult complication to



**Figure 4:** Posteroanterior skull radiograph of a young female with hemifacial microsomia who had undergone distraction of the mandible. The radiograph shows hypotrophic regenerate with very little mineralisation (indicated by arrow)



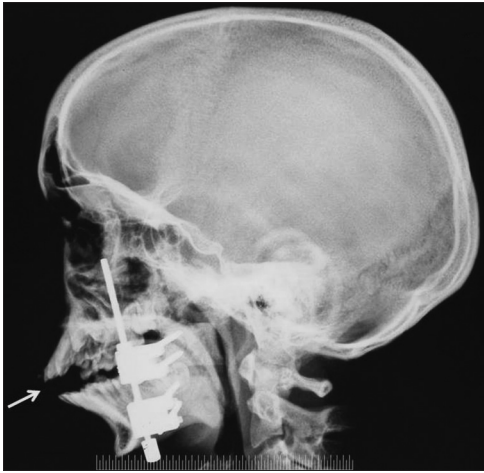
**Figure 5:** Cutaneous scar near the end of the distraction period in a young female with the right side hemifacial microsomia who had underwent application of an external distractor for the lengthening of the mandibular ramus. This scar appeared as a result of pin tract infection



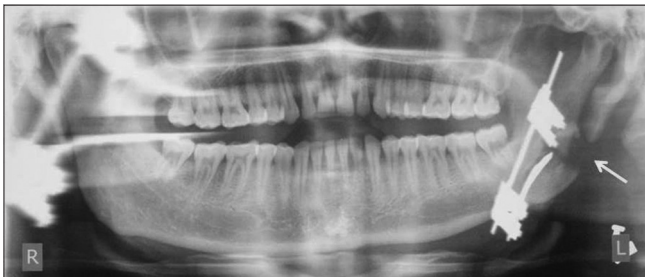**Figure 6:** (a) Young boy with severe maxillary hypoplasia secondary to bilateral cleft lip and palate showing the abnormal downwards vector of pull on the osteotomised maxilla. This was later corrected and the occlusion was restored (indicated by arrow). (b) Lateral cephalogram of the same patient showing the abnormal vector of pull. The maxilla though has been advanced appreciably well in this patient (indicated by arrow)

manage. Many times, the bone is atrophic and becomes difficult to expose fully for surgical access for drilling





**Figure 7:** An anterior open bite has been created during the sagittal mandibular advancement as a result of device placement almost parallel to the posterior border of the mandible in lateral X-ray skull (indicated by arrow)



**Figure 8:** An orthopantomogram showing fracture near the left angle of the mandible occurred during application of the external distractor as a result of excessive traction on the anchoring pins in a patient with left mandibular hypoplasia (indicated by arrow)

the anchoring pins and screws of the distraction device. Fracture of splintering of the bone near the osteotomy may occur due to overzealous drilling, making drill holes too close to the margin of the bone or sometimes it may occur due to unwanted force exerted on the already drilled pins while performing retraction for drilling the other pins on to the bone [Figure 8]. A splintered bone near the osteotomy at the time of application of the device is to be avoided as this thwarts the entire process of distraction. It is best treated by keeping the distraction device in the resting position without performing distraction so that the bone is stabilised by the device and heals itself. Once healing is checked clinically and radiologically a repeat osteotomy is needed and the distraction can then be commenced.

## CONCLUSIONS

DO is a straightforward procedure provided proper evaluation of the patient and execution of the various steps is performed according to the standard guidelines and protocols. The errors and complications arise whenever

prescribed parameters and hardware recommendations are compromised. Majority of the complications can be diagnosed and corrected if recognised early in the course of treatment. The abundant blood supply of the craniofacial region makes these complications less severe than those occurring in the axial skeleton. One must remain open to new devices and techniques, which help in overall reducing the complications associated with DO.

## REFERENCES

1. Snyder CC, Levine GA, Swanson HM, Browne EZ Jr. Mandibular lengthening by gradual distraction. Preliminary report. *Plast Reconstr Surg* 1973;51:506-8.
2. McKibbin B. The biology of fracture healing in long bones. *J Bone Joint Surg Br* 1978;60-B: 150-62.
3. Hulth A. Current concepts of fracture healing. *Clin Orthop Relat Res* 1989;249:265-84.
4. Postacchini F, Gumina S, Perugia D, De Martino C. Early fracture callus in the diaphysis of human long bones. Histologic and ultrastructural study. *Clin Orthop Relat Res* 1995;310:218-28.
5. Kharbanda OP, Darendeliler MA. Ortho-surgical management of skeletal malocclusions. In: Kharbanda OP, editor. *Orthodontics*. 2<sup>nd</sup> ed. India: Elsevier; 2013. p. 645-82.
6. Arnett GW, Bergman RT. Facial keys to orthodontic diagnosis and treatment planning. Part I. *Am J Orthod Dentofacial Orthop* 1993;103:299-312.
7. Genecov D, Agarwal R, Genecov ED, Salyer K. Evolution of extraoral mandibular distraction: Case reports. In: *Craniofacial Distraction Osteogenesis*. Ch. 23. Missouri: Mosby Pub.; 2001. p. 230-5.
8. Agarwal R, Agarwal S, Chandra R. Mandibular reconstruction using extraoral trifocal bone transport: Report of a case using a new device. *J Oral Maxillofac Surg* 2012;70:1739-44.
9. Agarwal R, Agarwal S. External system for stabilization and distraction of curved bony surfaces. *Patentscope*. Publication number WO2011121512, Application number PCT/IB2011/051287, 2011.
10. Shevtsov VI, Cherkashin AM, Sklyar LV, Borodailevich RD. Complication forecast and prophylaxis external fixation treatment, Ilizarov method: Achievements and prospective. Abstract Book of the International Scientific Conference, Kurgan, Russia Kurgan All-Union Scientific Center "Restorative Traumatology and Orthopaedics"; 1993.
11. Cherkashin AM, Samchukov ML. Potential mistakes and complications during distraction osteogenesis. In Samchukov ML, Cope JB, Cherkashin AM, editors. *Craniofacial Distraction Osteogenesis*. Ch. 68. New York: Mosby; 2001. p. 583-94.
12. Marchac D, Arnaud E. Midface surgery from Tessier to distraction. *Childs Nerv Syst* 1999;15:681-94.
13. Ilizarov GA. The tension-stress effect on the genesis and growth of tissues. Part I. The influence of stability of fixation and soft-tissue preservation. *Clin Orthop Relat Res* 1989;238:249-81.
14. Ilizarov GA. The tension-stress effect on the genesis and growth of tissues: Part II. The influence of the rate and frequency of distraction. *Clin Orthop Relat Res* 1989;239:263-85.
15. Stanitski DF, Bullard M, Armstrong P, Stanitski CL. Results of femoral lengthening using the Ilizarov technique. *J Pediatr Orthop* 1995;15:224-31.
16. Chin M, Toth BA. Distraction osteogenesis in maxillofacial surgery

- using internal devices: Review of five cases. *J Oral Maxillofac Surg* 1996;54:45-53.
17. Cope JB, Samchukov ML, Cherkashin AM, Wolford LM, Franco P. Biomechanics of mandibular distractor orientation: An animal model analysis. *J Oral Maxillofac Surg* 1999;57:952-62.
  18. Paley D. Problems, obstacles, and complications of limb lengthening by the Ilizarov technique. *Clin Orthop Relat Res* 1990;50:81-104.
  19. Kewitt GF, Van Sickels JE. Long-term effect of mandibular midline distraction osteogenesis on the status of the temporomandibular joint, teeth, periodontal structures, and neurosensory function. *J Oral Maxillofac Surg* 1999;57:1419-25.
  20. Gardner TN, Evans M, Simpson H, Kenwright J. Force-displacement behaviour of biological tissue during distraction osteogenesis. *Med Eng Phys* 1998;20:708-15.
  21. Harper RP, Bell WH, Hinton RJ, Browne R, Cherkashin AM, Samchukov ML. Reactive changes in the temporomandibular joint after mandibular midline osteodistraction. *Br J Oral Maxillofac Surg* 1997;35:20-5.
  22. Hussain SA. External frame distraction osteogenesis of the midface in the cleft patient. *Indian J Plast Surg* 2009;42 Suppl: S168-73.
  23. McCarthy JG, Stelnicki EJ, Grayson BH. Distraction osteogenesis of the mandible: A ten-year experience. *Semin Orthod* 1999;5:3-8.

**How to cite this article:** Agarwal R. Unfavourable results with distraction in craniofacial skeleton. *Indian J Plast Surg* 2013;46: 194-203.

**Source of Support:** Nil, **Conflict of Interest:** None declared.

### Dispatch and return notification by E-mail

The journal now sends email notification to its members on dispatch of a print issue. The notification is sent to those members who have provided their email address to the association/journal office. The email alerts you about an outdated address and return of issue due to incomplete/incorrect address.

If you wish to receive such email notification, please send your email along with the membership number and full mailing address to the editorial office by email.