

## Review Article

# Head and neck reconstruction

**Prabha Yadav**

Department of Plastic and Reconstructive Surgery, Tata Memorial Hospital, Mumbai, Maharashtra, India

**Address for correspondence:** Dr. Prabha Yadav, Department of Plastic and Reconstructive Surgery, Tata Memorial Hospital, Mumbai, Maharashtra, India. E-mail: drprabhatata@gmail.com

### ABSTRACT

Whatever is excisable, is reconstructable! "You excise, we will reconstruct" are the confident words of reconstructive surgeons today. Reconstruction with multiple flaps has become routine. Radial artery (FRAF), Antero lateral thigh (ALT) and Fibula osteo cutaneous flap (FFOCF) are three most popular free flaps which can reconstruct any defect with excellent aesthetics and performance. Radial Artery provides thin, pliable innervated skin; ALT large amount of skin & bulk; and FFOCF strong 22 to 25 centimetres of bone and reliable skin paddle. Free flap survival has gone to 98% in most of the renowned institutes and is an established escalator in management of defects.

### KEY WORDS

Free flap; head and neck; reconstruction

### INTRODUCTION

Microsurgical reconstruction is providing new and dramatic treatment options for patients affected by cancer, trauma and paralysis. Free flap achieves repair effectively and faster. In the treatment of cancer, adequate surgical excision of tumour is necessary. Compromise with excision, or due to inadequate excision, recurrence of disease will defeat the purpose of surgery. Now days even seemingly inoperable cases can be excised and reconstruction can be attempted thereby improving the quality of life. Today reconstructive surgery has become part of primary cancer treatment. Maximum reconstructions are performed to treat head and neck cancers. In cancers, adjuvant radiation or chemotherapy adds an additional insult

to reconstructed tissue. Reconstruction standing such hazard can be used in traumatic or congenital defects with much comfort.

### MYTHOLOGY AND FUTURE

Gaspar Tagliacozzi, in 1597 described plastic surgeons as those who restore, rebuild and make whole those parts which nature has given but which fortune has taken away.

According to Hindu mythology, Lord Shankar performed first heterogenic transplant of elephant head on baby Ganesha, clone son of Goddess Parvati [Figure 1].

In modern history of medicine, the first successful organ transplant was performed over 50 years ago. With 1984 National Organ Transplant Act, the United Network for Organ Sharing, the Organ Procurement and Transplant Network over 400,000 organs are done in past 20 years. Number of free flaps will be certainly much higher. Tissue allotransplant are being already performed.<sup>[1,2]</sup> Robotic surgery in progress.<sup>[3,4]</sup> Tissue engineered prefabricated flaps will be available across counter very soon.<sup>[5]</sup>

Access this article online	
Quick Response Code: 	Website: <a href="http://www.ijps.org">www.ijps.org</a>
	DOI: 10.4103/0970-0358.118604

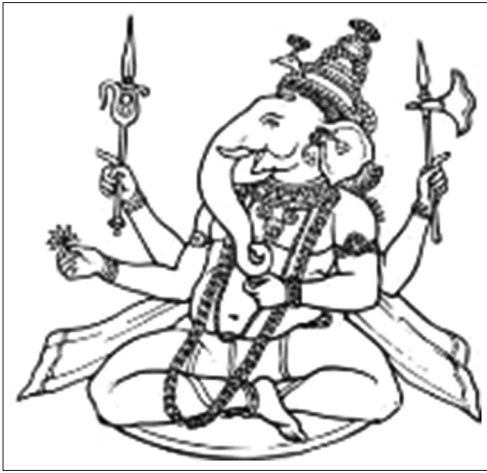

Figure 1: Lord ganesha

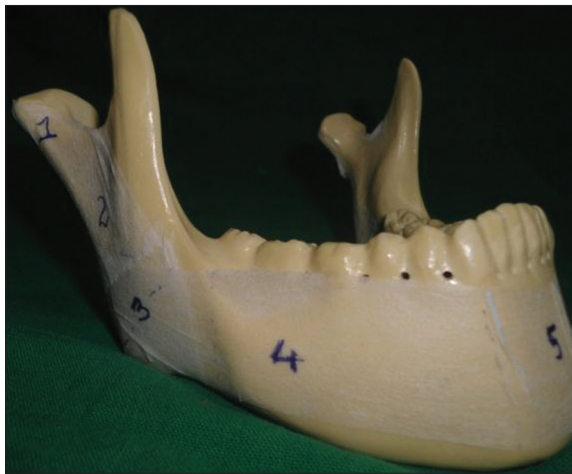

Figure 2: Mandible with segments marked

## APPLIED ANATOMY OF HEAD AND NECK

Head and neck with vital organs brain and eyes; major blood vessels, air and food passage has unique importance. Face is most exposed part of the body. The facial skin provides insertion to the muscle of facial expression and is therefore very important in day to day communication. Dull expressionless face or stary look may create fear. Face gives identity and social acceptance to individual. Acceptance or rejection of person is decided on face presentation. Tongue, the bulky boneless muscle which occupies most of the oral cavity, assists swallowing, mastication and speech; all these needs due to consideration while planning reconstruction.

## PATHOLOGY AND DISEASES OF HEAD AND NECK

Oral cavity cancers are common in India. Chewing bitter nut, tobacco and pan initiates disease at a young age of 10-12 years. Patient may present with pain and difficulty

in the opening of mouth, swelling or discharging sinus; revelling chronic ulcer or established squamous cell carcinoma infiltrating adjoining bone. Radical excision, chemo and radiation therapy promises almost complete cure and full life span. The treatment of many cancer patients extends beyond a single surgery and is often a lifelong process, with secondary surgery for rehabilitation and recurrence. Reconstruction performed at the first stage plays the main role in the long-term outcome. Free tissue transfer is often the first choice for reconstruction.

## ASSESSMENT OF WOUND, DEFECT AND DEFORMITY

In simple defect approximation of identical tissue with anatomical continuation solves problem. In composite defect, growth or repair of various tissue at a different speed makes wound healing difficult. Regeneration stress of tissue, possibilities of adhesions and infection are minimised by providing appropriate viable tissue in adequate amount.

Wound over natural stoma of mouth, however small it may be needs special attention. Adequate mouth opening is desired for feeding, swallowing and oral hygiene. It is easy to prevent microstoma at the time of primary repair. Correction of microstoma may need extensive surgical procedure like free flap if not addressed initially.

Restoration of integrity and function is the minimal goal in all patients who are not critically ill. Similarly form, or aesthetics, must be considered whenever possible. Having decided the aims of reconstruction, it is necessary to analyse the components of the defect. The defect may involve skin, soft-tissue, or bone, alone or in combination. It may also require two or more separate skin paddles, for example, in reconstruction of an intraoral mucosal and extraoral skin defect. The tissue components and volume of tissue required would dictate the choice of reconstruction. Analysis of wound, exact site, loss of skin and mucosa (size), soft-tissue bulk, lip defect, tongue, palate, bone length and segment lost, condition of orbital floor, neck dissection, available residual tissue and recipient blood vessels play an important part in selecting reconstruction procedure. Understanding patients need, analysis of defect and selection of proper free flap are key factors in the head and neck reconstructions. Complications like failure of procedure, exposure of hardware, mal occlusion, non-union, enophthalmos, dystopia, ectropion, asymmetry of face, fistulae, stricture or mal occlusion are absolutely avoidable.

Majority of wounds could be reconstructed with Free Fibula Osteo Cutaneous Flap (FFOCF), anterolateral thigh (ALT) flap and radial artery free flap [Table 1].

## MANDIBLE RECONSTRUCTION

### Surgical anatomy of mandible

Mandible consists of horseshoe shape body and a pair of rami. Body of mandible meets ramus on each side at an angle of mandible. Mean mandible angle at canine premolar region where mandible turns towards midline is 120° in Indians, Chinese, Africans and Peruvians. In Europeans it is 128°, where as in Netherland 110°.<sup>[6]</sup>

For the reconstruction of mandible, defect analysis data of bone loss [Figure 2] is collected as in [Table 2].

For good functional recovery, all defects where native mandible is present on both sides, should be reconstructed with bone. Posterior segment mandibulectomy may be reconstructed by soft tissue flap pectoralis major

myocutaneous (PMMC) or ALT. Reconstruction of mandible with vascularised free fibula graft is considered as the gold standard.<sup>[7]</sup> Reconstruction with plate and soft-tissue flap is considered in very high morbidity and poor prognosis.<sup>[8]</sup> High post-operative complications, fracture of plate or extrusion of the plate may require secondary surgeries.<sup>[9]</sup>

While assessing defect, always neutralize head position. Measure bone segments on either side left behind after excision of the tumour. Assess mucosal and skin defect. Do temporary inter maxillary fixation (IMF). Decide which neck vessels are to be used as recipient vessels.

If reconstruction of the outer skin is required (in addition to mucosal cover), it is ideal to have skin with separate perforator. Locate perforators for the inner lining and outer skin. Divide skin based on perforator to rotate out. Sometimes it is not possible to divide skin on perforator, in such situation de-epithelise and rotate out skin. In a difficult situation cover outer defect with 2<sup>nd</sup> flap.

**Table 1: Free flaps used for head and neck reconstruction (2008-2013) TMH India Mumbai**

Site	FFOC	ALT	FRAF	JEJ	PMMC	LD	VRAM	T
1	481	29			260			770
2	25	84	03					112
3		62	89					151
4		66	141					207
5		3	9	31	43			86
6		9	12					21
7			14					14
8		6						6
9			4					4
10		10				2		12
11							2	2
T	506	269	272	31	303	2	2	1385

1: Mandible, 2: Maxilla, 3: Tongue, 4: Buccal mucosa, 5: Pharynx, 6: Lip, 7: Orbit, 8: Parotid, 9: Cheek nose, 10: Scalp, 11: Skull base, T: Total, FFOCF: Free fibula osteo cutaneous flap, FRAF: Free radial artery forearm flap, LD: Latissimus dorsi, JEJ: Jejunum, VRAM: Vertical retus abdominus muscle, ALT: Anterolateral thigh, PMMC: Pectoralis major myocutaneous

**Table 2: Mandibular defects**

Segment involved	Defect description mandibulectomy	Defect in cm
1-3	Right post segmental	6
1-5	Right hemimandible	13
1-6	Right extended hemimandible	16
3-5	Right lateral body	7
3-7	Angle to angle	17
4-6	Middle third	9
4-9	left extended hemimandible	16
5-7	Left lateral body	7
5-9	Left hemimandible	13
7-9	Left post segmental	6

## FREE FIBULA OSTEOTOMY PLANNING AND FLAP INSET

To fabricate mandible from fibula, mark all perforators. Plan osteotomy from distal to the proximal end taking care of perforator. Use K wire template. Mark closing wedge osteotomy of 60°. Base of the wedge is on the side that needs to bend. Take lateral peroneal surface as fixation surface. Mark on bone graft as per defect and osteotomy requirements. To avoid devascularisation, do not make any graft segment smaller than 2 cm. Do not strip off periostium even for screw fixation. Adjust bone graft to mandible by checking its position with upper incisors for midline and see to that it does not become prognathic or retrognathic. Have exact bone cuts to match with mandible cuts. Do mini plate fixation with 2.5 mm screws. Reconstruction plate is not used to prevent damage of overlying skin by radiation therapy. Undo IMF and check for dental occlusion. It should be normal if not then undo fixation and readjust. It is very difficult to correct it post radiotherapy. Inset inner skin paddle partially and then perform vascular anastomosis after checking length and lie of vessels. Avoid kinking or undue tension. Achieve the haemostasis. Haematomas may compress vessels. Position drains. Prevent movement of drain and compression of vessels by drain. Give final inset.

## MAXILLA

Maxilla and its sinus is six dimensional hollow structure. It is in close relationship with orbit, nose, paranasal sinus, nasopharynx, skull base, infratemporal fossa and oral cavity. It provides skeletal support to face, orbit and nose. Alveolar process of maxilla support upper dentition. Loss of this mid face bone causes obvious aesthetic disruption. Tumours arising from paranasal sinus and maxillary alveolus need maxillectomy. Direct invasion of these tumours in surrounding tissue through natural path or direct invasion makes defect small or devastating on their excision.

Reconstruction is required to support facial skin, seal base of skull, fill up dead space, maintain orbit support, prevent oro-nasal communication and provide support for dental rehabilitation. Maxillary defect must be assessed properly in horizontal and vertical dimensions. Reconstructive options available are from prosthesis to free tissue transfer.<sup>[10]</sup> Isolated palatal defect can be managed with obturator, local flap or free tissue flap like free radial forearm flap (FRAF) depending on defect size. In low maxillectomy defects where orbital floor is intact if horizontal extent is less than half of alveolar arch, prosthesis with sound spectrograms will be adequate. But, when the defect is hemi or more, or total palatotomy, then reconstruction with bone flap is desired [Figure 3]. Large volume maxillectomy defect with or without orbital exenteration needs bulky flap to fill up dead space. In addition, external skin cover may be required.

ALT could be an answer in such a situation [Figure 4]. To prevent sagging of such heavy flap and contour deformity, flap needs to be anchored to zygoma for support after drilling a hole in it.

However, in intermediate size defect with better survival, quality of life is a priority issue, osteocutaneous free flap

is indicated. With FFOC flap mid facial height, width, projection and rehabilitation with osteo integrated dental implant could be achieved.<sup>[11]</sup>

Additional second free flap to provide bulk may be required in few cases.

Other bone flaps available are; iliac crest based on deep circumflex iliac artery which can provide good support for orbit and facial skin.<sup>[12]</sup> But it may need vein graft because of its short pedicle length and it has high donor area morbidity. Another flap is scapular osteocutaneous flap.<sup>[13]</sup> It has enough skin, bulk and pedicle length. Change of position prolongs surgery.<sup>[14]</sup>

When floor of orbit is intact and it is low maxillectomy defect, FFOC flap could be the best choice. Defects including palate, cheek, orbit and external nose are difficult to reconstruct. A combination of free flap and prosthesis may be the better answer.<sup>[15]</sup> Multiple free flaps may help.

Orbital floor reconstruction is a challenge. Enophthalmous, dystopia, diplopia and ectropion may develop and must be avoided by providing good orbital support. This support can be either with vascularized or random bone graft or tensor fascia lata or titanium mesh or other prosthetic material; which is covered with free

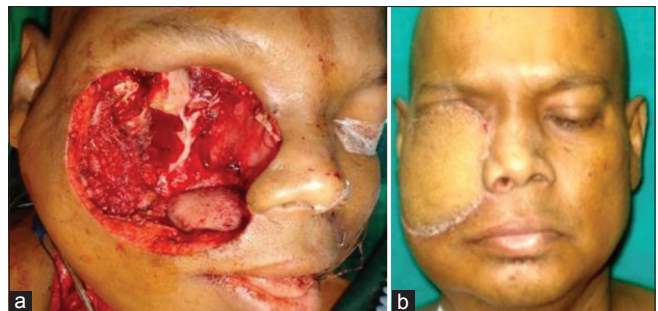


Figure 4: (a) Maxillectomy plus orbital exenteration with skin defect. (b) Reconstructive with ALT flap

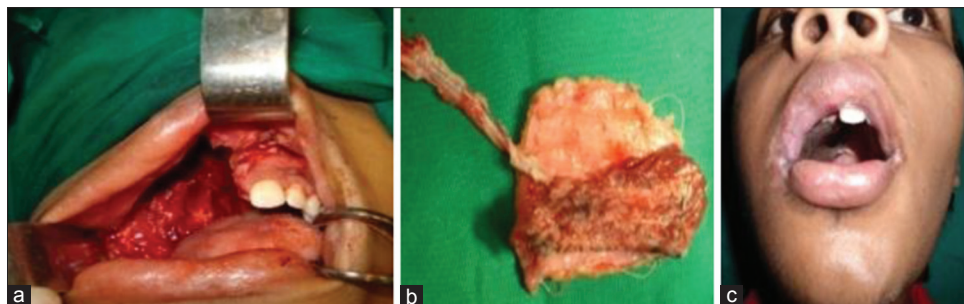


Figure 3: (a) Hemipalatal maxillary defect. (b) Free fibular flap. (c) Post operative

flap.<sup>[16]</sup> Post radiotherapy if bone graft gets exposed it can be managed by just nibbling it. But to remove a mesh is very difficult and hence should be used with caution.

In certain cases, it needs supra structure maxillectomy where palate stays intact. The defect is above that with orbital exenteration exposing skull base. Outer skin may be involved requiring excision. Defect needs bulky flap as filler and to seal off skull base. It is best reconstructed with ALT or rectus abdominis myocutaneous flap. Extensive complicated defects could be addressed with facial allotransplantation.

Due to the complexity and variation, no definite algorithm has been suggested by any reconstructive surgeon so far. Reconstruction is planned on an individual basis and preferences.

## PHARYNX RECONSTRUCTION

Pharynx is tubular fibromuscular passage connecting oral cavity to cervical oesophagus extends from the inferior border of tonsil to the inferior border of cricoid cartilage. Larynx projects anteriorly into pharynx protecting air passage and helps nasal breathing and speech. Pyriform sinuses are created on either side of the larynx. Anatomically and functionally larynx and pharynx are intimately related. Diseases of the larynx and pharynx are of different aetiology. But both organs are affected with disease of any one of them.

Larynx is the most developed organ. Preservation of the larynx is desired and is possible in early disease or small lesion. Though surgery remains the main modality of treatment 'radiation therapy' is often recommended for larynx preservation. Defect produced by surgery varies causing impairment in swallowing, loss of speech and loss of nasal breathing. One may require permanent tracheostomy. Reconstruction aims to provide leak proof food passage and speech normalcy. Small defects can be closed primarily. In moderate size defect, where remaining unstretched mucosa is at least 3 cm in width uniformly, primary closure may provide adequate food passage. If remaining mucosa is less than 3 cm in width primary closure would be under tension and chances of wound dehiscence are high. It may lead to fistula and adds risk of neck vessel blowout. It may develop stricture subsequently. Such defects need augmentation with flap, either by pedicle or free flap. Patch pectoralis major myocutaneous (PMMC) flap is reliable with good vascularity,

has an easy reach and simple to harvest. In addition, muscle covers and protects major neck vessels. Pedicle PMMC flap is ideal for such defect.<sup>[17,18]</sup> But in situations like very bulky or fat patients and female patients it is not a good option. Suturing thin pharyngeal mucosa to thick fatty skin is difficult. Similarly, in patients with intact larynx patch PMMC should not be done. Its bulk causes intractable aspirations. In composite defects, skin grafts are applied on pectoralis major muscle for neck skin defect or free flap is used for the entire defect.

In cases where PMMC is not ideal they are reconstructed with free flap like FRAF or ALT flap. When remaining mucosa is less than 3 cm and is irregular then it is better to remove it and treat it as circumferential defect.

## PLANNING OF PATCH PMMC

Circumference of the pharynx, at the upper end near the base of the tongue is about 12 cm. It gradually reduces to 9 cm at cricoid level and continues as oesophagus. This passage is about 10 cm in length. On an average for circumferential defect, desired tube can be made by skin measuring 12 cm × 10 cm × 9 cm. In case of partial defect, it will be the 12-minus width of available mucosa × 10 × 9-minus width of available mucosa.

Flap is flipped up. Flap is planned in reverse and then marked. Lower end of flap goes to tongue end of defect. To avoid circular suture line at oesophageal end small skin extension of about 1.5 cm is marked at the opposite margin of flap, i.e., upper end of marked flap. This avoids stricture formation at a later date. Flap is raised in standard fashion. Suturing is done with knots facing inside the lumen. While suturing skin with mucosa do not try to take bite up to muscle as it may crush fat while tying the knot and lead to flap necrosis resulting in leak/fistula. Cover this suture line with pectoralis muscle by anchoring it with few sutures. Tuck the same, medial to the opposite side neck vessels. This protects vessels if any leak develops. Place drain away from pharyngeal suture line.

## Circumferential defect

Lower extent of the defect is a key factor in deciding method of reconstruction. If defect extends below thoracic inlet, then gastric pull up is done. When lower extent is above thoracic inlet, then it is reconstructed with mucosal lined tube or skin lined tube.

Mucosa lined tubes are jejunal loop or gastro omental flap. Skin lined tubes are from FRAF or ALT flap.<sup>[19]</sup>

### Jejunal loop

It is ready made tube with similar physiology with secretions in particular. Mucosa to mucosa healing is always better. Leak rates are less. Functional rehabilitation is faster.<sup>[20]</sup> Only constrain is jejunums tolerance to ischemia is short. Ischemia over 2 hours is intolerable.

Jejunal loop 30-50 cm distal to ligament of Treitz should be harvested. Required length and its supplying vessel, a branch of superior mesenteric artery are identified. Proximal end marked for isoperistaltic anastomosis. Jejunal loop is isolated on its pedicle and then divided between clamps and kept ready, but vessels are not divided to reduce ischemia time. Neck vessels are identified and prepared for anastomosis and then only jejunum vessels are clamped and divided. Take few sutures at the upper end to stabilise the jejunum. Do vascular anastomosis. Thereafter do proper inset of flap. This is to reduce ischemia time. Cut open jejunum at its anti-mesenteric border at the upper end to enlarge width of the tube. Do upper inset of flap. Judge the length required because the moment arterial anastomosis is over and clamp is opened jejunal loop increases in length. The distal small remaining segment is brought out through neck suture line based on vasa recti vessels for post op monitoring. Monitoring is not done with interest to salvage flap, but if outer loop is found not viable, the jejunal flap is immediately discarded to prevent subsequent infection so that alternative reconstruction could be done. It is very difficult to salvage jejunum due to its short ischemia time. In normal recovery, monitoring loop is divided after 8-10 days.

Gastro-omental tubes are indicated in chemo and radiation compromised wounds. Omentum provides protection for neck vessels.

### Skin lined tubes

PMMC flap is occasionally used for circumferential defect in very high risk patients or patients with poor prognosis. Bulk of flap makes it difficult to tube. Risk of the suture line dehiscence and leak are high.

### Free skin flaps

Both FRAF and ALT flap can be used with good results. For monitoring small patch of flap skin is brought out in the neck suture line. Mucosa to skin healing is slower. Leaks are higher with skin lined tubes. Additional suturing

of fascia or soft-tissue over suture line for tubing can avoid leakage. Whenever there is a leak it is managed conservatively. If it does not reduce in few days but in fact increases, then it needs surgical intervention.<sup>[21]</sup>

Speech rehabilitation is reported to be better with skin lined tubes than jejunal flap. Speech quality is wet or gurgly when reconstruction is done with jejunum. Speech rehabilitation is done by tracheo esophageal puncture (TEP) and use of Bloom singer valve prosthesis or provog prosthesis. Patient needs to learn with the help of a speech therapist. Speech with electro larynx has mechanical or robotic quality.

Complication like stricture is managed by dilation on out-patient department basis. Over all for circumferential defects jujunum is preferred as it has less complications and faster rehabilitation.

### Oral cavity

Oral cavity is relatively small cavity extending from lips to tonsillar pillar. Upper and lower alveolus; palate, floor of mouth, anterior part of tongue and vermilion, buccal mucosa, palate are various constituents. To facilitate chewing, eating, swallowing and speech entire cavity is lined by special secreting mucosa. Grinding food, forming bolus, holding saliva or articulating speech, all needs coordinated effort of tongue, cheeks, and lips. Each sub site has different functional requirement.

### Tongue

Tongue is the largest muscle organ in the mouth. Anterior two-third of the tongue is slim and mobile.

Posterior third is bulky and heavy.

For anterior two-third tongue defects up to 30% defect can be sutured primarily, without compromising any function. Larger defects up to almost 80% needs reconstruction by flap. In general free flaps are preferred as they can be thin pliable and do not have tethering effect like pedicle flap.<sup>[22]</sup> FRAF is the most used flap for such defects [Figure 5]. It is thin pliable with sizable pedicle length. It can be made sensate. It does not have any donor area morbidity. Simultaneous harvest reduces over all operative time.

Total glossectomy defects need bulky flap to obliterate dead space and mound to occlude against palate for speech and swallowing. ALT<sup>[23]</sup> or rectus abdominis myocutaneous flap<sup>[24]</sup> is preferred.

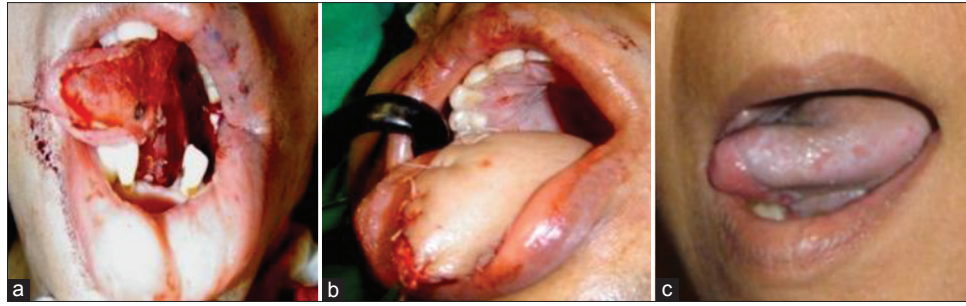

Figure 5: (a) Hemiglossectomy defect. (b) FRAFL sutured. (c) Long term follow up

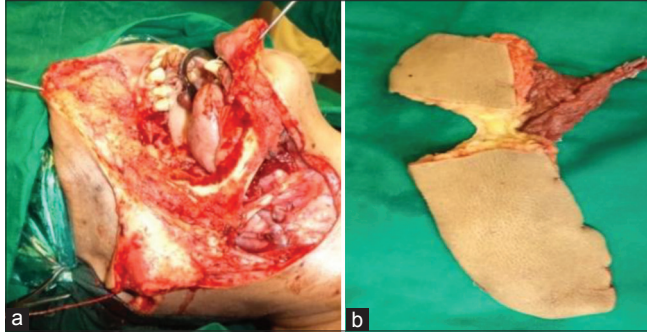


Figure 6: (a) Composite buccal mucosa defect extending laterally. (b) Divided ALT flap to be used

**Floor of mouth**

To prevent salivary leakage or fistula formation, integrity and alignment of tissue must be maintained, overlapping or gaps of tissue must be avoided. Sutures must be placed adequately and firmly.

**Buccal mucosa**

Most of The buccal mucosa defects can be reconstructed with FRAFL. But, when buccal mucosa defect extends laterally and soft tissue loss is more. Bulkier ALT flap is desired [Figure 6].

**CONCLUSION**

Cancer patients are most benefited with primary reconstruction. Success rate of 95-98% in free flap reconstruction is achieved at number of institutes. It is possible to reconstruct most of defects in the head and neck region by using FFOC, radial artery forearm flap or ALT free flap [Table 3].

Once these 3 flaps are mastered, other flaps also can be performed with ease.

Requirement to conduct free flap surgery are not very high. Assessment of wound defect, selection of appropriate flap and prosthesis are easy to understand.

Table 3: Free Flaps

Flap	Skin (cm)	Bone (cm)	Muscle	Fascia/sub cut	Pedicle (cm)
FFOC	12x25	22-25	FHL soleus	Leg fascia	7-10
Radial artery forearm flap	12x25	Thin sliver 10-12	Nil	Thin sub cut	8-10
ALT	25x30	Nil	Vas lat	Deep fascia of thigh	8-10

FFOC: Free fibula osteo cutaneous flap, FHL: Flexor hallucis longus, ALT: Anterolateral thigh flap

Good team to monitor flap, surgical operating loops for vascular anastomosis should give courage to skilled hands at secondary care establishment.

Stem cell engineering, tissue transplant from cadaveric donors and laboratory synthesis of tissue are in rapid progress and will be practiced at secondary care establishments.

**REFERENCES**

- Haughey BH, Beggs JC, Bong J, Genden EM, Buckner A. Microvascular anastomosis of the canine tongue. *Laryngoscope* 1999;109:1461-70.
- Gastman B, Djohan R, Siemionow M. Extending the Cordeiro maxillofacial defect classification system for use in the era of vascularized composite transplantation. *Plast Reconstr Surg* 2012;130:419-22.
- O'Malley BW Jr, Weinstein GS, Snyder W, Hockstein NG. Transoral robotic surgery (TORS) for base of tongue neoplasms. *Laryngoscope* 2006;116:1465-72.
- Leonhardt FD, Quon H, Abrahão M, O'Malley BW Jr, Weinstein GS. Transoral robotic surgery for oropharyngeal carcinoma and its impact on patient-reported quality of life and function. *Head Neck* 2012;34:146-54.
- Fennis JP, Stoelinga PJ, Merckx MA, Jansen JA. Reconstruction of the mandible with a poly D (L-lactide) scaffold, autogenous corticocancellous bone graft, and autogenous platelet-rich plasma: An animal experiment. *Tissue Eng* 2005;11:1045-53.
- Rai R, Ranade AV, Prabhu LV, Pai MM, Madhyastha S, Kumaran M. A pilot study of the mandibular angle and ramus in Indian population. *Int J Morphol* 2007;25:353-6.
- Delacure M. Reconstruction of mandible. *Indian J Plast Surg* 2007;40:28-34.
- Chepeha DB, Teknos TN, Fung K, Shargorodsky J, Sacco AG,

- Nussenbaum B, *et al.* Lateral oromandibular defect: When is it appropriate to use a bridging reconstruction plate combined with a soft tissue revascularized flap? *Head Neck* 2008;30:709-17.
9. Wei FC, Celik N, Yang WG, Chen IH, Chang YM, Chen HC. Complications after reconstruction by plate and soft-tissue free flap in composite mandibular defects and secondary salvage reconstruction with osteocutaneous flap. *Plast Reconstr Surg* 2003;112:37-42.
  10. Robb GL, Marunick MT, Martin JW, Zlotolow IM. Midface reconstruction: Surgical reconstruction versus prosthesis *Head Neck* 2001;23:48-58.
  11. Kim DD, Dreher MA. The fibula free flap in maxillary reconstruction. *Atlas Oral Maxillofac Surg Clin North Am* 2007;15:13-22.
  12. Brown JS. Maxillary reconstruction. *Indian J Plast Surg* 2007;40:35-43.
  13. Urken ML, Bridger AG, Zur KB, Genden EM. The scapular osteofasciocutaneous flap: A 12-year experience. *Arch Otolaryngol Head Neck Surg* 2001;127:862-9.
  14. Clark JR, Vesely M, Gilbert R. Scapular angle osteomyogenous flap in postmaxillectomy reconstruction: Defect, reconstruction, shoulder function, and harvest technique. *Head Neck* 2008;30:10-20.
  15. Cordeiro PG, Chen CM. A 15-year review of midface reconstruction after total and subtotal maxillectomy: Part I. Algorithm and outcomes. *Plast Reconstr Surg* 2012;129:124-36.
  16. Cordeiro PG, Chen CM. A 15-year review of midface reconstruction after total and subtotal maxillectomy: Part II. Technical modifications to maximize aesthetic and functional outcomes. *Plast Reconstr Surg* 2012;129:139-47.
  17. Patel D, Kuriakose MA, Iyer S. Reconstruction of laryngopharynx. *Indian J Plast Surg* 2007;40:35-43.
  18. Spriano G, Pellini R, Roselli R. Pectoralis major myocutaneous flap for hypopharyngeal reconstruction. *Plast Reconstr Surg* 2002;110:1408-13.
  19. Gilbert RW, Neligan PC. Microsurgical laryngotracheal reconstruction. *Clin Plast Surg* 2005;32:293-301.
  20. Vos JD, Burkey BB. Functional outcomes after free flap reconstruction of the upper aerodigestive tract. *Curr Opin Otolaryngol Head Neck Surg* 2004;12:305-10.
  21. Murray DJ, Novak CB, Neligan PC. Fasciocutaneous free flaps in pharyngolaryngo-oesophageal reconstruction: A critical review of the literature. *J Plast Reconstr Aesthet Surg* 2008;61:1148-56.
  22. de Vicente JC, de Villalain L, Torre A, Peña I. Microvascular free tissue transfer for tongue reconstruction after hemiglossectomy: A functional assessment of radial forearm versus anterolateral thigh flap. *J Oral Maxillofac Surg* 2008;66:2270-5.
  23. Yu P. Reinnervated anterolateral thigh flap for tongue reconstruction. *Head Neck* 2004;26:1038-44.
  24. Lyos AT, Evans GR, Perez D, Schusterman MA. Tongue reconstruction: Outcomes with the rectus abdominis flap. *Plast Reconstr Surg* 1999;103:442-7.

**How to cite this article:** Yadav P. Head and neck reconstruction. *Indian J Plast Surg* 2013;46:275-82.

**Source of Support:** Nil, **Conflict of Interest:** None declared.

#### Announcement

#### Android App



Download  
**Android**  
application

FREE

A free application to browse and search the journal's content is now available for Android based mobiles and devices. The application provides "Table of Contents" of the latest issues, which are stored on the device for future offline browsing. Internet connection is required to access the back issues and search facility. The application is compatible with all the versions of Android. The application can be downloaded from <https://market.android.com/details?id=comm.app.medknow>. For suggestions and comments do write back to us.