

## Case Report

# Successful combined approach to a severe Fournier's gangrene

Tommaso Agostini, Francesco Mori, Raffaella Perello, Mario Dini, Giulia Lo Russo

Department of Plastic and Reconstructive Surgery, University of Florence, Largo Palagi 1, 50134 Florence, Italy

**Address for correspondence:** Prof. Tommaso Agostini, Department of Plastic and Reconstructive Surgery, CTO-AOUC, Faculty of Medicine and Surgery, University of Florence, Largo Palagi 1, 50100 Florence, Italy. E-mail: <mailto:tommasoagostini@gmail.com>

### ABSTRACT

We present a case of a successful reconstruction of a severe Fournier's gangrene (FG) involving the scrotum, the perineum, the right ischial area and extended to the lower abdomen. There are many different surgical techniques to repair and reconstruct the defect following debridement in FG. The authors treated this complex wound using negative pressure wound therapy (NPWT), dermal regeneration template and a split-thickness skin graft. Complete recovery was achieved and no major complications were observed. The patient showed a satisfying functional and aesthetic result.

### KEY WORDS

Dermal regenerative template; Fournier's gangrene; vacuum-assisted closure therapy

### INTRODUCTION

Fournier's gangrene (FG) is an infective necrotizing fasciitis involving the skin and soft-tissues of the genitalia and perineum, which may extend to the abdomen, lower limbs and chest. It is a rare but potentially fatal condition and must be promptly recognized and appropriately treated. In 1883 Jean Alfred Fournier (1832-1914), a Parisian Venereologist, described the syndrome that would later bear his name, a case of fulminant gangrene involving the genital area in an otherwise healthy young man.<sup>[1]</sup>

The disease can affect people of all ages, the mean age appears to range from 40 to 50 years, with a strong male predominance.<sup>[2-4]</sup> Originally FG was considered

an idiopathic disease but today is often possible to identify the sources of the infections, that frequently arise from cutaneous trauma or urogenital and colorectal diseases.<sup>[2-6]</sup> Many species of bacteria, including aerobic and anaerobic, are isolated from the wounds, most frequently in combination rather than single. These organisms, usually commensal of the digestive and urogenital tract, become pathogenic and act synergistically to cause extensive tissue damage.<sup>[2-8]</sup> Systemic disorders that compromise the immune system have been implicated in the development of FG. Diabetes mellitus, alcoholism, obesity, malignancy and immunosuppression are the most common comorbidities associated with the disease. FG frequently results from a polymicrobial infection in a susceptible immunocompromised host.<sup>[2-6]</sup>

FG commonly presents with sudden onset of intense pain in the genitalia, perineum or perianal region, often accompanied by swelling, tenderness, erythema, vesicles and frank necrotic skin lesions in the advanced cases. Crepitus between the skin and the fascia may be present, suggesting a gas-forming infection. Systemic signs can range from fever to septic shock and multiple organ failure.<sup>[2-4]</sup> FG is

#### Access this article online

Quick Response Code:



Website:

[www.ijps.org](http://www.ijps.org)

DOI:

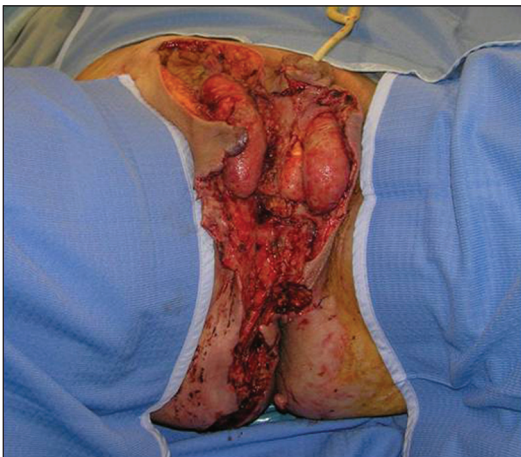
10.4103/0970-0358.129648

a life-threatening emergency and the mortality rate ranges from 3% to 45% respectively.<sup>[4]</sup> Treatment should be started as soon as possible; hemodynamic stabilization, parenteral administration of broad-spectrum antibiotics and extensive debridement of all necrotic tissue are the mainstay of therapy.<sup>[2-8]</sup> Adequate debridement may leave a large skin and soft tissue defect that pose significant reconstructive challenges. We report a case of a successful reconstruction of a severe FG using negative-pressure wound therapy, dermal regeneration template and split-thickness skin grafting.

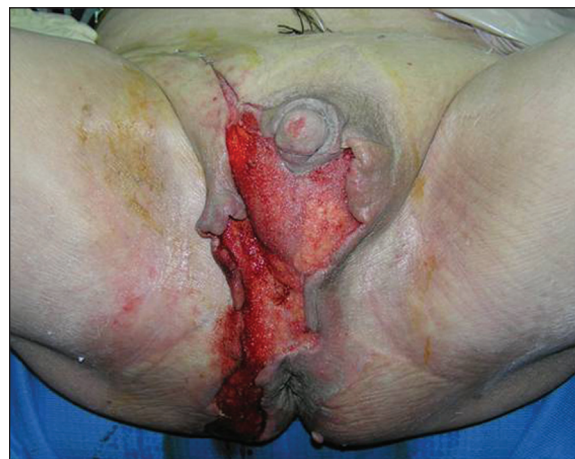### CASE REPORT

The present case report is about a 64-year-old Caucasian man was transferred to our hospital with the diagnosis of FG complicated by septic shock. His past medical history was significant for hypertension, mild chronic renal insufficiency and diabetes mellitus type 2 controlled with oral hypoglycaemic agents. He was admitted to the intensive care unit due to progressive respiratory deterioration and hemodynamic instability. On examination, the patient presented with a FG involving the scrotum, the perineum, the right ischial area and extended to the lower abdomen. A multidisciplinary approach involving intensivists, endocrinologist, urologist and reconstructive surgeon was adopted to address his problems. After hemodynamic stabilization and administration of broad-spectrum antibiotic therapy, the first surgical debridement and a temporary diverting colostomy were performed. After 2 days a second radical debridement was done and a suprapubic cystostomy was established [Figure 1]. After the second debridement negative pressure wound

therapy (NPWT) was applied to facilitate wound healing by removing exudates constantly, centripetally contracting the wound and assist in nursing.<sup>[5,7]</sup> Two large polyurethane foams were cut into several pieces and stapled into the wound, making certain not to staple the urethra or testicles. NPWT was applied with a continuous negative pressure of 125 mmHg. After surgical debridement, the patient received daily hyperbaric oxygen therapy (HBOT) at 2.4 atmospheres absolute for 90 min, until the wound showed healthy granulation tissue. The empiric antibiotic treatment was tailored according to blood and wound culture findings. Blood culture results were positive for methicillin-resistant *Staphylococcus epidermidis*. Wound cultures taken during the operation grew *Proteus mirabilis* and *Enterococcus faecalis*. During NPWT there were no signs of deep wound infection. NPWT dressing was changed and reapplied twice a week, until the presence of healthy granulation tissue with no sign of infection was observed [Figure 2]. After 21 days of NPWT the patient was ready for the next stage of reconstruction. Skin and soft-tissue defects of the lower abdomen were managed with primary delayed closure. The anterior part of the scrotum was covered with scrotal advancement flaps. The Integra dermal regeneration template was used to temporarily cover the full-thickness skin defects of the perineum, the right ischial region and the posterior part of the scrotum [Figure 3]. The NPWT was re-applied over dermal regenerative template as a bolster dressing to ensure complete contact with the wound bed. NPWT dressing was changed and dermal regenerative template was inspected twice a week. No complications related to dermal regenerative template engraftment were observed. After 3 weeks the outer silicone layer was removed and the neodermis was covered with a split-thickness skin graft



**Figure 1:** Intraoperative view of the tumour. Patient after the second surgical debridement procedure. The defect involves the scrotum, the perineum, the right ischial region and extended to the lower abdomen



**Figure 2:** Post-operative 21 days later surgery. The healthy granulation tissue throughout wound

harvested from the right inner thigh. NPWT was placed on the graft as a bolster dressing and it was removed after 5 days. Complete healing occurred and the patient was discharged from the hospital after 58 days. No major complications were observed. At 3 months follow-up, the patient had fully recovered and showed a satisfying functional and aesthetic result [Figure 4].

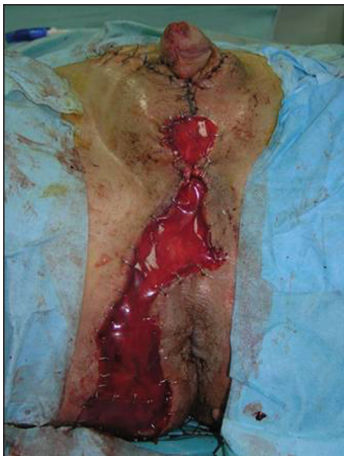## DISCUSSION

FG is a rapidly progressive and potentially fatal necrotising fasciitis of the perineum and genitalia. Early recognition of the disease, haemodynamic stabilisation of the patient, administration of broad-spectrum antibiotics, timely and extensive surgical debridement of all necrotic tissue improve the overall survival rate.<sup>[2-8]</sup> The most common source of infection are urogenital foci, extension of anorectal infection and local trauma. This infective process rapidly spreads along Colles' fascia, Dartos fascia and may involve the abdominal wall through the Scarpa's fascia.<sup>[2,6]</sup> Common causative organisms associated with FG are *Enterobacteria*, particularly *Escherichia coli*, streptococcal species, staphylococcal species and *Clostridia*, frequently in combination rather than single.<sup>[2-8]</sup> This polymicrobial infection leads to vascular thrombosis of the subcutaneous tissue and subsequent gangrene of the overlying skin.<sup>[2]</sup> Comorbidities that compromise the immune system have been implicated in the development of FG and diabetes mellitus is the most common predisposing factor due to the defective phagocytosis, increase incidence of urinary infection and microangiopathy.<sup>[2-6]</sup>

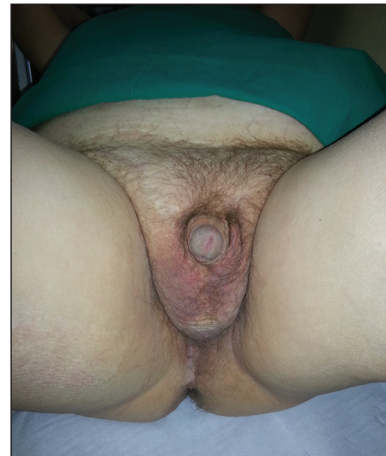Establishing a diagnosis of FG can be challenging in the early stages, when the patient may present only minimal

cutaneous manifestation of the underlying infection. Fever, intense pain, erythema and tenderness of the genitalia and perineum are the most common clinical presenting features.<sup>[2-4]</sup> Patients may present with systemic symptoms of sepsis: Shock and altered mental status are common.<sup>[2]</sup> Appropriate support for organ dysfunction, broad-spectrum antibiotic therapy and wide excision of devitalised tissue, with one or more debridements, are the mainstays in the treatment of this condition.<sup>[2-8]</sup> The goal of extensive debridement is the removal of all necrotic tissue, exudate and infectious material from the wound bed until normal and well-vascularised tissue remains. Orchidectomy is rarely necessary because testes have an abundant and independent blood supply from testicular arteries, which arise directly from the abdominal aorta.<sup>[6]</sup> The efficacy of HBOT for the treatment of FG is still under debate and HBOT should not delay surgical intervention. Hollabaugh *et al.* has shown significant improvement combining traditional surgical and antibiotic regimens with HBOT, demonstrating a statistically significant survival advantage.<sup>[8]</sup>

Wide surgical debridement of all necrotic tissue, including skin, subcutaneous fat and fascia, frequently lead to defects that present a reconstructive challenge. Reconstruction of the genitalia and perineum require wound coverage without affect the urogenital and anorectal function. Furthermore, the high bacterial count in this area of the body predisposes to a significant risk of infection and wound breakdown. Surgical options comprise primary or secondary wound closure, skin grafting, local advancement flaps, fasciocutaneous flaps, muscle flaps, myocutaneous flaps or perforator flaps.<sup>[5-12]</sup> The choice of wound management should be



**Figure 3:** Intraoperative view following Integra application. Surgical application of dermal regenerative template



**Figure 4:** Post-operative final result at 18 months. Patient showed a satisfying functional and aesthetic result

determined by the general condition of the patient, the size, location and severity of the defects and the availability of local tissue.

According to Chen *et al.* when the defect involves less than half the scrotal surface area, a scrotal advancement flap can be performed.<sup>[5]</sup> The scrotal skin is expandable and stretchable, it provides a good aesthetic result and replaces like with like. If the defect is bigger and involves more than half the scrotal surface area, wrap-around skin grafting or pudendal thigh flap (Singapore flap) are both effective solutions for reconstruction.<sup>[5,10]</sup> In scrotal defects with a combination of perineal skin loss, surgical options may comprise pudendal thigh flap, anterolateral thigh (ALT) flap, superomedial thigh flap and gracilis muscle flap.<sup>[5,6]</sup> The pudendal thigh fasciocutaneous flap is a useful flap in perianal reconstruction, however special attention should be given to the design of skin paddle because apical necrosis has been widely reported.<sup>[11]</sup> The ALT flap has the advantages of a large skin paddle with abundant blood supply and a long vascular pedicle that permits a wide range of rotation, but the well-known disadvantage of high variability in the vascular anatomy. We also believe that ALT flap is not appropriate in obese patients, in which a skin graft is often required to repair the donor site. Gracilis muscle flap can be readily harvested as a muscle-only or myocutaneous flap and it's very useful to fill deep perineal defects after surgical aggressive debridement. The main disadvantages of this flap are the bulky volume, in some situations, and the sacrifice of a functional muscle.<sup>[5,6]</sup> In patients with a large skin defect, especially those who have a large wound involving the genitalia, perineum and abdominal wall, it is often necessary to resort to split-thickness skin grafting.<sup>[5]</sup> The split-thickness skin graft is safe and technically easy but is frequently associated with secondary contraction, less acceptable aesthetic result and lack of protection from vulnerability. Once the wound has been carefully debrided, after removing all necrotic and infectious material, negative pressure therapy can be applied to prepare the wound bed. Gross infection and recurrent infection within the wound is addressed by an extensive debridement followed by NPWT. Morykwas *et al.* have reported enhanced clearance of bacteria in NPWT treated subjects.<sup>[13]</sup> Though the anatomy in this region can make the placement of these NPWT devices difficult, if applied successfully it assists in the recovery of large perineal wounds by assisting and hastening granulation, promoting wound contraction,

reducing contamination and minimising the frequency of dressing changes. In our experience placement of the polyurethane NPWT sponge in close proximity to the corpus spongiosum or the skeletonised testicles was safe and avoided any complication or further injury to these structures. If there is damage to the urethra or suspicion of a urethral fistula, however, placement of a wound vacuum device could theoretically prolong the fistulous tract.<sup>[14]</sup> Dermal regeneration template has been developed for the treatment of deep partial-thickness or full-thickness thermal injury to the skin to reduce scarring and improve skin pliability;<sup>[13]</sup> it is a bilayer membrane system made of a porous coprecipitate of bovine tendon type I collagen and shark chondroitin-6-sulfate, covered by a temporary epidermal substitute made of polysiloxane (silicone).<sup>[14]</sup> The cross-linked collagen and chondroitin-6-sulfate layer allows for ingrowth of host fibroblasts and endothelial cells, providing a scaffold for dermal regeneration. The functional and aesthetic benefits arising from its application has widened its clinical indications to encompass its use in skin defects where less scarring and wound contracture are desirable.<sup>[15-17]</sup> Our patient presented with a large defect involving the scrotum, the perineum, the right ischial area and the lower abdomen. To deal with this complex wound we used multiple reconstructive procedures, comprising application of dermal regenerative template to minimise post-operative contracture and improve skin pliability. To deal with this complex wound we used multiple reconstructive procedures, comprising application of dermal regenerative template to improve skin pliability and minimize postoperative contractures, which might otherwise affect urogenital and anorectal function. Incorporation of the synthetic dermal substitute can be accelerated by subatmospheric pressure, with improved take rate and fewer complications, especially when used in concave and circumferential areas of the body. Moreover, NPWT evacuates wound secretions and blood, thus lowering the risk of seroma, haematoma and infection and shortening the time necessary for engraftment.<sup>[15,16]</sup> Dermal regeneration template has been successfully used for the reconstruction of the penis and anterior abdominal wall following necrotising fasciitis but, until now, there do not seem to be published reports that describe this technique to reconstruct the defect of perineum following FG.<sup>[15,16]</sup> In conclusion, combination of NPWT, dermal regeneration template and split-thickness skin grafting resulted in a satisfying reconstruction of the defect caused by FG.

## REFERENCES

1. Fournier AJ. Fulminating gangrene of the penis. *Semaine Med* 1883;3:345.
2. Smith GL, Bunker CB, Dinneen MD. Fournier's gangrene. *Br J Urol* 1998;81:347-55.
3. Corman JM, Moody JA, Aronson WJ. Fournier's gangrene in a modern surgical setting: Improved survival with aggressive management. *BJU Int* 1999;84:85-8.
4. Eke N. Fournier's gangrene: A review of 1726 cases. *Br J Surg* 2000;87:718-28.
5. Chen SY, Fu JP, Wang CH, Lee TP, Chen SG. Fournier gangrene: A review of 41 patients and strategies for reconstruction. *Ann Plast Surg* 2010;64:765-9.
6. Ferreira PC, Reis JC, Amarante JM, Silva AC, Pinho CJ, Oliveira IC, *et al.* Fournier's gangrene: A review of 43 reconstructive cases. *Plast Reconstr Surg* 2007;119:175-84.
7. Silberstein J, Grabowski J, Parsons JK. Use of a vacuum-assisted device for Fournier's Gangrene: A new paradigm. *Rev Urol* 2008;10:76-80.
8. Hollabaugh RS Jr, Dmochowski RR, Hickerson WL, Cox CE. Fournier's gangrene: Therapeutic impact of hyperbaric oxygen. *Plast Reconstr Surg* 1998;101:94-100.
9. Hallock GG. Scrotal reconstruction following Fournier gangrene using the medial circumflex femoral artery perforator flap. *Ann Plast Surg* 2006;57:333-5.
10. Tan BK, Rasheed MZ, Wu WT. Scrotal reconstruction by testicular apposition and wrap-around skin grafting. *J Plast Reconstr Aesthet Surg* 2011;64:944-8.
11. Tham NL, Pan WR, Rozen WM, Carey MP, Taylor GI, Corlett RJ, *et al.* The pudendal thigh flap for vaginal reconstruction: Optimising flap survival. *J Plast Reconstr Aesthet Surg* 2010;63:826-31.
12. Sinna R, Qassemyar Q, Benhaim T, Lauzanne P, Sabbagh C, Regimbeau JM, *et al.* Perforator flaps: A new option in perineal reconstruction. *J Plast Reconstr Aesthet Surg* 2010;63:E766-74.
13. Morykwas MJ, Argenta LC, Shelton-Brown EI, McGuirt W. Vacuum-assisted closure: A new method for wound control and treatment: Animal studies and basic foundation. *Ann Plast Surg* 1997;38:553-62.
14. Payne CE, Williams AM, Hart NB. Lotus petal flaps for scrotal reconstruction combined with Integra resurfacing of the penis and anterior abdominal wall following necrotising fasciitis. *J Plast Reconstr Aesthet Surg* 2009;62:393-7.
15. Moiemens NS, Vlachou E, Staiano JJ, Thawy Y, Frame JD. Reconstructive surgery with Integra dermal regeneration template: Histologic study, clinical evaluation, and current practice. *Plast Reconstr Surg* 2006;117 7 Suppl:160S-74.
16. Akhtar S, Hasham S, Abela C, Phipps AR. The use of Integra in necrotizing fasciitis. *Burns* 2006;32:251-4.
17. Dini M, Quercioli F, Mori A, Romano GF, Lee AQ, Agostini T. Vacuum-assisted closure, dermal regeneration template and degloved cryopreserved skin as useful tools in subtotal degloving of the lower limb. *Injury* 2012;43:957-9.

**How to cite this article:** Agostini T, Mori F, Perello R, Dini M, Russo GL. Successful combined approach to a severe Fournier's gangrene. *Indian J Plast Surg* 2014;47:132-6.

**Source of Support:** Nil, **Conflict of Interest:** None declared.