Published online: 2019-08-26



# A novel technique of monitoring a completely covered free flap

Sir,

Significance of monitoring free flaps cannot be overemphasized. Monitoring a flap that is completely

covered is often a challenging task. Different techniques are employed to that end depending on the situation,[1-3] each one with its own advantages and disadvantages. We share a novel technique that we used and found to be very helpful in monitoring a free flap when it is completely covered and out of sight.

A case of ameloblastoma mandible underwent segmental resection and free fibula flap for reconstruction. Since there was no skin paddle needed and hence used, monitoring the flap was to be a worrisome issue. Incidentally, we noted that the flap had an extra length of the peroneal vessels beyond the required length of the bone [Figure 1], as it happens quite often after shaping the fibula and sacrificing the excess bone. The artery had good pulsations and we planned to use it for post-operative monitoring.

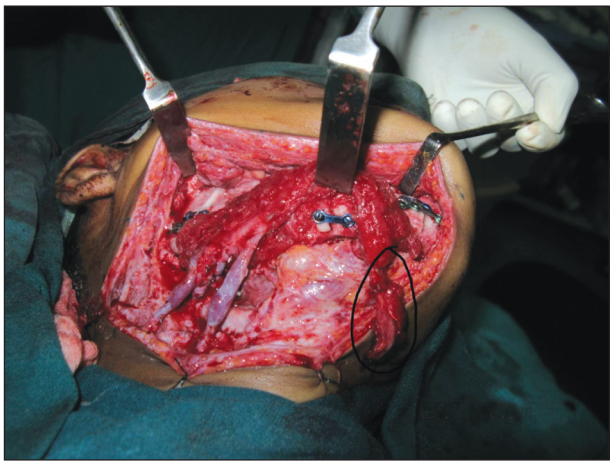

**Figure1:** Free fibula flap being inset at lower jaw. Outlined are the redundant peroneal vessels distal to the flap

**Figure 2:** Post-operative period. Shaded is the area undermined and pulsations felt for

We created a thin subcutaneous pocket on one side of the anterior end of the incision and placed there the distal redundant end of the peroneal vessels before closing the incision. Since it fell below the chin, a superficial elevation was deemed not unsafe for the skin flap but one that would easily transmit the pulsations. Besides, the pulse could be felt against the base of the tongue. The exact location of the pulsation was marked over the skin surface with a permanent marker [Figure 2] and was covered only by the dressing 'window'. Post-operatively, nursing staff in the intensive care unit were taught to lift the 'window' and gently feel for the pulse periodically.

The technique worked well. After 2 days, the pulsations were dampened by edema but could nevertheless be felt without much difficulty. We did not find the need for any other means of monitoring. The flap settled uneventfully and the pulsation (or the 'pulse') stayed on under the patient's chin.

Thus far, we have used this technique in one more patient with the same scenario and had similar experience of convenience in flap monitoring.

We recommend this technique whenever required and feasible as it is simple, easy to perform, safe, reliable, reproducible and obviate the need of machines for flap monitoring. Besides it avoids harvesting a skin paddle for the sole purpose of flap monitoring saving the patient any resulting discomfort and complications.

The technique can be applied in following conditions:

1. A flap that is going to be completely covered by native tissue leaving no window to watch for bleeding.
2. There is an excess length of pedicle 'distal' to the flap.
3. There are arterial outflows (at least one) in the segment to keep it from thrombosing.

Some technical finer points:

1. Keep the monitoring site outside the expanse of the flap for the safety of the flap.
2. Elevating a wider pocket/tunnel and keeping the pulse farther from suture-line will avoid pressing on the tender suture-line during the post-operative period.
3. A bulky segment may spoil the contours. Excise unwanted fat and other tissue.
4. Choose a bony or firm background in the vicinity against which to feel the pulsation and place the vessels accordingly.

5. Avoid placing the artery in close vicinity of any other pulsations to prevent confusion.
6. Expect dampening of pulse with edema. A hand-held Doppler may be used in place of digital palpation if required.

An important limitation of this technique is that it can monitor only arterial pulsations. Venous obstruction if any takes its time to progress to arterial obstruction. This point is to be borne in mind lest we feel too secure picking up arterial pulsations alone.

A higher volume center or a multi-centric experience can add more inputs to the technique in future.

**Kiran Petkar, K. S. Krishnakumar, Sameer Lateef, T. J. Arun, V. Suresh**

Department of Plastic Surgery, Baby Memorial Hospital, Calicut, Kerala, India

**Address for correspondence:**
Dr. Kiran Petkar, Department of Plastic Surgery, Maa Gayatri Hospital, Airport Road, Udaipur, Rajasthan, India.
E-mail: drkiranpetkar2009@gmail.com

## REFERENCES

1. Guo QF, Xu ZH, Wen SF, Liu QH, Liu SH, Wang JW, *et al*. Value of a skin island flap as a postoperative predictor of vascularized fibula graft viability in extensive diaphyseal bone defect reconstruction. Orthop Traumatol Surg Res 2012;98:576-82.
2. Meier JK, Prantl L, Müller S, Moralis A, Liebsch G, Gosau M. Simple, fast and reliable perfusion monitoring of microvascular flaps. Clin Hemorheol Microcirc 2012;50:13-24.
3. Pitak-Arnnop P, Hemprich A, Dhanuthai K, Pausch NC. Fibular flap for mandibular reconstruction: Are there old tricks for an old dog? Rev Stomatol Chir Maxillofac Chir Orale 2013;114:15-8.

**Access this article online**

| Quick Response Code: | Website: www.ijps.org |
| --- | --- |
| | DOI: 10.4103/0970-0358.129662 |