

Review Article

Recent advances in head and neck cancer reconstruction

Prabha Yadav

Department of Surgery, Tata Memorial Hospital, Dr. E. Borges Marg, Parel, Mumbai, Maharashtra, India

Address for correspondence: Dr. Prabha Yadav, Department of Surgery, Tata Memorial Hospital, Dr. E. Borges Marg, Parel, Mumbai - 400 012, Maharashtra, India. E-mail: drprabhatata@gmail.com

ABSTRACT

Treatment of cancer is race against time! Following radical excision, breathing, speech, mastication and swallowing are hampered. Face is invariably involved. Beside functional normalcy, excellent cosmetic restoration is necessary for patient's life quality. Primary wound healing, quick resumption of adequate oral intake, prompt initiation of chemo-radiotherapy has direct bearing on cure. Primary reconstruction with pedicle or free flap is the choice of treatment in most protocols. Composite defects are requiring bone, muscle and skin restrict choice of donor site and may have shortfalls in aesthetic and functional requirements. To improve further newer, and newer modalities are being developed and used to give best aesthetic and functions. Navigation, use of three-dimensional imaging, stereo lithic model and custom made implant for reconstruction are recommended as they promise improvement in aesthetics. Robotic surgeries allow access for resection of tumours and reconstruction with free flap in deep oropharynx obviating need of doing mandibulotomy. Researchers in stem cell and tissue engineering are looking forward to regenerating tissues and avoid the need of autologous tissue flaps. Desired tissue combination across counter may be available in the future. Excellent immunosuppressant drugs have made it possible to reconstruct composite facial anatomical units with allotransplant in a single surgery, along sensory and motor recovery! Mythological heterogenic head transplant like clone Ganesha, will be a reality in the near future!!

KEY WORDS

Head; mandible; reconstruction; transplant

INTRODUCTION

Cancers of head and neck are very common in India. Out of 50,000 new cases, 8000 are head and neck patients every year. Over 2000 major surgeries and about 800 reconstruction are performed every year at Tata Memorial Hospital, Mumbai.

Tumours in this area lead to cosmetic and functional deficits. The overall survival for patients with head and neck is promising and has remained static for last 35 years. Studies based on a large series have helped to develop reconstruction algorithms for different defects of head and neck region.^[1] Newer endoscopic laser-assisted techniques, advances in radiotherapy techniques like intensity modulated radiotherapy or image-guided radiotherapy are reducing damage to tissues without compromising treatment arm. In established disease, primary reconstruction with pedicle or free flaps offers reasonable function and aesthetic outcome.

Access this article online

Quick Response Code:



Website:

www.ijps.org

DOI:

10.4103/0970-0358.138939

RELEVANT HISTORY OF HEAD AND NECK RECONSTRUCTION

Development of plastic surgery is very well documented as early as 3000 BC. According to Hindu Mythology Ganesha emerged as a distinct deity in the 4th and 5th centuries CE, and has inherited traits from Vedic and pre-Vedic precursors.^[2,3] In 3000 BC, Edwin Smith Surgical Papyrus, from ancient Egypt, described first surgical management of facial trauma. Reduction of nasal fracture, followed by nasal cleaning, packing and splinting with linen. In 6th century BC, Shushruta from India described first operative procedures for nasal reconstruction by transferring skin from forehead and cheek. In the 1950s, defects were repaired using a forehead flap or temporal flap combined with split-thickness skin graft.

Milestones in Head & Neck Reconstruction

Year	Recent milestones	Researcher
1959	Revascularised flaps	Seidenberg
1965	Deltpectoral flap	Bakamjian
1967	Chondrocutaneous flap	Antia Buch
1973	First free flap using operating microscope	Daniel and Taylor
1976	Free flaps to reconstruct defects of the oral cavity	Panje and Harashina
1979	Pedicled pectoralis major myocutaneous flap	Ariyan
1989	Perforator flap	Koshima
1989	Free fibula osteocutaneous flap or mandible	Hidalgo
1990	Nobel prize for pioneering work in organ and cell transplantation	Joseph Murrey
1999	Tongue reconstruction gracilis musculocutaneous flap	Yousif NG
2001	Successful mandibular reconstruction using a BMP* bioimplant	Moghadam Hassan G
2005	First partial face transplant in France	Dr. Bernard Devauchelle
2010	Full face transplant performed in Spain	Dr. Joan Pere Barret

*BMP: Bone morphogenetic protein

Surgery is one of the main treatments for cancers of the head and neck. The aim of surgery is to excise the cancer completely. With the possibility of reconstruction, what cancer was termed as inoperable, has become operable. Judicious cancer surgeons have become bolder in resections.

In 1982, Mathes and Nahai introduced reconstruction ladder for closure of simple to complex wound.^[4] Today it is updated with the use of negative-pressure wound therapy, dermal matrices and perforator flaps.^[5] With the

escalation in technique of microsurgery, microsurgical flap is preferred as a direct route. Goals of reconstruction are to regain swallowing, speech, breathing and have symmetry of the face. Complex anatomy and physiology of head and neck region constitute a challenge for reconstructive surgeon. Lip, tongue, mandible, mid-face and defects of pharynx have specific anatomical and physiological functions.

Lip

Lip defects of up to one-third of lip can be closed primarily. From one-third to two-third defects, lip sharing techniques are useful. More than two-third defect need additional tissue by using local^[6] or distant flap. Local flaps are nasolabial flap or gate flap or cheek flap. In the lip, defects replace little less than what is lost so that it stays taught and helps in oral competence.

Tongue

Tongue is largest muscular organ in the oral cavity. Anterior two-third of the tongue is a mobile part of the tongue. Up to 30% of its defect can be closed primarily without affecting its functions. Defects up to 80% need thin pliable flap so it can be shaped like tongue, which also prevents tethering and allows remaining normal tongue to function.^[7] Free radial artery forearm flap (FRAF) is usually used as it is thin, pliable and has long vascular pedicle. One can have sensate FRAF.^[8]

Total or near total glossectomy needs a bulky flap to obliterate the space and give mound that can occlude against palate for swallowing and speech. Flap used are either anterolateral thigh flap (ALT), rectus abdominis myocutaneous flap or pectoralis major myocutaneous flap (PMMC).

Functional Gracilis muscle with gastro omental flap has been used. Gracilis muscle is attached between hyoid and mandibular bone, which on contraction lifts larynx up and prevents aspirations.^[9] Gastro-omental flap provides bulk.

There is no large series with long-term follow-up to prove the benefit of one over the other method of total tongue reconstruction.

Maxilla

Maxilla is six-dimensional hollow bone which supports mid-face skin, orbit, nose and teeth. Loss of this mid-face bone causes obvious aesthetic disruption and also affects

eating, swallowing and speech. Reconstruction with bone should be the aim. Reconstructions are individual, or institute based.^[10] Browns classification is simple and sound in its principle during planning reconstruction [Figure 1].^[11]

Maxillary defect must be assessed in horizontal and vertical dimensions. Reconstructive options available are from prosthesis to free tissue transfer. Isolated palatal defect are managed with obturator, local flap or free tissue flap-like FRAF depending on the size of the defect. In infrastructure maxillectomy with a horizontal extent less than half of the alveolar arch, prosthesis with SSG will be adequate. For larger defects reconstruction with vascularised bone flap-like free fibula osteocutaneous flap (FFOCF) is better than prosthesis (type 2).

Maxillary defect involving the orbital floor but sparing the eye is the most challenging defect to reconstruct (type 3). It needs bony support for orbital floor, cheek skin and dental rehabilitation. Amongst various bone flaps, available FFOCF is most used flap.

Prefabricated maxilla using titanium mesh prepared on three-dimensional (3D) skeletal model covered with ALT has been reported.^[12] Large volume maxillectomy defect with orbital exenteration is easy to reconstruct as there is no eye to worry about. It needs a bulky flap to fill up dead space (type 4). ALT or rectus abdominis myocutaneous flap could be the answer in such situation. To prevent contour deformity due to sagging of heavy flap, anchoring flap to zygoma is recommended.

In the palate preserving supra structure maxillectomy with orbital exenteration, defect needs a bulky flap as filler to seal off skull base like ALT or rectus abdominis myocutaneous flap.

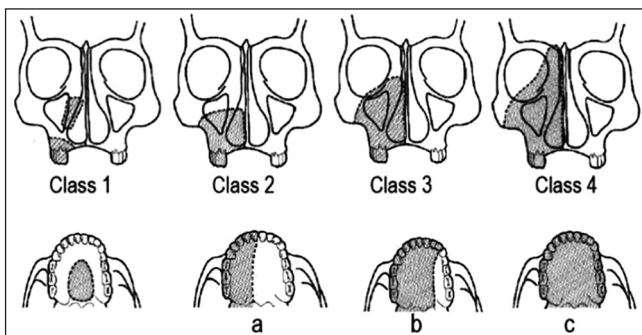


Figure 1: Brown's Classification

Defects that include palate, cheek, orbit and external nose are difficult to reconstruct with single flap. A combination of free flap and magnet retained facial prosthesis may be better for good functional and aesthetic outcome.^[13]

Mandible

In marginal mandibulectomy, as bone continuity is maintained reconstruction is not required. In posterior segment mandibulectomy, that is, lateral to the molars including condyle, segments 1-3, or 7-9, function is not affected to a large extent, is reconstructed with soft tissue alone [Figure 2].

Segmental removal of mandible whether lateral, anterior or combined, anywhere between two condyles, that is, 1-9 has a tremendous impact.

Both function and aesthetics need bony^[14] reconstruction. Single fibular flap (FFOCF) is adequate for most of the composite oromandibular defects. Skin paddles are divided based on septocutaneous perforators of the fibular flap.^[15] Second flap is advised, when the intraoral, as well as extraoral defects, are very extensive or when these defects are at different separate locations. This second flap can be generated from same fibular flap skin paddle by using proximal perforator^[16] or separate flap from a different donor site.^[17] Sensate FFOCF have been reported.^[18]

Reconstruction plate is used in very high risk or poor prognosis patients or as a spacer for definitive reconstruction at later date. In distraction osteogenesis and tissue engineered mandible, it obviates the need of bone graft. However, both are time consuming procedure.

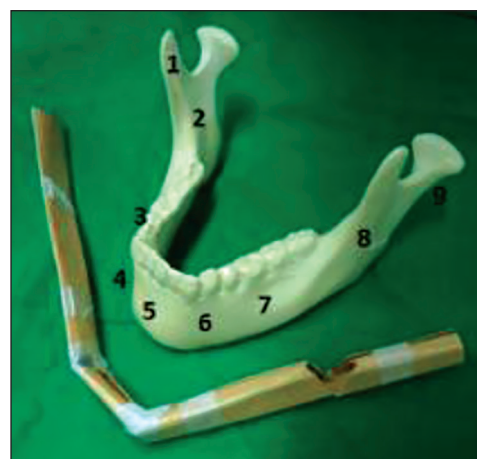

Figure 2: Segments of mandible

Tissue engineered mandible of 6 cm has been successfully constructed.^[19]

Pharynx

Anatomically larynx and pharynx are intimately related. Resection of one involves the other, both speech and swallowing are affected. After total laryngectomy with end tracheostomy, if remaining unstretched pharyngeal mucosal width is 3 cm or more, then primary closure is possible with good functional recovery.

If it is <3 cm, then its closure needs flaps like patch PMMC or FRAF or ALT.

In the case of circumferential defect, if lower end of defect is above thoracic inlet; then either jejunum or tubed FRAF or ALT is used, otherwise reconstructed with gastric pullup. Functional recovery is faster with mucosa lined tube like jejunum. Risk of fistula are also less as there is no additional vertical suture line as in FRAF or ALT.^[20]

RECENT ADVANCES

These current techniques are far from ideal. Use of newer techniques like using navigation during surgery, computer aided designing (CAD) and virtual surgery, stereo lithographic models, customized implants, robotic surgery, tissue engineering and allotransplants, are searching solutions. Excellent literature and plenty of information are available. They are still in developing stages. Definite solutions are awaited.

Navigational systems

Like global positioning system, navigation provides 3D road map.^[21] Advantages are accuracy, least trauma, shorter duration of surgery, reduced complications, fewer chances of recurrence and excellent success rate. Used mainly by neurosurgeons for removal of brain tumours that are seen on computed tomography or magnetic resonance imaging but are clinically difficult to distinguish from normal brain tissue.

Its use in soft tissue resections of head and neck is yet to be established. It has been used for lymphatic venous anastomosis.^[22] At present, it is being used for reduction of fractures of orbital floor and zygoma. Software based digital mirror image of the normal side or matching image from database is used for exact reduction. Size and volume are restored accurately.^[23]

Stereo lithographic models

Computer aided planning and CAD is used to evaluate exact site, size and shape of the defect preoperatively by using 3D imaging of the area involved. Virtual mandibular resections are done to prepare customized plate or implant. Similar technique can be used to develop a template for fibular bone osteotomy. It also guides in deciding which part and surface of fibula is best for dental implant in case primary implant based dental restoration is planned.^[24] It is used for planning in craniofacial surgeries or for making cranial bone implant that is, polyetheretherketone (PEEK) implant.^[25]

Though it provides several advantages, it still does not appear to decrease operative time enough to justify its cost, plus facility may not be available.^[26]

Robotic surgery

Vinci robotic arm positioned near patient reach inaccessible region easily. Performing surgeon has comfortable sitting position at console. With 3D, endoscopic, microscopic image and sensitive controls desired procedure can be done even from a remote place. Currently, robotic surgery is being used for resections and reconstruction of tumours at base of tongue and larynx, avoiding mandibulotomy for access which has its own morbidity.^[27] With trans-axillary approach, thyroid, para thyroid adenoma and neck lymph node can be operated without giving scar on the neck.

TISSUE ENGINEERING

Tissue engineering is an exciting new field that has potential to revolutionize reconstructive surgery.

Autologous flaps are limited and have donor area morbidity. They do not match exactly. Prosthetic materials may fail to integrate with body tissue. With tissue engineering technique and stem cell therapy, tissues can be regenerated, replaced or repaired for specific purposes. Biologic mediators or scaffolds^[28] are used for specific tissue. Three components: Scaffold, signalling molecule and cells decides success of tissue engineering. For the regeneration of tissue either all or some of these components are introduced, followed by *in-vitro* growth and maturation, to produce tissue or even organs.

Natural collagen, demineralized bone matrix, acellular matrix; or polymers — polyglycolic acid or metal — titanium^[29] are used as a scaffold at present.

Maximum progress of tissue engineering is in bone and cartilage regeneration.

Cartilage tissue engineering

Cartilage does not have ability to repair or regenerate. Reconstruction of cartilage defects are challenging due lack of suitable donor sites and prosthetic materials used have their own associated problems. Tissue engineering cartilage is relatively simple because it consists of only one cell type, the chondrocyte. It does not need neovascularization. It survives on the diffusion fluid for nutrition and excretion of waste products. Different shaped cartilage like ear or temporomandibular joint have been produced.^[29] Clinical use of tissue engineered cartilage, in head and neck is still not established as it still gets reabsorbed to a certain extent.

Tissue engineered trachea is still in experimental stage.^[30]

Tissue engineered bone

Bone is highly vascular tissue. It has ability to remodel and heal without scarring. Random non-vascular bone graft can manage small defect. Large defect or unfavourable environment like postradiotherapy need vascularised bone graft for reconstructions with microsurgical expertise. Available bone graft may not be adequate. Allografts have their own problems of reabsorption and infection.

Tissue engineered bone is either cell-based or growth factor based. Both need 3D scaffold as carrier. Bone morphogenetic proteins (BMPs) are most important growth factors for formation and differentiation of bone.

Bone morphogenetic proteins promote bone formation. It is used for treating nonunion of long bones, Le Fort osteotomies, in spine surgery and for alveolar regeneration and sinus floor augmentation.

Orthotopic or heterotopic bone formation is possible with the application of BMPs, process is called osteoinduction.

To fabricate tissue engineered bone, one needs an adequate number of cells with osteogenic capacity, appropriate scaffold for seeding cells, and factors to stimulate osteogenesis. But it needs blood supply for its transfer to a distant site. It has been possible to fabricate bone in latissimus dorsi muscle and then transferred it as free bone muscle flap.^[31] Mandibular defect has been reconstructed with this method. A titanium mesh cage

was filled with autologous bone, infiltrated with BMP-7 and then implanted into latissimus dorsi muscle. After 7 weeks transferred as free bone muscle flap to repair mandible defect.^[32]

ALLOTRANSPLANTS

Reconstruction of the entire face along with its delicate features is difficult to achieve. To avoid the patchwork effect with multiple flaps and skin grafts, one flap with similar colour, texture, thickness and composition lead to the development of allotransplant. Patient's face is removed and replaced with composite allograft. Depending on the requirement it includes the underlying fat, nerves, blood vessels, bones and/or musculature.^[33,34]

So far, 30 cases have been reported in the literature. Face transplants have transformed lives of nearly all surviving recipients. They have regained their ability to eat, drink, speak, smell, smile and blink.

The main ethical issue is subjecting that person to lifelong immunosuppressant therapy which is otherwise normal. But the deformity that one has is very severe. Social outcast is life limiting, and in this context it is a lifesaving procedure. Still it needs to be used judiciously.

FUTURE

Gene therapy and immune system targeting are being explored, and research wants to attack cancer at cellular or molecular level. In the future, progress in this technology will determine how much role surgery, chemotherapy and radiotherapy will have in treatment of cancer. However, mass education to improve oral hygiene and healthy habits has a great role in the prevention of these cancers in India.

CONCLUSION

Newer modalities like tissue engineering are in developing stage. In the future, we may have tissue banks to supply readymade body part for reconstruction. Similarly, medicines will be free of toxicity and side effect. But till such time, one must master current method of reconstruction. Reconstructive surgeon should learn and know at least three flaps: FFOCF, FRAF and free ALT which are sufficient to reconstruct any defect in head and neck cancer surgery.

REFERENCES

1. Hurvitz KA, Kobayashi M, Evans GR. Current options in head and neck reconstruction. *Plast Reconstr Surg* 2006;118:122e-33.
2. Narain AK. *Garain: The Idea and the Icon*. Brown, Robert (1991); Ganesh-Studies of an Asian God; ISBN0-7914-0657-1.
3. Understading Ganpathi: Insights into the dynamics of a cult; ISBN 8173041954.
4. *Grabb's Encyclopedia of Flaps*. Berish Strauch, Luis Vasconez 2009. ISBN 07181774926.
5. Janis JE, Kwon RK, Attinger CE. The new reconstructive ladder: Modifications to the traditional model. *Plast Reconstr Surg* 2011;127 Suppl 1:205S-12S.
6. Gill PS, Bidros RS, Boutros S. Reconstruction of oncological defects of the eyelid, lip and ear. *Indian J Plast Surg* 2007;40 Supp:S13-21.
7. Yadav P. Reconstruction surgery in oral cancers. *Indian J Plast Surg* 2007;40 Suppl:S22-37.
8. Kuriakose MA, Loree TR, Spies A, Meyers S, Hicks WL Jr. Sensate radial forearm free flaps in tongue reconstruction. *Arch Otolaryngol Head Neck Surg* 2001;127:1463-6.
9. Yoleri L, Mavioglu H. Total tongue reconstruction with free functional gracilis muscle transplantation: A technical note and review of the literature. *Ann Plast Surg* 2000;45:181-6.
10. Iyer S, Thankappan K. Maxillary reconstruction: Current concepts and controversies. *Indian J Plast Surg* 2014;47:8-19.
11. Brown JS, Rogers SN, McNally DN, Boyle M. A modified classification for the maxillectomy defect. *Head Neck* 2000;22:17-26.
12. Dediol E, Uglešić V, Zubcic V, Knežević P. Brown class III maxillectomy defects reconstruction with prefabricated titanium mesh and soft tissue free flap. *Ann Plast Surg* 2013;71:63-7.
13. Ahmed MM, Piper JM, Hansen NA, Sutton AJ, Schmalbach CE. Novel magnet-retained prosthetic system for facial reconstruction. *JAMA Facial Plast Surg* 2014;16:55-7.
14. Delacure M. Reconstruction of the mandible. *Indian J Plast Surg* 2007;40 Suppl:s28-34.
15. Jones NF, Vögelin E, Markowitz BL, Watson JP. Reconstruction of composite through-and-through mandibular defects with a double-skin paddle fibular osteocutaneous flap. *Plast Reconstr Surg* 2003;112:758-65.
16. Yadav PS, Shankhdhar VK, Dushyant J, Seetharaman SS, Rajendra G. Two in one: Double free flap from a single free fibula osteocutaneous unit. *Indian J Plast Surg* 2012;45:459-65.
17. Wei FC, Demirkan F, Chen HC, Chen IH. Double free flaps in reconstruction of extensive composite mandibular defects in head and neck cancer. *Plast Reconstr Surg* 1999;103:39-47.
18. Wei FC, Yazar S, Lin CH, Cheng MH, Tsao CK, Chiang YC. Double free flaps in head and neck reconstruction. *Clin Plast Surg* 2005;32:303-8, v.
19. Moghadam HG, Urist MR, Sandor GK, Clokie CM. Successful mandibular reconstruction using a BMP bioimplant. *J Craniofac Surg* 2001;12:119-27.
20. Patel D, Kuriokose MA, Iyer A. Reconstruction of laryngopharynx. *Indian J Plast Surg* 2007;40 Suppl:s44-51.
21. Collyer J. Stereotactic navigation in oral and maxillofacial surgery. *Br J Oral Maxillofac Surg* 2010;48:79-83.
22. Yamamoto T, Yamamoto N, Numahata T, Yokoyama A, Tashiro K, Yoshimatsu H, *et al*. Navigation lymphatic supermicrosurgery for the treatment of cancer-related peripheral lymphedema. *Vasc Endovascular Surg* 2014;48:139-43.
23. Evans BT, Webb AA. Post-traumatic orbital reconstruction: Anatomical landmarks and the concept of the deep orbit. *Br J Oral Maxillofac Surg* 2007;45:183-9.
24. Chang YM, Santamaria E, Wei FC, Chen HC, Chan CP, Shen YF, *et al*. Primary insertion of osseointegrated dental implants into fibula osteoseptocutaneous free flap for mandible reconstruction. *Plast Reconstr Surg* 1998;102:680-8.
25. Hanasono MM, Goel N, DeMonte F. Calvarial reconstruction with polyetheretherketone implants. *Ann Plast Surg* 2009;62:653-5.
26. Morris L, Sokoya M, Cunningham L, Gal TJ. Utility of stereolithographic models in osteocutaneous free flap reconstruction of the head and neck. *Craniofacial Trauma Reconstr* 2013;6:87-92.
27. Selber JC. Transoral robotic reconstruction of oropharyngeal defects: A case series. *Plast Reconstr Surg* 2010;126:1978-87.
28. Langer R, Vacanti JP. Tissue engineering. *Science* 1993;260:920-6.
29. Shieh SJ, Terada S, Vacanti JP. Tissue engineering auricular reconstruction: *In vitro* and *in vivo* studies. *Biomaterials* 2004;25:1545-57.
30. Kojima K, Bonassar LJ, Roy AK, Mizuno H, Cortiella J, Vacanti CA. A composite tissue-engineered trachea using sheep nasal chondrocyte and epithelial cells. *FASEB J* 2003;17:823-8.
31. Kusumoto K, Beshha K, Fujimara K, Akioka J, Ogawa Y, Jizuka T. Prefabricated bone graft including bone induced by recombinant bone morphogenic protein-2: An experimental study of ectopic osteoinduction in rat latissimus dorsi muscle flap. *Br J Plast Surg* 1998;51:275-80.
32. Warnke PH, Springer IN, Wiltfang J, Acil Y, Eufinger H, Wehmöller M, *et al*. Growth and transplantation of a custom vascularised bone graft in a man. *Lancet* 2004;364:766-70.
33. Devauchelle B, Badet L, Lengelé B, Morelon E, Testelin S, Michallet M, *et al*. First human face allograft: Early report. *Lancet* 2006;368:203-9.
34. Gini Graham Scott: The very next new thing - Commentaries on latest development that will change your life ISBN: 978-0-313-39411-9.

How to cite this article: Yadav P. Recent advances in head and neck cancer reconstruction. *Indian J Plast Surg* 2014;47:185-90.

Source of Support: Nil, **Conflict of Interest:** None declared.