

Original Article

An improved dual approach to post bariatric contouring — Staged liposuction and modified medial thigh lift: A case series

Zaher Jandali, Charles Yuen Yung Loh¹, Thanassi Athanassopoulos, Klaus Müller¹

Department for Plastic, Aesthetic and Reconstructive Surgery, Hamburg, Germany, ¹Department of Plastic Surgery, Ninewells Hospital, Dundee, Scotland.

Address for correspondence: Dr. Charles Yuen Yung Loh, Department of Plastic Surgery, Ninewells Hospital, Dundee, Scotland.
E-mail: chloh_yy@hotmail.com

ABSTRACT

Objective: Following massive weight loss (MWL) medial contouring of the thigh is frequently requested to improve appearance and function. Thigh lifting can be associated with significant complications. We present a case series of post bariatric patients undergoing thigh lift using staged the liposuction, a modified T incision and a buried de-epithelialised dermal flap. **Materials and Methods:** From January to December 2012, 21 consecutive patients underwent a modified medial thigh lift. A retrospective review of the case notes was performed to assess complications that occurred. **Results:** There were no major post-operative complications in terms of reoperation, hematoma, thromboembolism and no seromas. Seven patients, all of which were smokers had minor superficial wound healing complications. Aesthetic outcomes were satisfactory for all patients at a minimum follow-up of 6 months. **Conclusions:** The modified 'T' incision with staged liposuction is described. We have found the technique to be useful for a variety of different thighs. It is a reproducible method for contouring the medial thigh in MWL patients. In this series, our overall complications were low, and no seromas occurred.

KEY WORDS

Combined liposuction; modified; thigh lift; buried dermal flap

BACKGROUND

Thigh contouring in massive weight loss (MWL) patients poses a significant challenge to the plastic surgeon. MWL commonly affects the medial thigh region, resulting in poor skin elasticity and proximal fat deposits that cause embarrassment, chafing, and irritation.^[1,2] The thigh lift, first described by Lewis in

1957, has been modified to improve results and reduce complications.^[3-6] The horizontal inguinal crease incision with fascial suspension, the 'T' incision, which extends the horizontal inguinal crease incision vertically down to the medial knee region, and the 'L' incision are common approaches. We report our experience of staged liposuction and subsequent resection of the horizontal component followed by de-epithelialisation of the vertical component. The vertical component in then buried during the closure.

MATERIALS AND METHODS

The present study is a retrospective review of 21 patients who underwent medial thigh lift with a modified 'T' incision between January and December 2012. Eighteen

Access this article online

Quick Response Code:



Website:

www.ijps.org

DOI:

10.4103/0970-0358.138957

(85.7%) were female, and three (14.3%) were male. Mean age was 38 years (range, 27-52 years). Nine (42.9%) were smokers. Mean pre-operative body mass index (BMI) was 26.1 kg/m² (range, 19.5-29.4 kg/m²). All 21 patients had MWL after bariatric surgery: Mean weight loss was 62.3 kg (range, 44-143 kg). All patients had a lower body lift with liposuction of the medial thigh region, prior to the first stage of body contouring.

Three types of medial thigh conditions were identified and classified based on tissue volume and tightness of the skin. Type I was the 'non-deflated type', with a cutaneous envelope that is filled. Type II was the 'mixed type', with moderate volume and loose excess skin. Type III was the 'deflated type', with low-volume and excess loose skin. We also assessed whether skin laxity was limited to the proximal third of the thigh (horizontal type) or extends beyond the proximal third of the thigh (horizontal-vertical type). The procedure described herein targets the Type III (deflated) thigh, with horizontal-vertical type skin laxity. Non-deflated or mixed type thighs can be deflated by liposuction. The patient is then reviewed after 3 months, and the modified thigh lift is performed at 6 months. A horizontal inguinal crease thigh lift is used for thighs with horizontal type laxity.

Procedure

In the modified medial thigh lift procedure, pre-operative markings are made with the patient in both the upright and supine positions. The horizontal scar is planned at the inguinal crease, and the vertical scar runs along the medial aspect of the leg. The anterior part of the vertical scar is marked first, and then the posterior aspect is determined by pinching the skin. This marking scheme minimises the visibility of both scars [Figure 1a-c]. A single dose of a first-generation cephalosporin (e.g., cefazolin) is administered pre-operatively. During the surgery, the anaesthetised patient is positioned in a supine position, with a 90° angle between the thigh and the legs. Stockinettes are placed on the lower legs, which can then be moved freely. One surgeon sits between the legs; the assistant adopts a lateral position. The horizontal component in the inguinal crease region is corrected first, with particular attention to the superficial ventral inguinal area to avoid damage to lymphatic vessels and veins. Dissection is limited to the markings, to prevent dead space formation. The vertical excess skin is then marked, using temporary tailoring sutures along the pre-operative markings. De-epithelialisation of this excess is performed using a dermatome [Supplemental

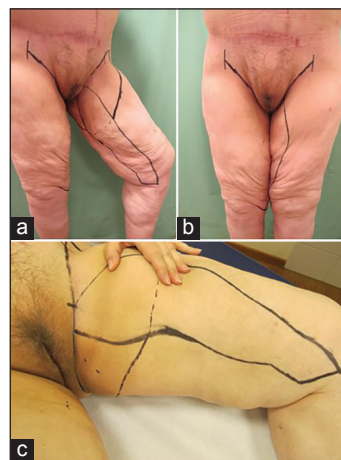

Figure 1: Photograph demonstrating the markings for our medial thigh lift. (a and b) Standing and (c) supine respectively

Digital Content 1]. A buried de-epithelialised dermal flap is used to reduce dead space formation.

Following the procedure, three to four deep anchoring sutures are placed into the Colles fascia, to prevent post-operative sagging of the medial thigh, to fix the scar in position, and to prevent migration and dehiscence. The sutures are a key element for an improved aesthetic outcome. They anchor the superficial fascia system of the medial thigh to the periosteum of the ischiopubic ramus and/or the Colles fascia (perineal fascia). We use a non-absorbable 1-0 monofilament suture (e.g., Ethilon, Ethicon, Inc., Somerville, N.J.). The superficial fascia of the horizontal incision is then closed with vicryl sutures (Ethicon, Inc., Somerville, N.J.). One or two drains may be placed at the horizontal and vertical incisions. Wound closure is performed with interrupted sutures (3-0 PDS, Ethicon, Inc., Somerville, N.J.) at the dermis, and an intradermal continuous suture (2-0 Monocryl, Ethicon, Inc., Somerville, N.J.). Dermabond (Johnson & Johnson, Langhorne, Pennsylvania) is then applied to avoid post-operative contamination. Compression garments are fitted immediately in the operating theatre, and should subsequently be worn day and night for at least 6 weeks.

Post-operative care includes mobilisation on the 1st post-operative day, low molecular weight heparin for thromboprophylaxis, and drain removal within 24 h, or when drainage <30 cc. If the patient feels uncomfortable or is in pain, patient-controlled analgesia is used for the first 24 h.

RESULTS

Among a total of 21 patients, 16 (76.2%) had Type II medial thigh, and 5 (23.8 %) had Type III. Mean operating

time was 92 min (range, 79-110 min). Mean weight of resection was 205 g (range, 60-748 g). Mean hospital stay was 5 days (range, 4-9 days). Drains were placed in 16 patients (76.2%), and removed after 2-4 days. No drains were used in five patients (23.8%). No blood transfusions were necessary, and all patients returned for a follow-up review. There were no perioperative complications related to the modified thigh lift procedure.

Post-operative follow-up ranged from 6 to 12 months. There were no major infections, thromboembolic complications, seromas, lymphocele, hematomas, or hypertrophic scars. Seven patients (33.3%), all active smokers, experienced superficial wound healing complications at the 'T' point (trifurcation point) of the medial thigh, the confluence of the vertical and horizontal scars, and were managed conservatively. No reoperations were required.

Post-operative results showed improved definition of the medial thigh region and satisfactory aesthetic outcomes in all patients. Pre- and post-operative views of two representative cases show significant improvement in the contour of the medial thigh [Figure 1].

DISCUSSION

Safety and avoidance of complications are paramount in MWL patients. Medial thigh lift procedures can be associated with significant morbidity including prominent scars, labial distortion, residual skin excess and recurrent ptosis. Post-operative complications, including delayed wound healing, and skin or fat necrosis, are sometimes long lasting and difficult to treat.^[1,6] Infrequent, but serious, complications include formation of lymph fistulas or lymphoceles. Lymphatic channels can be damaged, particularly with the extended vertical lift. Seromas and lymphatic fistulas have a reported incidence of up to 33% and a high recurrence rate in some series.^[1,2,7-11] It is important to distinguish between seromas associated with extended flap undermining, and lymphoceles resulting from damage to lymphatic vessels. Both complications typically present post-operatively within 3-4 weeks.^[8] Strategies used to manage these complications include external compression, introduction of sclerosing agents, placement of closed drainage catheters, revision operations (e.g., lymphatic ligation), vacuum therapy, mesh graft, flap surgery and lymph vessel surgery, and muscle flaps.^[1,2,8] However, the complications are difficult to manage and are best avoided.

High BMI is associated with a greater incidence of complications, and our preference is to select patients with a BMI <30. In the 21 patients of the present study, 'junction' complications occurred only in active smokers. The seroma rate was 0%, comparing favourably to reported rate.^[1] The outcomes of surgery are shown for two patients [Figures 2, 3 and 4]. The low-seroma rate in this technique is probably due to the reduced of dead space with a buried dermal flap and the combined

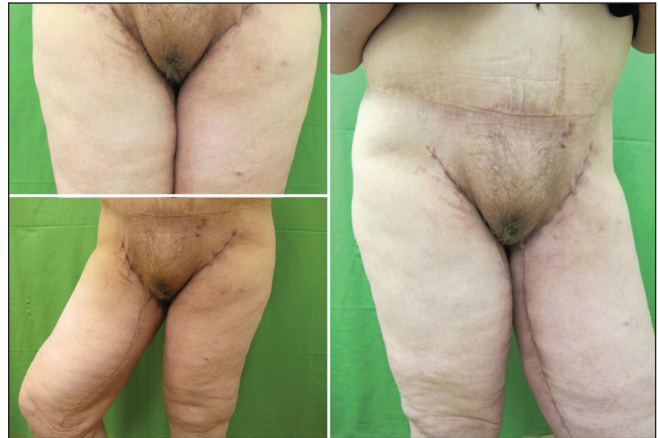

Figure 2: Photograph demonstrating early post-operative outcomes after our medial thigh lift

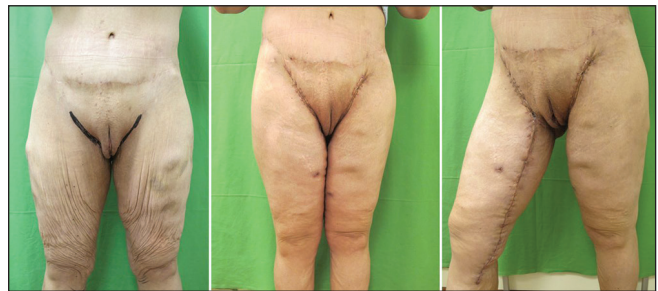

Figure 3: Another photograph demonstrating early post-operative outcomes after medial thigh lift. Note the superficial wound healing complication at the apex of the T

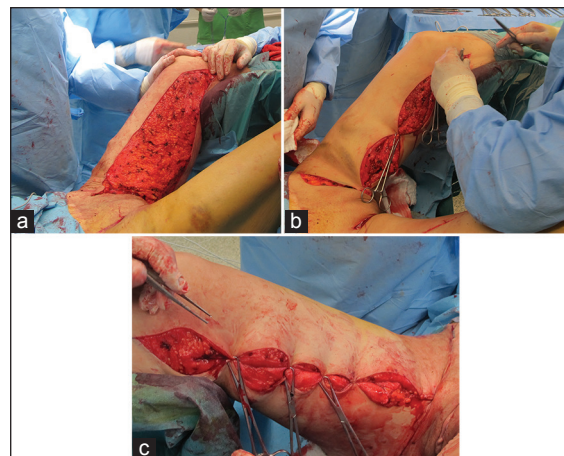


Figure 4: (a-c) Intraoperative photographs demonstrating technique

used to liposuction which generally preserves lymphatic channels.

The main drawback of the modified thigh lift procedure is that patients with Type I and II medial thighs require liposuction several months prior to the procedure. However, this can be combined with an additional contouring procedure. The appearance of the medial thigh might be worse in the interim period, so patients are counselled regarding the importance of this initial step and are shown photographs at each stage of surgery. Some surgeons perform liposuction and resection concomitantly; however, we believe that the combined procedure involves a higher risk of complications. In our experience, the modified procedure provides satisfactory aesthetic outcomes with manageable complications. At follow-up, all patients were pleased with the outcome of surgery.

CONCLUSIONS

The modified medial thigh lift method is useful for correcting circumferential medial thigh excess. Careful pre-operative markings, tailoring the resection and avoidance of undermining are critical to minimise complications and to provide reproducible aesthetic outcomes.

REFERENCES

1. Kolker AR, Xipoleas GD. The circumferential thigh lift and vertical extension circumferential thigh lift: Maximizing aesthetics and safety in lower extremity contouring. *Ann Plast Surg* 2011;66:452-6.
2. Borud LJ, Cooper JS, Slavin SA. New management algorithm for lymphocele following medial thigh lift. *Plast Reconstr Surg* 2008;121:1450-5.
3. Lewis JR Jr. The thigh lift. *J Int Coll Surg* 1957;27:330-4.
4. Schultz RC, Feinberg LA. Medial thigh lift. *Ann Plast Surg* 1979;2:404-10.
5. Lewis JR Jr. Correction of ptosis of the thighs: The thigh lift. *Plast Reconstr Surg* 1966;37:494-8.
6. Lockwood TE. Fascial anchoring technique in medial thigh lifts. *Plast Reconstr Surg* 1988;82:299-304.
7. Stadelmann WK. Intraoperative lymphatic mapping to treat groin lymphorrhea complicating an elective medial thigh lift. *Ann Plast Surg* 2002;48:205-8.
8. Leitner DW, Sherwood RC. Inguinal lymphocele as a complication of thighplasty. *Plast Reconstr Surg* 1983;72:878-81.
9. Spirito D. Medial thigh lift and DE.C.LI.VE. *Aesthetic Plast Surg* 1998;22:298-300.
10. Le Louarn C, Pascal JF. The concentric medial thigh lift. *Aesthetic Plast Surg* 2004;28:20-3.
11. Kenkel JM, Eaves FF 3rd. Medial thigh lift. *Plast Reconstr Surg* 2008;122:621-2.

How to cite this article: Jandali Z, Loh CY, Athanassopoulos T, Müller K. An improved dual approach to post bariatric contouring - Staged liposuction and modified medial thigh lift: A case series. *Indian J Plast Surg* 2014;47:232-5.

Source of Support: Nil. **Conflict of Interest:** None declared.

Announcement

14 – 16 NOVEMBER, 2014

ISSHCON 2014 Annual Conference of Indian Society of Surgery of the Hand

Venue: Dr. TMA Pai International Convention Centre at MG Road Mangalore

Contact: Dr. B Jagannath Kamath, Organizing Chairman

ISSHCON 2014 Conference Secretariate

IMA House, Attavar Road, Near Railway Station

Mangalore-575001

Cell No: 09845235747