

Iatrogenic metacarpal fracture complication secondary to K-wire fixation

Sir,

We present a K-wire-related complication in the management of a Bennett fracture and would like to highlight the importance of planning K-wire placement and minimising the number of K-wire passes.

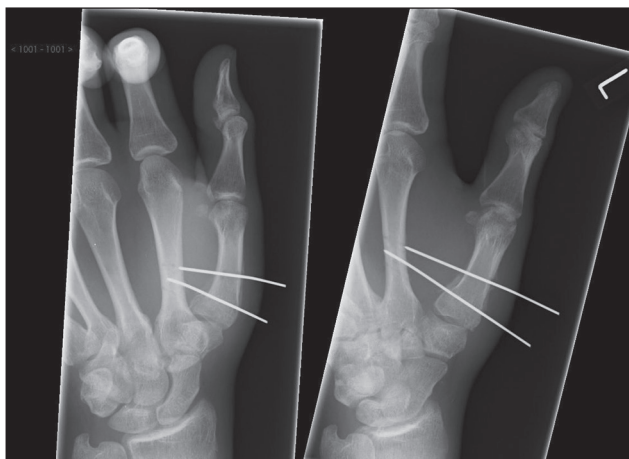


Figure 1: Radiograph demonstrating anterior-posterior and oblique views post K-wire fixation

After having fallen from a roof, a 42-year-old patient was referred to our hand trauma unit with a Bennett fracture; he had previously had pinning across the first and second metacarpals with 1.1 mm K-wires at another hospital [Figure 1]. According to our protocol, we reviewed him at 5 weeks, removed the K-wires and began mobilisation.

Three days later, he noted the acute onset of pain at the base of the second metacarpal. A radiograph of his hand was taken in the emergency department that demonstrated a unicortical fracture through the second metacarpal where the K-wire had entered the bone [Figure 2]. He was treated with a volar cast for the second fracture and made an uneventful recovery.

Fracture through a previous K-wire tract is a known complication of K-wire treatment.^[1] From our literature search on Medline and Embase using keywords like ‘complications of K-wires’, collateral K-wire damage in an adjacent bone has not been reported.

When using K-wires, their thickness, relation to each other, number of passes, fracture geometry, surrounding soft tissues including neurovascular structures and tendons must be considered.

Multiple passes of the K-wire onto cortical and cancellous bone, resulting in blunting of the K-wire and subsequent heat generation. A zone of necrosis around the pin site can lead to subsequent loosening and loss of fixation.

K-wires crossing the fracture site can cause fragment distraction. K-wire convergence can create a pivot

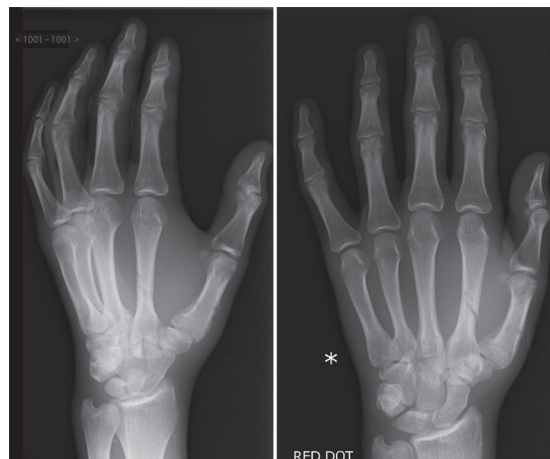

Figure 2: Radiograph demonstrating the adjacent second metacarpal fracture post removal of K-wires

point with resulting rotational instability. In this case, convergence resulted in a stress zone on the adjacent metacarpal. Multiple adjacent pin tracts further weaken the bone, similar to perforations between stamps facilitating structural failure.

Surgeons should be aware of the potential damage to bone during K-wire fixation. Preoperative planning, marking the K-wire route on the skin and appropriate K-wire thickness minimise complications. Patients should be told that following K-wire removal, the residual holes could subject to stress risers and that several weeks are needed before they can use their injured hand normally.

**Charles Yuen Yung Loh, Nigel Yong Boon Ng¹,
Meiling Loh², Nanda Kandamany,
Thanassi Athanassopoulos**

Department of Plastic Surgery, Ninewells Hospital, Dundee,
¹Aberdeen Medical School, Aberdeen, Scotland,
²National University of Singapore, Singapore

Address for correspondence:

Dr. Charles Yuen Yung Loh, Department of Plastic Surgery,
Ninewells Hospital, Dundee, Scotland.
E-mail: chloh_yy@hotmail.com

REFERENCE

1. Hsu LP, Schwartz EG, Kalainov DM, Chen F, Makowiec RL. Complications of K-wire fixation in procedures involving the hand and wrist. *J Hand Surg Am* 2011;36:610-6.

Access this article online	
Quick Response Code: 	Website: www.ijps.org
	DOI: 10.4103/0970-0358.138986