

## Original Article

# Enhancing dermal and bone regeneration in calvarial defect surgery

Bruno Zanotti, Nicola Zingaretti<sup>1</sup>, Daria Almesberger<sup>1</sup>, Angela Verlicchi<sup>2</sup>, Roberto Stefini<sup>3</sup>, Mauro Ragonese<sup>4</sup>, Gianni Franco Guarneri<sup>1</sup>, Pier Camillo Parodi<sup>1</sup>

Neurosurgery Clinic, University of Udine, <sup>1</sup>Department of Plastic and Reconstructive Surgery, University of Udine, <sup>2</sup>Neurology Unit, Free University of Neuroscience "Anemos", Reggio Emilia, <sup>3</sup>Neurosurgery Clinic, A.O. Spedali Civili, Brescia, <sup>4</sup>Urologic Clinic, Catholic University Medical School of Rome, Italy

**Address for correspondence:** Dr. Nicola Zingaretti, Department of Plastic and Reconstructive Surgery, University of Udine, Piazza Rodolone 3, 33013 Gemona del Friuli (UD) Italy. E-mail: zingarettin@gmail.com

### ABSTRACT

**Introduction:** To optimize the functional and esthetic result of cranioplasty, it is necessary to choose appropriate materials and take steps to preserve and support tissue vitality. As far as materials are concerned, custom-made porous hydroxyapatite implants are biomimetic, and therefore, provide good biological interaction and biointegration. However, before it is fully integrated, this material has relatively low mechanical resistance. Therefore, to reduce the risk of postoperative implant fracture, it would be desirable to accelerate regeneration of the tissues around and within the graft.

**Objectives:** The objective was to determine whether integrating growth-factor-rich platelet gel or supportive dermal matrix into hydroxyapatite implant cranioplasty can accelerate bone remodeling and promote soft tissue regeneration, respectively. **Materials and Methods:** The investigation was performed on cranioplasty patients fitted with hydroxyapatite cranial implants between 2004 and 2010. In 7 patients, platelet gel was applied to the bone/prosthesis interface during surgery, and in a further 5 patients, characterized by thin, hypotrophic skin coverage of the cranial lacuna, a sheet of dermal matrix was applied between the prosthesis and the overlying soft tissue. In several of the former groups, platelet gel mixed with hydroxyapatite granules was used to fill small gaps between the skull and the implant. To confirm osteointegration, cranial computed tomography (CT) scans were taken at 3-6 month intervals for 1-year, and magnetic resonance imaging (MRI) was used to confirm dermal integrity. **Results:** Clinical examination performed a few weeks after surgery revealed good dermal regeneration, with thicker, healthier skin, apparently with a better blood supply, which was confirmed by MRI at 3-6 months. Furthermore, at 3-6 months, CT showed good biomimetism of the porous hydroxyapatite scaffold. Locations at which platelet gel and hydroxyapatite granules were used to fill gaps between the implant and skull appeared to show more rapid integration of the implant than untreated areas. Results were stable at 1-year and remain so to date in cases where follow-up is still ongoing. **Conclusions:** Bone remodeling time could be reduced by platelet gel application during cranioplasty with porous hydroxyapatite implants. Likewise, layering dermal matrix over such implants appears to promote dermal tissue regeneration and the oshtemo mimetic process. Both

of these strategies may, therefore, reduce the likelihood of postsurgical fracture by promoting mechanical resistance.

### KEY WORDS

Biomaterials integration; bone regeneration; cranioplasty; dermal matrix; platelet gel

Access this article online	
Quick Response Code:	Website: www.ijps.org
	DOI: 10.4103/0970-0358.146581

## INTRODUCTION

It is almost impossible to correct skull defects caused by trauma, tumor resection and/or other pathologies by relying exclusively on the intrinsic regenerative capacity of bone. In Europe alone, there are more than three million patients who would benefit from reconstructive cranial bone therapy, making it a significant clinical and economic issue.<sup>[1]</sup>

Grafts to fill cranial lacunae are the treatment of choice, such as exchange cranioplasty using autologous calvarian particulate bone graft,<sup>[2]</sup> although there are disadvantages to this approach. In particular, the autologous supply is very limited, and bone grafting can cause trauma at the previously healthy donor site, potentially increasing the risk of other medical issues. Allografts and xenografts (Bovine Spongiform Encephalopathy), on the other hand, present a potential risk of transmitting infective diseases (HIV). Furthermore, whatever their source, 25-50% of bone grafts are plagued by re-absorption phenomena.<sup>[3,4]</sup> Moreover, the cranial morphology is almost impossible to replicate using bone harvested from other areas, making esthetic outcomes partial at best.

These limiting factors have driven the search for an optimal artificial bone replacement. Although a wide variety of materials have been proposed, and indeed are currently in use, none is yet able to provide the ideal combination of biological interactivity and primary resistance. Nevertheless, using custom-made implants to correct cranial lacunae (especially those due to destructive pathologies such as meningioma and metastases) and single-step cranial demolition-reconstruction processes is now standard operating procedure with unquestionable advantages. Specifically, it improves the functional and esthetic results and reduces surgery times and the attendant burden to both the patient and the operating facility's budget.<sup>[3]</sup> In cranial demolition-reconstruction in particular, the accuracy of implant positioning can be improved by routine use of 3D computer guidance, i.e., the neuronavigator.<sup>[3,5]</sup>

That being said, calvarian defect surgery is still troublesome in pediatric patients, and neither autologous bone grafts nor artificial implants have yet provided a satisfactory solution. Rogers *et al.*, for example, treated 20 young patients with autologous bone, and 5 of these showed residual bone defects. To put this percentage (25%) into perspective, it should also be noted that the risk of bone

re-absorption can be as high as 50% in young patients.<sup>[2,4]</sup> On the other hand, the use of artificial cranial implants is severely limited by the fact that they cannot grow as the patient does, making such an approach unfeasible in pediatric surgery, particularly in patients under the age of eight.

In adults, the ideal cranioplasty implant must have marked biomimetic properties (bio-interaction, bio-integration, bio-stimulation),<sup>[2]</sup> and the material that best fulfills this criterion is currently hydroxyapatite (HA).<sup>[3,6]</sup> Indeed, all forms of HA have excellent biocompatibility and display osteoconduction and attachment properties when placed in direct contact with the bone. Although cases of intolerance to implant materials such as polymethyl acrylate, titanium, and calcium phosphate cement have been documented; no such cases have been reported for custom-made HA implants.<sup>[7-9]</sup> Furthermore, the fact that HA implants can be accurately constructed to fit individual lacunae makes them an excellent choice, and in the presence of bone growth-induction factors, they also promote osteoinduction.

### Ceramic hydroxyapatite is available in two forms

dense and porous. The former is entirely synthetic, poreless, and available in either block or granular form. Dense HA is, however, poorly suited to surgical applications, being difficult to shape and failing to allow bone tissue to grow. In contrast, porous HA, whether produced synthetically or obtained from the skeletons of certain, chemically converted marine corals, fills and mimics the mineral component of bone perfectly, particularly spongy bone, enabling bone cell regeneration in cases of fracture.<sup>[3,6]</sup> Indeed, osteofibrous tissue readily grows inside porous HA, promoting attachment to the surrounding bone tissue within a few weeks or months.<sup>[6]</sup>

Upon complete osteointegration, HA implants generally consist of about 17% bone, 43% soft tissue, and 40% HA.<sup>[10]</sup> It is clear, therefore, that a high degree of biomimetism can be achieved by ceramic scaffolds like porous HA (70-90% of total porosity).<sup>[11,12]</sup> Their osteoconductivity is directly proportional to scaffold porosity, which in HA implants can vary in terms of size, number of pores, and type of interconnection (60-70% porosity with macro-pores of 200-500  $\mu\text{m}$ , micro-pores of 1-10  $\mu\text{m}$  and interconnection holes of 50-200  $\mu\text{m}$ ).<sup>[11,12]</sup> Put simply, the greater the degree of interconnection and porosity, the better the osteoconductive result.<sup>[13]</sup>

As well as offering very good connectivity with bone, HA implants, when custom-shaped, provide excellent esthetic results. However, HA is an extremely fragile material, and therefore, breaks easily without any plastic deformation. The yield point of HA is very high, coinciding with the maximum tensile stress, as it contains crystals whose interconnections are very difficult to dislocate.<sup>[3,14]</sup> These physical-mechanical properties make HA implants - although able to withstand physiological stresses for a certain period - more vulnerable than the natural bone the material is intended to mimic and replace. It would, therefore, be highly desirable to accelerate osteoblast and osteoclast invasion within the HA scaffold, and in turn, accelerate osteoinduction and the development of mechanical resistance equivalent to that of the surrounding normal bone. Regenerative medicine and tissue engineering are, therefore, being explored as means of enhancing the performance of artificial implants by incorporating materials that can trigger and induce tissue repair mechanisms.

We report here, the outcomes (after surgery and at follow-up) of several cases of reconstructive surgery performed using HA cranial implants alongside either platelet gel or dermal matrix to promote bone and dermal regeneration, respectively.

## MATERIALS AND METHODS

This retrospective case series analysis was performed on cranioplasty patients treated at the University Hospital of Udine between January 2004 and January 2010. During this period, custom-made HA cranial implants were fitted in 68 patients (42 males and 26 females).

In 7 cases, a novel approach was tried, inserting a thin layer of platelet gel (2-3 mm) between the bone edge and the prosthesis, and another over the external surface of the prosthesis, under the soft tissue above it. Cases were selected for this procedure on the basis of the fit of their prosthesis - as HA implants are custom-made, there was seldom sufficient space to accommodate a platelet gel sheet at the bone/implant interface. Where any small gaps remained at this interface (n. 7/7 patients), these were filled with a mixture of platelet gel and 900 nm granules of hydroxyapatite (characterized by variable interconnected macroporosity of 5-50 mm).

In five other cases, in which the overlying skin appeared thin and hypotrophic, a single layer of dermal matrix was implanted over the graft.

All patients underwent cranial computed tomography (CT) scan (bone resolution) to enable assessment of ossification levels at the edges of the cranioplasty. The baseline scan was taken within 48 h of surgery (T0), another after 3-6 months (T1), and another at 1-year (T2). Patients are also continuously monitored up to the present day as part of routine follow-up.

Dermal regeneration was assessed both clinically and via cranial magnetic resonance imaging (MRI) performed within 3 months of the operation.

Informed written consent was obtained from all patients.

### Hydroxyapatite implants

The porous HA cranial implants fitted were all custom-made by FinCeramica (Faenza, Italy). In simple reconstruction, the procedure was as follows: Thin-layer cranial CT and DICOM data generation; three-dimensional reconstruction of the patient's cranium in resin (scale 1:1); prototype production; neurosurgeon's approval and validation of the implant morphology, curvature, and thickness; custom-made HA implant production; sterilization and delivery to the surgical team.<sup>[3,15]</sup>

In demolition-reconstruction cases, the portion of the cranial bone to be removed was marked by the surgeon on the three-dimensional resin model, including a perilesional (safety) margin, prior to production of the implant prototype.<sup>[3,15]</sup> In the latter cases treated, this step was performed virtually via a newly accessible WEB-2 link between the hospital and the manufacturer's laboratory, thereby obviating the need to physically move the model [Figure 1]. At the hospital, implant positioning and demolition-reconstruction surgeries were planned with the aid of CT scans of the three-dimensional resin model (featuring the surgical lacuna) integrated with the MR images of the patient's cranium [Figure 2] using a neuronavigator.

### Platelet gel

To produce the growth-factor-rich platelet gel used in the operations, a venous blood sample of around 65 ml was taken from each patient 2 (or a maximum 4) days before surgery. Each sample was subjected to 2 low-rate

centrifugation cycles, each of 15 min, the first at 180-200 ×g, and the second at 560 ×g. This yielded a platelet concentrate of around 8 ml (platelet count of 1,265,000 mL, with platelet enrichment 616% and platelet recovery of 64%), which was later mixed with the activator (calcium gluconate and autologous serum) during surgery. This formed a gel in 3-5 min, which was applied to the HA implant as shown in Figure 3. The gel was used within 15-20 min of concentrate activation.

Patients were instructed to avoid dairy products for the few hours before the blood sample was taken. Carriers of cardiovascular diseases and those with thrombocytopenia, ongoing beta-blocker treatment, or prior anticoagulant therapy were excluded from surgery, as were those who tested positive for HIV and/or hepatitis. Surgery was not carried out on patients showing signs of infection in progress, and no surgical patient had any metabolic illnesses.

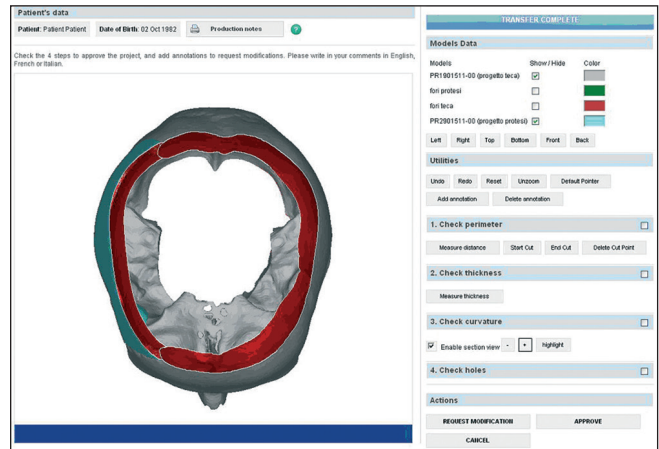
**Dermal matrix**

The dermal matrix applied over the cranial implant before soft tissue closure consisted of a nonliving, semi-biological membrane implant (INTEGRA® Dermal Regeneration Template single-layer film), essentially a porous single-layer sheet of reticular collagen extracted from bovine Achille's tendon, and glycosaminoglycan (chondroitin 6-sulfate), The size of each dermal matrix sheet was 20 × 25 cm, thickness 2-3 mm. Due to extreme dermal thinness, a double layer of dermal matrix was used in 2 patients.

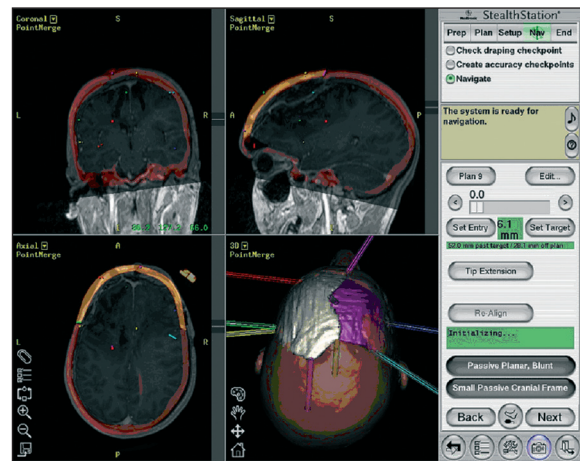
**RESULTS**

About 60% of the total 68 patients were scheduled for surgery following cranial trauma or decompression surgery (posttraumatic, postischemic, or posthemorrhagic), 20% due to tumors involving the skull, 18% as second-line treatment following bone operculum reabsorption or osteitis of the autologous bone, and 2% following adverse reactions to previous cranial implants made of other materials. Three patients underwent a double implant owing to the significant size of their cranial lacunae.

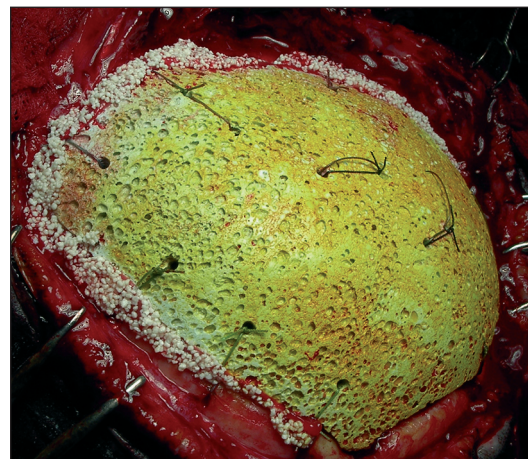
In all surgical demolition-reconstruction procedures, the cranial destruction phase was performed using the Neuronavigator (Neurosurgery Clinic, University Hospital of Udine) or the anatomical landmarks (Neurosurgery Clinic - Hospital of Brescia).



**Figure 1:** The entire hydroxyapatite cranial implant design process can be carried out using a web portal, from transmission of the patient's neuroradiological data to the validation of the prosthesis, with direct interaction between operators and technicians



**Figure 2:** Neuronavigator implementation of the patient's magnetic resonance data with computed tomography scan of the three-dimensional model of the patient's cranium. The cranial prosthesis has been marked out (in two pieces, in this particular case) for a neuronavigator-assisted surgical demolition-reconstruction procedure



**Figure 3:** Applying the platelet gel mixed with granules of hydroxyapatite to the frontal section of the cranioplasty. At the back, the space between the bone and cranioplasty perimeter is left free

### Hydroxyapatite cranioplasty

all patients showed excellent aesthetic and functional results, and all patients pronounced themselves satisfied.

#### *Platelet gel*

Cranial CT scans showed that in all patients in the platelet gel group, at locations where the gel had been applied, the HA implant perimeter was successfully attached within 3-6 months. This was often not the case at those not treated with platelet gel [Figure 4]. In our small sample, no discernable differences in osteointegration rate were seen between patients treated with platelet gel alone and those treated with the gel and HA granule filler.

#### *Dermal matrix*

In cases in which a dermal matrix was inserted between the HA prosthesis and the soft tissue, both clinical observation performed a few weeks after surgery and cranial MRI at 3-6 months showed good dermal regeneration with respect to its presurgical state [Figure 5].

#### *Complications*

Two cases of complications arose in our series, both in the group given neither platelet gel nor dermal matrix. Specifically, one patient who had already been operated on several times for meningioma, and had suffered a previous infection of the operculum a decade earlier, developed ischemic necrosis of the skin flap. In order to resolve this issue, it was necessary to remove the prosthesis and create a rotation flap. In another case, the soft tissue overlying the implant became infected,

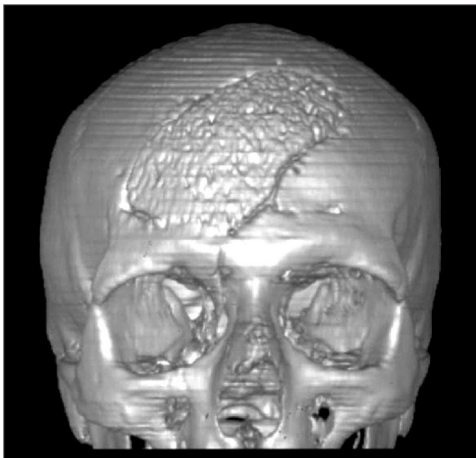
necessitating prolonged, targeted antibiotic treatment. In this case, however, the patient was able to keep their prosthesis.

There were no cases of intolerance or adverse reactions to either the HA implant, the platelet gel or the dermal matrix used. Patients whose treatment involved platelet gel or dermal matrix were monitored up to 2013, and no medical issues ascribable to the cranioplasty procedure came to light.

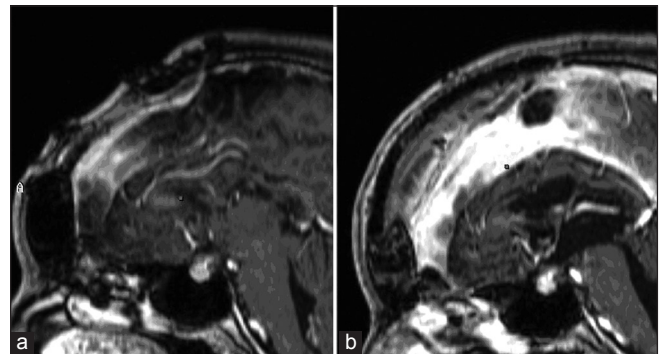
### DISCUSSION

First and foremost, our results confirm that HA implants are well-tolerated by cranioplasty patients, and likewise, the autologous blood derivatives-platelet gel-we used in the operating theater as part of the cranioplasty procedure itself with the aim of promoting tissue regeneration around the implant.<sup>[16,17]</sup>

Platelet gel is essentially a concentrated form of peripheral blood with reduced red blood cells (<15% of their physiological value) 4-6 times the concentration of platelets and growth factors, and an equivalent concentration of fibrin. The growth factors within the gel are said to promote tissue regeneration, in concert with many other different molecules freed by the activated platelets.<sup>[16,18]</sup> The contribution of platelet growth factors to cell stimulation and replication, thereby favoring the formation of bone tissue, has been well-documented. In particular, platelet-derived growth factor has a mitogenic and angiogenic action, as well as regulating other growth factors. In addition, epidermal growth factor stimulates mesenchymal and epidermal cells; transforming growth



**Figure 4:** Seriated cranium computed tomography scan (at 48 h, and roughly 3, 6, and 12 months from fitting the custom-made porous hydroxyapatite cranioplasty implant). Platelet gel mixed with hydroxyapatite granules has been applied in the frontal area, whilst the occipital area has none. From the third to the 6<sup>th</sup> month, initial frontal attachment is observed, which is completed within a year. Progress at the back, in the absence of the filler, is slower



**Figure 5:** (a and b) Magnetic resonance (MR) images before and after insertion of a custom-made porous hydroxyapatite frontal cranioplasty implant covered by a small sheet of dermal matrix. In the presurgical MR (left), the derma appears thinner and patchy. In the postsurgical MR, carried out a few months later, the derma looks healthier, more uniform, and is almost identical to that observed after cranial table-cranioplasty conjunction

factor-beta, stimulates fibroblasts and preosteoblasts, inhibiting epithelial and endothelial cells, osteoclasts and bone reabsorption; and insulin-like growth factor I and II, stimulate osteoblasts, their precursors, and bone deposition.<sup>[16,19]</sup>

Through these factors, bone regeneration can occur through enhanced osteoinduction, osteoconduction-in this case guaranteed by the porous ceramic matrix of the cranial implant, and osteogenesis — Thanks to the differentiation of the osteoblast and/or mesenchymal stem cells surrounding the prosthesis. Obviously, the benefits of platelet gel are only expected during the initial weeks or months after implantation, that is, until osteointegration is complete. Although we are not currently in a position to make a direct comparison between osteoinduction rates with and without platelet gel application-which would require extensive (and unethical) histological testing-we can state that our preliminary data from histological samples taken 4 years after implantation without platelet gel show signs of bone regeneration, even at some centimeters distant from the HA/bone interface, but that these are patchy and not uniformly distributed.<sup>[3]</sup> It will be interesting to see what similar tests on patients recently treated with the platelet gel will reveal in the years to come.

For the moment, however, we can only rely on our CT data to attest to the good biomimetism of the HA scaffold in the presence of the gel. Cranial CT (bone viewing window) is a simple yet effective way of assessing prosthesis osteointegration, although operator expertise is indispensable, as the apparent degree of remodeling can change with the viewing window. Although CT is sufficient for clinical purposes, it would be interesting to see whether a similar study using Tc-99m methylene diphosphonate three-phase bone imaging, by highlighting the metabolically active and growing areas of bone, would confirm these observations, and indeed, any acceleration in regeneration ascribable to the platelet gel.

Obviously, considering the nature of the procedure itself, the number of variables in play when dealing with inter-individual comparison makes it virtually impossible to get an accurate assessment of whether platelet gel has a statistically significant influence on the speed of HA osteointegration, especially at the small sample sizes available to us as surgeons. However, we can report observational data from our series regarding the two strategies used within the same patients, a much more

meaningful comparison in our eyes. As shown in the cranial CT image series (at T0, T1 and T2) in Figure 4, attachment was much improved in the frontal area, where platelet gel mixed with hydroxyapatite granules was applied, with respect to the occipital area, where the implant was fitted in direct contact with the bone.

In view of these promising results, we are currently refining our strategy, designing a special kit for producing autologous platelet concentrate in the operating theatre during surgery. By harnessing the potential of the stem cells from the patient's bone marrow (normally from the top of the iliac crest), it will no longer be necessary to take blood before the operation. The idea is to produce an end product consisting hematopoietic stem cells, mesenchymal cells, vascular progenitor cells, immune cells, and platelets. This product is likely to be superior, as stem or stromal cells from the bone marrow produce chondrocytes, osteoblasts, adipocytes, myoblasts, and an endothelial cell precursor, in relation to the tissue environment in question, and may thereby induce repopulation of the bone graft.<sup>[3]</sup>

Meanwhile, however, we also show the regeneration potential of the cranioplasty can be further enhanced by layering a dermal matrix between the implant and scalp to improve healing and reconstruction of the latter. This could be particularly helpful where skin is thin, damaged or scarred, and therefore poorly vascularized and susceptible to complications. In cranioplasty patients, these complications include cutaneous necrosis, laceration with exposure of the underlying implant, and an increased risk of infection. Thanks to its histoconductive and histoinductive properties, dermal matrix not only functions as a scaffold to support the generation of new tissue, it also attracts cells toward it, as in the embryonic histogenesis.<sup>[3,20]</sup> The INTEGRA® dermal matrix employed in this case contains hyaluronic acid dermatan sulfate, keratan sulfate, and heparan sulfate to promote cell differentiation and tissue regeneration, in addition to chondroitin sulfate, a key component of the extracellular matrix.

Studies have shown that this preparation promotes cellular aggregation within 17 days, when poorly organized syncytial clusters of 10-12 cells featuring large embryonal cells and new collagen are visible. To form viable tissue, these cells rely on the nutrients and oxygen from the vascular bed, and to compete with other such clusters promote angiogenic factors (first and foremost

vascular endothelial growth factor) in order to increase their supply. This causes hypertrophism of the existing local blood vessels and angiocytes, endothelial cells, and other perivascular cells begin to multiply and migrate to create a physical link to a nearby vessel. Once connected the spaces between the cells in the clusters begin to fill with fibrous tissue, which forms a dense collagen mesh capable of trapping syncytial cells and to all intents and purposes, transforming them into fibroblasts.<sup>[3,21-23]</sup>

By improving skin coverage of the cranial implant, the dermal matrix is also likely to improve aesthetic recovery, as well as promoting cell growth and regeneration of thin skin coverage. It may likewise improve skin laceration resistance and may reduce the need to resort to surgical flaps or skin grafts, thereby reducing time, costs, and donor site morbidity. In theory, the vascularization that enhances should also promote the invasion of the organic matrix into the pores of the HA implant, thereby supporting its osteoconduction and osteointegration through better blood supply. Indeed, the MRI we took before and a few months after cranioplasty with HA implant and a small sheet of dermal matrix show a marked difference in thickness between the two, with the posttreatment skin layer also appearing more uniform, alongside the improved trophism. Indeed, our MRI results were very encouraging in this regard, revealing good biomimetism of the HA scaffold and dermal regeneration (in terms of skin thickness and vascularization) in just a few short weeks.

Before summing up, it is important to note that optimization of results was only possible due to the combined efforts of our multidisciplinary team. In particular, the surgery itself relied on equal participation by the maxillofacial surgeon, plastic surgeon, and neurosurgeon.<sup>[24]</sup> Indeed, the vary nature of the cranial-cephalic area means that results cannot be optimized without the overlapping of various specialties.

## CONCLUSIONS

Our preliminary study shows encouraging signs that platelet gel and dermal matrix may be used alongside HA implants to good result in cranioplasty patients, with a view to accelerating bone remodeling — Thereby guaranteeing better implant stability and resistance — and enhancing dermal regeneration — Thereby improving esthetic and clinical outcomes. Although

further investigation is needed to expand this avenue of exploration, it is plausible that such a strategy may reduce the burden associated with autologous grafts and/or implant fracture on both the patient and the health service.

## REFERENCES

1. ISMETT: Rigenerazione ossea, accordo Palermo-Genova-Pittsburgh. Available from: <http://www.ismett.edu/?q=it/node/532>. [Last cited on 2012 Feb 20].
2. Rogers GF, Greene AK, Mulliken JB, Proctor MR, Ridgway EB. Exchange cranioplasty using autologous calvarial particulate bone graft effectively repairs large cranial defects. *Plast Reconstr Surg* 2011;127:1631-42.
3. Zanotti B, Verlicchi A, Parodi PC, editors. Cranial Demolition and Reconstruction. One-Step Surgical Procedure. Topics in Medicine. Special Issue 1-4. Trento: New Magazine Edizioni. 2010. p. 16.
4. Grant GA, Jolley M, Ellenbogen RG, Roberts TS, Gruss JR, Loeser JD. Failure of autologous bone-assisted cranioplasty following decompressive craniectomy in children and adolescents. *J Neurosurg* 2004;100:163-8.
5. Van Havenbergh T, Berghmans D, De Smedt K, Arcangeli E, Nataloni A: "One Step" neuronavigated cranial vault tumor resection and porous hydroxyapatite custom made prosthesis reconstruction: A case report. In: Editors: A. Ravaioli, A. Krajewski. Ceramic, cell and tissues. Consiglio Nazionale delle Ricerche: Annual Conferences, Faenza, October, 2-5, 2007.
6. Nataloni A, Martinetti R, Servadei F, Staffa G, Piconi C. Porous Hydroxyapatite Custom Made for Cranioplasty: Two Yeras of Clinical Experience. Vol. 12. Proceedings of 13<sup>th</sup> International Symposium on Ceramics in Medicina. Bologna; 2000. p. 881-4.
7. Meel BL. Fatal systemic allergic reaction following acrylic cranioplasty: A case report. *J Clin Forensic Med* 2004;11:205-7.
8. Hettige S, Norris JS. Mortality after local allergic response to titanium cranioplasty. *Acta Neurochir (Wien)* 2012;154:1725-6.
9. Stefani R, Esposito G, Zanotti B, Iaccarino C, Fontanella MM, Servadei F. Use of "custom made" porous hydroxyapatite implants for cranioplasty: Postoperative analysis of complications in 1549 patients. *Surg Neurol Int* 2013;4:12.
10. Holmes RE, Hagler HK. Porous hydroxyapatite as a bone graft substitute in cranial reconstruction: A histometric study. *Plast Reconstr Surg* 1988;81:662-71.
11. Tampieri A, Celotti G, Sprio S, Delcogliano A, Franzese S. Porosity-graded hydroxyapatite ceramics to replace natural bone. *Biomaterials* 2001;22:1365-70.
12. Fabbri A, Nataloni A, Celotti G, Ravaglioli A. Production and characterization of hydroxyapatitebased porous bodies for medical applications. *Fourt Eur Ceram* 1995;8:109-16.
13. Descamps M, Richart O, Hardouin P, Hornez JC, Leriche A. Synthesis of macroporous b-tricalcium phosphate with controlled porous architectural. *Ceram Int* 2008;34:1131-7.
14. Saha S, Pal S. Mechanical properties of bone cement: A review. *J Biomed Mater Res* 1984;18:435-62.
15. Zanotti B, Verlicchi A, Almesberger D, De Franceschi D, Guarneri GF, Rampino Cordaro E, *et al.* Cranioplastiche custom made: Appunti di lavoro. In: Zanotti B, Verlicchi A, Parodi PC, editors. Cranioplastica Terapeutica. Trento: New Magazine Edizioni; 2013. p. 47-56.
16. Manes E, Manes C, Cantò L, Erasmo R. Stem cells and growth factors in orthopaedics and traumatology. *GIOT* 2005;31:197-205.

17. Plachokova AS, van den Dolder J, van den Beucken JJ, Jansen JA. Bone regenerative properties of rat, goat and human platelet-rich plasma. *Int J Oral Maxillofac Surg* 2009;38:861-9.
18. Marx RE, Carlos EC, Eichstaedt RM, Schimmele SR, Strauss JE, Georgeff KR. Growth factor enhancement for bone grafts. *Oral Maxillofac Surg* 1998;85:638-46.
19. Butcher A, Milner R, Ellis K, Watson JT, Horner A. Interaction of platelet-rich concentrate with bone graft materials: An *in vitro* study. *J Orthop Trauma* 2009;23:195-200.
20. Cordaro ER, Calabrese S, Faini GP, Zanotti B, Verlicchi A, Parodi PC. Method to thicken the scalp in calvarian reconstruction. *J Craniofac Surg* 2011;22:598-601.
21. Gottlieb ME. Modeling blood vessels: A deterministic method with fractal structure based on physiological rules. *Proceedings 12<sup>th</sup> International Meeting IEEE Engineering Medicine Biology Society*; 1990.
22. Campitiello E, Della Corte A, Fattopace A, D'Acunzi D, Canonico S. The use of artificial dermis in the treatment of chronic and acute wounds: Regeneration of dermis and wound healing. *Acta Biomed* 2005;76 Suppl 1:69-71.
23. Moiemens NS, Vlachou E, Staiano JJ, Thaw Y, Frame JD. Reconstructive surgery with INTEGRA® dermal regeneration template: Histologic study, clinical evaluation, and current practice. *Plast Reconstr Surg* 2006;117:160S-74.
24. Riberti C, Rampino Cordaro E, Parodi PC, Guarneri GF, De Biasio F. The collaboration between neurosurgeon and plastic surgeon: The usefulness of a multidisciplinary approach. *Riv Med* 2005;11:161-3.

**How to cite this article:** Zanotti B, Zingaretti N, Almesberger D, Verlicchi A, Stefani R, Ragonese M, *et al.* Enhancing dermal and bone regeneration in calvarial defect surgery. *Indian J Plast Surg* 2014;47:325-32.

**Source of Support:** Nil, **Conflict of Interest:** None declared.

#### Announcement

### “QUICK RESPONSE CODE” LINK FOR FULL TEXT ARTICLES

The journal issue has a unique new feature for reaching to the journal's website without typing a single letter. Each article on its first page has a "Quick Response Code". Using any mobile or other hand-held device with camera and GPRS/other internet source, one can reach to the full text of that particular article on the journal's website. Start a QR-code reading software (see list of free applications from <http://tinyurl.com/yzlh2tc>) and point the camera to the QR-code printed in the journal. It will automatically take you to the HTML full text of that article. One can also use a desktop or laptop with web camera for similar functionality. See <http://tinyurl.com/2bw7fn3> or <http://tinyurl.com/3ysr3me> for the free applications.