

## Original Article

# Post-burn axillary contracture: A therapeutic challenge!

Durga Karki, Nikhil Mehta, Ravi Prakash Narayan

Department of Burns and Plastic Surgery, VMMC and Safdarjung Hospital, New Delhi, India

**Address for correspondence:** Dr. Nikhil Mehta, Department of Burns and Plastic Surgery, VMMC and Safdarjung Hospital, New Delhi, India.  
E-mail: theforgottensword@gmail.com

### ABSTRACT

**Background:** Axillary post-burn scar contracture is a challenging problem to the reconstructive surgeon owing to the wide range of abduction that should be achieved. The aim of this paper was to highlight the various options used in managing axillary contractures in our hospital. **Materials and Methods:** This is a retrospective hospital-based study of axillary contractures managed at Safdarjung Hospital (a tertiary care hospital) from 2009 to 2013. The study consisted of 44 patients from all age group and both sex included in it. Patients with a bilateral axillary contracture were excluded. Axillary contracture was released and resurfaced using split skin graft and/or with different types of flaps including the propeller flap, parascapular flap. All the reconstructed cases were followed-up for a period of 12 months. Assessment was done on the basis of functional and aesthetic outcome. **Results:** Forty-four patients consisting of 25 males and 19 females presented with axillary contractures that involved 44 axillae. The mean age of the study group was 17.1 years. Injuries involved the anterior axillary fold in 8 (18.18%), posterior fold in ten (22.72%), both folds and axillary fossa in 14 (31.81%) and both folds plus part of the chest wall and arm (sparing the axillary fossa) in 12 (27.27%) axillae. Surgical treatment included split-thickness skin graft in 15 (34.1%), local skin flaps in 4 (9.1%), Z-plasties in 4 (9.1%), parascapular flaps in 3 (6.82%), while propeller flaps in 12 (27.27%) and square flap were used in 6 (13.64%) patients. The percentage of improvement in abduction had a mean of 156°. The functional and aesthetic results were satisfactory. **Conclusion:** The choice of surgical procedure for reconstruction of post-burn axillary contractures can be made according to the pattern of scar contracture and the state of the surrounding skin. The choice of a flap should have priority over the skin graft because of the superior functional and aesthetic results of flaps.

### KEY WORDS

Axillary contracture; propeller flap; square flap

### INTRODUCTION

In a developing country like India, the estimated annual burn incidence is approximately 6-7 million every year.<sup>[1]</sup> The high incidence is attributed to illiteracy, poverty and low level of safety consciousness in the population. The incidence of upper extremity burns constitutes a major chunk amongst them. In their natural course; burns of the upper extremity can lead to debilitating post-burn contractures, especially those involving the axillae, causing

Access this article online	
Quick Response Code:	Website: www.ijps.org
	DOI: 10.4103/0970-0358.146594

severe functional impairment and difficulty in shoulder abduction, due to the contractile evolution of scar.

According to Kurtzman and Stern, axillary contractures are classified into three categories [Table 1].<sup>[2]</sup>

Axillary contractures can be prevented by early prophylactic splinting and active exercises. But once formed surgical correction is the only option. The goal of surgical correction should be to provide the maximum release encompassing the entire axis of rotation of the shoulder to facilitate complete range of motion with minimum or no local anatomic distortion. In addition to the scarring of the fold(s), there are two local anatomic conditions that must be taken into consideration when surgical correction is contemplated. They are:

1. The extent of scarring of the adjacent skin and,
2. The involvement of the hair-bearing area of the axilla.

It is unusual for the hair-bearing area to be involved in thermal injury due to its anatomic location and because in most instances, the upper extremities are maintained in adduction, protecting the axillary hair-bearing area.<sup>[3]</sup>

A variety of reconstructive methods has been reported for treatment of axillary contractures including release and skin grafting; Z-plasty; local random flaps; island flaps; free flaps; tissue expanders.<sup>[4]</sup>

Once surgical correction is indicated, the choice of the procedure must be individualised in order to achieve this goal. In this paper, we present our surgical approach in the reconstruction of post-burn axillary scar contractures in a tertiary care centre.

**MATERIALS AND METHODS**

The study was conducted in the Department of Burns and Plastic Surgery at Safdarjung Hospital between 2009 and 2013. Patients of all age groups and both sexes were included in the study. Patients with involvement of both axillae were excluded from the study group. Forty-four patients with post-burn deformities of the axilla were treated.

**Pre-operative assessment**

Patient’s demographic data along with the history of contracture were taken. Local examination was done to note the degree of contracture; site involved and condition of the surrounding skin. Pre- and post-operative photographs were taken.

Operative procedures opted are mentioned in Table 2.

**Post-operative care**

Splinting was done post-operatively for a period varying from 1 to 3 weeks. In cases where release of contracture followed by skin grafting was done, continuous splinting was given for a period of 6 weeks and night splinting continued for a period of 6 months.

Follow-up visits were scheduled till a period of 1-year. Photographic assessment was done at various stages of healing post-operatively. Patients were asked to grade the aesthetic outcome of surgery according to Global Aesthetic Improvement Score [Table 3].

Following are the few cases to highlight the various operative procedures used:

- Case 1: A 17-year-old boy with Type 3 contracture of 5 years duration and abduction of 20° was treated with local flaps. A good improvement with 170° abduction was noted [Figure 1].

**Table 1: Kurtzman and stern classification of axillary contractures**

Classification	Description
Type 1A	Injuries involving anterior axillary fold
Type 1B	Injuries involving posterior axillary fold
Type 2	Injuries involving both anterior and posterior axillary folds (sparing axillary dome)
Type 3	Injuries Type 2 plus axillary dome

**Table 2: Operative procedures used with indications and patient details**

Procedure	Indication	Number of patients
Z-plasty	Linear scar contractures of anterior or posterior axillary folds if the surrounding skin was healthy	4
Square flaps	Linear scar contractures to attain more lengthening as compared to Z-plasty	6
Random pattern local skin flaps	Localised moderate bands of contractures anterior or posterior axillary folds; provided the donor site was not scarred	4
Release and skin grafting	Severe axillary contractures; if the surrounding skin was scarred and was not available for any local or fasciocutaneous flaps that could cover the resultant defect	15
Parascapular flaps	Severe axillary contractures with sparing of posterior chest wall	3
Propeller flaps	Axillary fossa was spared	12

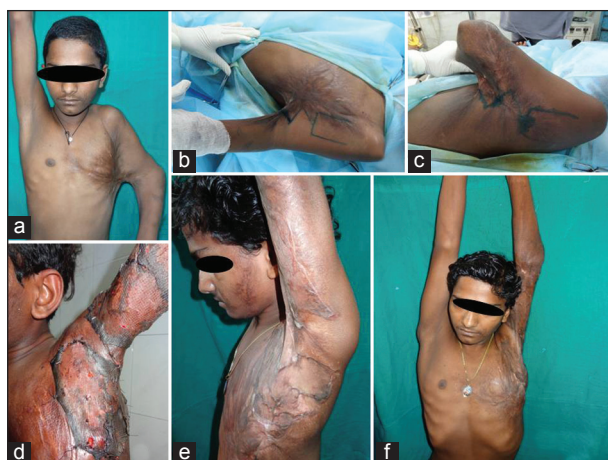- Case 2: An 8-year-old child with Type 1B contracture of 4 years duration with 70° abduction was operated with square flap method which led to increase in the angle of abduction to 180° [Figure 2].
- Case 3: A 28-year-old female patient with a Type 2 contracture with involvement of anterior and posterior axillary folds and sparing of axillary fossae was treated with a propeller flap. The degree of abduction improved from 40° to 160° [Figure 3].
- Case 4: A 22-year-old male patient with Type 1B contracture involving posterior axillary fold and a pre-operative degree of abduction of 70° was treated with square flap method. The resultant increase in angle of abduction was 160° [Figure 4].

## RESULTS

Forty-four patients including 25 males (56.82%) and 19 females (43.18%) with the post-burn axillary

**Table 3: Global assessment improvement score**

Rating	Description
Very much improved	Optimal cosmetic result for the implant in this patient
Much improved	Marked improvement in appearance from the initial condition, but not completely optimal for this patient. A touch-up will slightly improve the result
Improved	Obvious improvement in appearance from the initial condition, but a touch up or re-treatment is indicated
No change	The appearance is essentially the same as the original condition
Worse	The appearance is worse than the original condition



**Figure 1:** Type 3 contracture treated with local flaps. (a) Pre-operative photograph of the patient, with only 20° abduction. (b and c) Intra-operative flap markings with flaps being raised from anterior and posterior adjacent healthy skin. (d) 1-week post-operatively. (e) 6-month post-operatively. (f) 1-year post-operatively; increase in the degree of abduction to 170°

contracture were taken up for the study. Demographic details are mentioned in Table 4. Most common cause of burn was thermal injury. Scalds were seen less often; mainly in the paediatric population. None of the patients had undergone initial splinting or physiotherapy.

Patient distribution according to the classification of the axillary contracture given by Kurtzman and Stern has been shown in Table 4.

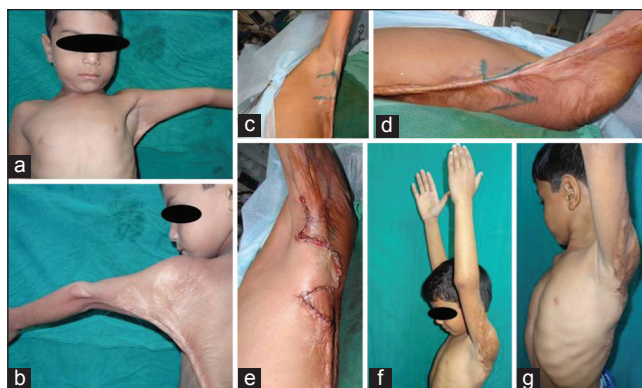Pre-op degree of abduction ranged from 20° to 100° with a mean degree of abduction being 48°. The procedure opted, and their results are compiled in Table 5.

The degree of abduction obtained 1-month post-operative ranged between 100 and 180° with a mean degree of abduction being 156°. Minor complications in the form of tip necrosis and partial graft loss were seen in 18.8% cases [Table 5].

Functional results were satisfactory in all the procedures done. Aesthetic results as assessed by patients are mentioned in Table 6. Figures 1-4 shows some of the cases included in the study; including pre-operative, intra-operative and post-operative photographs.

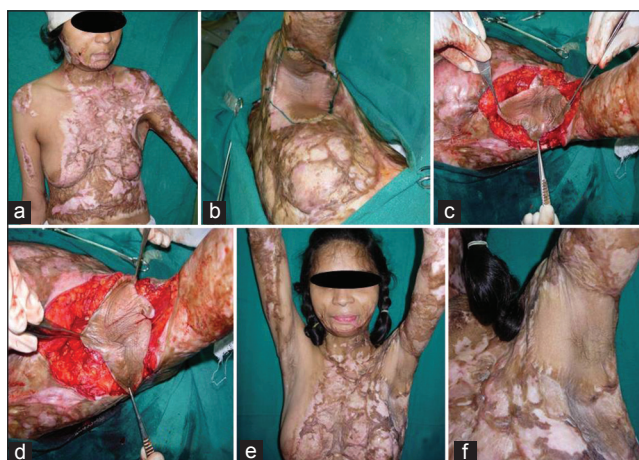
## DISCUSSION

Rehabilitation of axillary contractures is a challenge for reconstructive surgeons. Difficulty in management arises due to joint stiffness, difficulty in splinting and a high



**Figure 2:** Type 1B contracture treated with square flap method. (a and b) Pre-operative photographs of patient showing scarring of posterior axillary fold and an abduction of 70°. (c and d) Intra-operative flap markings. (e) Immediately post-operative photograph. (f and g) 1-year post-operative; increase in the degree of abduction to 180°





**Figure 3:** Type 2 contracture (with sparing of axillary dome) treated with a propeller flap. (a) Pre-operative photograph showing severe debilitation in abduction; limited to 40°. (b) Intra-operative flap markings. (c) Propeller flap raised over a subcutaneous pedicle. (d) Propeller flap rotated to 90° for its final placement. (e) 1-year post-operative photograph showing increase in abduction to 160°. (f) 1-year post-operative photograph showing spreading of flap to scarred area with maintenance of the hair-bearing region in the centre

**Table 4: Demographic details of patients included in the study**

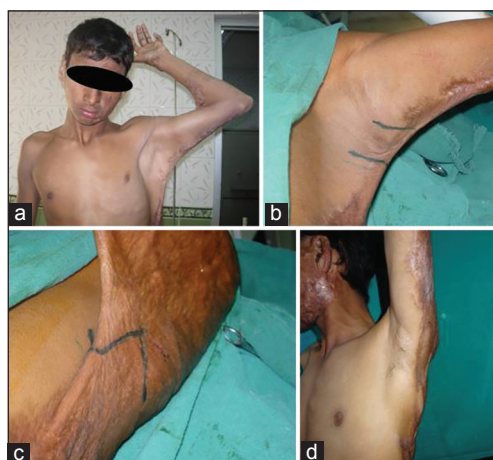Patient characteristics	Number of patients
Number of patients	44
Male:female ratio	25:9 (1.32:1)
Age range	6-30 years
Mean age	17.1 years
Duration of contracture	1-5.5 years
Mean duration	28 months
Right:left axilla	16:28 (1:1.8)
Patient distribution according to Kurtzamm classification (%)	
Type 1A	8 (18.18)
Type 1B	10 (22.72)
Type 2	12 (27.27)
Type 3	14 (31.8)

recurrence rate with inadequate care. The cutaneous gliding capacity of the shoulder area skin is important. Full abduction stretches both anterior and posterior folds of the axilla, and there is upward movement of the skin covering the lateral aspect of the trunk. Treating axillary contractures should replace these gliding possibilities.<sup>[5]</sup>

Operative procedures available for axillary contractures include:

### Z-plasty

This is the procedure of choice for linear scar contractures of the anterior or posterior axillary folds if the surrounding skin is healthy. The technique is based on transposition of two triangular flaps. The incisions are designed to create a Z shape with central limb aligned with the part of the scar that needs lengthening. A 60° Z-plasty causes



**Figure 4:** Type 1B contracture treated with square method flap. (a) Pre-operative photograph of the patient. (b and c) Intra-operative marking of the square flap and two triangular flaps. (d) Post-operative improvement showing increase in the degree of abduction to 160°

75% lengthening of central limb.<sup>[6]</sup> Multiple Z-plasties can be used for long linear scars while single Z-plasty is done for a short web.

### Square flap

Square flap method was proposed by Hyakusoku *et al.* in 1985,<sup>[7]</sup> a modification of the method described by Limberg in 1963.<sup>[8]</sup> It can be called a three flap Z-plasty. The method is an advancement transposition technique which consists of two triangular flaps (transposed) and a square flap (advanced). If the tip of one triangular flap is a right angle, it gives better lengthening, better advancement of the square flap and avoids the suture lines running parallel to the direction of lengthening. When the angle of the T-flap is 45° and of the U-flap 90°, as proposed by Hyakusoku *et al.*, there will be an increase of 2.80 times the original length after transposition of the flaps. This is better than that achieved by the other methods.<sup>[7]</sup>

### Random pattern local skin flaps

Flaps from the arm, anterior chest, axilla, or back of the chest are chosen for cases of localised moderate band of contractures of anterior or posterior axillary folds, provided that the donor site is not scarred. The donor sites of the flaps are covered with split-thickness skin graft.

### Release and skin grafting

Split-thickness skin grafting is performed after release of contractures of the axilla involving one or both axillary folds. This operation is done if the surrounding skin is

**Table 5: Pre- and post-operative results and complications of procedures done**

Procedure	Number of patients (%)	Preoperative degree of abduction	Post-operative degree of abduction	Percentage improvement	Complications
Z-plasty	4 (9.1)	60°	173°	188.33	Tip necrosis in 2 patients
Square flap	6 (13.64)	54°	172°	218.52	Tip necrosis in 1 patients
Local random flap	4 (9.1)	48°	152°	216.67	Nil
Release and skin grafting	15 (34.1)	43°	108°	151.16	Partial graft loss in 5 patients Recontracture in 2 patients at 1-year
Parascapular flap	3 (6.82)	50°	160°	220	Nil
Propeller flap	12 (27.27)	42°	168°	300	Nil

**Table 6: Aesthetic outcome as assessed by patients**

Improvement score	Number of patients
Very much improved	10
Much improved	12
Improved	22
No change	0
Wo	0

flaps that can cover the resultant defect or if the defect is bigger than any available flap as in severe axillary contractures.

### Parascapular flap

These are fasciocutaneous flaps based on subscapular artery and its branches. This is a flap of choice to cover the defect after release of the axilla if the width of the defect is less than 8 cm provided that the parascapular area is not scarred. Donor site is closed directly after proper undermining. Parascapular flaps have the advantage of being thin flaps which make it ideal for the reconstruction of axilla.

### Propeller flap

A propeller flap can be defined as an "island flap that reaches the recipient site through an axial rotation."<sup>[9]</sup> The term "propeller flap" was introduced in 1991 by Hyakusoku *et al.* to describe an adipocutaneous flap, based on a random subcutaneous pedicle, with a skin island of a length largely exceeding its width, made of two portions (the blades of the propeller), one at either side of the pedicle.<sup>[10]</sup> The flap is rotated 90° on the central pedicle, like a propeller, to resurface burn scar contractures at the axilla.

Our study included 44 patients amongst which maximum patients had axillary dome involvement (Type 3 = 14) followed by involvement of both anterior and posterior axillary folds (Type 2 = 12). The pre-operative degree of abduction ranged from 42° to 60° with mean of 49.5°. The choice of the operative procedure was made according to the site involved, severity of the

contracture and the state of surrounding skin. The above mentioned procedures were opted. The range of abduction increased post-operatively to 100-180° with a mean of 156°.

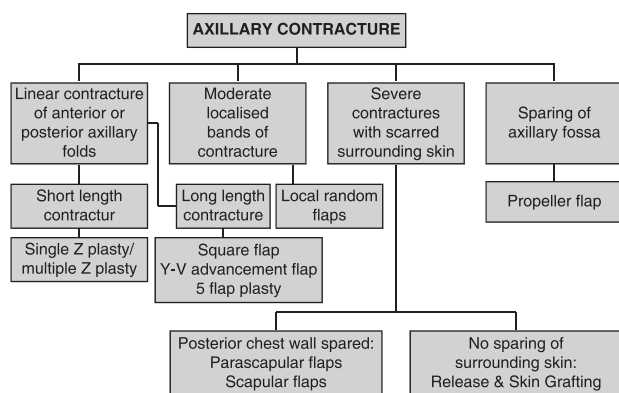
Z-plasties or local flaps such as transposition or advancement flaps, usually, can be used in linear scar contractures at the axillary folds, but they are not effective in severe axillary contractures or scarred adjacent tissue.<sup>[11]</sup> We used Z-plasty and square flap method for mild to moderate contractures involving either of the axillary folds. The percentage of improvement in the abduction at axilla noted in these two methods was 188.33% and 218.52%, respectively.

Fasciocutaneous flaps from the back such as scapular and parascapular flaps have been used for the treatment of obliterated axilla.<sup>[12]</sup> They have proved to be excellent for resurfacing large defects involving the axilla, and their donor sites can be closed primarily up to a 8 cm flap width. Parascapular flaps were used in our study group for severe contractures of the axillae with sparing of the posterior chest wall. The increment noted in post-operative abduction was 220%.

Propeller flaps were used in cases where axillary dome was spared. A subcutaneous pedicle flap with pedicle in the centre based on healthy skin spared in the region of the joint was raised and rotated to 90° to release the scar contracture. A substantial mean improvement of 300% was noted in these cases, along with sparing of hair-bearing axilla which gave aesthetically good results.

Comparing the mean pre-operative and post-operative degree of abduction; a fair improvement to the extent of 212% was noted in our study group.

Few studies have been done categorically for patients



**Flowchart:** Algorithm for management of post burn axillary contracture

Few studies have been done categorically for patients with post-burn axillary contractures worldwide. Sakr *et al.* performed surgeries in 20 patients of axillary contractures who had a mean burn contracture of 18 months. Mean degree of abduction pre-operatively was 60° which increased to 130°. [13] Complication seen in their study included tip necrosis, graft loss, wound infection, marginal flap necrosis.

Güven *et al.* studied 77 cases of upper extremity, neck and face contractures; out of which 19 had an axillary contracture. [14] The group used Z-plasty, K-plasty, thoracodorsal perforator flap and tissue expanders. They found excellent results with no complications.

Our study differs from the other study groups as we performed a large number of propeller flaps and square flap method with good success rate.

## CONCLUSION

Good shoulder movement is essential for day to day activity. Surgical intervention is aimed at obtaining good functional and aesthetic results and improving patients' self-esteem. Some of the factors to be considered in choosing the best option for a particular contracture include the type of contracture, the state of surrounding skin and the expertise of the surgeon. Despite the availability of numerous surgical options, flap cover gives

the best result with minimal or no flap loss and better range of joint movement and reduced recurrence rate. An algorithm as followed in our set up has been suggested in the Flowchart.

## REFERENCES

- Gupta JL, Makhija LK, Bajaj SP. National programme for prevention of burn injuries. *Indian J Plast Surg* 2010;43:S6-10.
- Kurtzman LC, Stern PJ. Upper extremity burn contractures. *Hand Clin* 1990;6:261-79.
- Hanumadass M, Kagan R, Matsuda T, Jayaram B. Classification and surgical correction of postburn axillary contractures. *J Trauma* 1986;26:236-40.
- Olaitan P, Onah I, Uduezue A, Duru N. Surgical options for axillary contractures. *Internet J Plast Surg* 2007;3:154-8.
- Teot L, Bosse JP. The use of scapular skin island flaps in the treatment of axillary postburn scar contractures. *Br J Plast Surg* 1994;47:108-11.
- Salam GA, Amin JP. The basic Z-plasty. *Am Fam Physician* 2003;67:2329-32.
- Hyakusoku H, Shirai H, Umeda T, Fumiiri M. The use of the square flap method for repair of axillary burn contracture. *Jpn J Plast Reconstr Surg* 1985;28:585.
- Limberg AA. *The Planning of Local Plastic Operations on the Body Surface: theory and Practice* (translated into English by Wolfe SA. 1984). Lexington: The Collamore Press. D. C. Heath and Co.; 1963.
- Pignatti M, Ogawa R, Hallock GG, Mateev M, Georgescu AV, Balakrishnan G, *et al.* The "Tokyo" consensus on propeller flaps. *Plast Reconstr Surg* 2011;127:716-22.
- Hyakusoku H, Yamamoto T, Fumiiri M. The propeller flap method. *Br J Plast Surg* 1991;44:53-4.
- Kim DY, Cho SY, Kim KS, Lee SY, Cho BH. Correction of axillary burn scar contracture with the thoracodorsal perforator-based cutaneous island flap. *Ann Plast Surg* 2000;44:181-7.
- Maruyama Y. Ascending scapular flap and its use for the treatment of axillary burn scar contracture. *Br J Plast Surg* 1991;44:97-101.
- Sakr WM, Mageed MA, Mo'ez WE, Ismail M. Options for treatment of post burn axillary deformities. *Egypt J Plast Reconstr Surg* 2007;31:63-71.
- Güven E, Ugurlu AM, Hocaoglu E, Kuvat SV, Elbey H. Treatment of post-burn upper extremity, neck and facial contractures: Report of 77 cases. *Ulus Travma Acil Cerrahi Derg* 2010;16:401-6.

**How to cite this article:** Karki D, Mehta N, Narayan RP. Post-burn axillary contracture: A therapeutic challenge!. *Indian J Plast Surg* 2014;47:375-80.

**Source of Support:** Nil, **Conflict of Interest:** None declared.