

Ideas and Innovations

Laser: The torch of freedom for ankyloglossia

Barot Varshal J., Vishnoi Shival L., Sarath Chandran, Bakutra Gaurav V.

Department of Periodontics and Implantology, Manubhai Patel Dental College and Hospital, Vadodara, Gujarat, India

Address for correspondence: Dr. Barot Varshal J, E-2/5, Professors Quarters' New Civil Hospital Campus, Majura Gate, Surat - 395 001, Gujarat, India. E-mail: varshalb@gmail.com

ABSTRACT

The tongue is an important oral structure that affects speech, position of teeth, periodontal tissues, nutrition, swallowing, nursing, and certain social activities. Ankyloglossia or tongue-tie, is a congenital anomaly characterized by an abnormally short lingual frenulum, which restricts mobility of the tongue. Though the ankyloglossia is not a serious condition, it may lead to a host of problems including infant feeding difficulties, speech disorders, and various mechanical and social issues related to the inability of the tongue to protrude. Hence, management of ankyloglossia should be considered at any age considering the risk-benefit evaluation. Tongue being highly vascular and mobile structure, laser-assisted lingual frenectomy is the simplest, safest and less traumatic of all the treatment modalities available, with most promising results in minimally invasive dentistry. Here, a case of ankyloglossia is reported with its management by diode laser.

KEY WORDS

Ankyloglossia; diode laser; lingual frenectomy; tongue-tie

INTRODUCTION

Frenum, a triangle-shaped fold of tissue connects the lip, tongue and buccal musculature to the alveolar bone in the oral cavity. It keeps a balance between the growing hard and soft tissues during the development of the foetus and limits the movement of the lip, tongue and cheeks.^[1] Ankyloglossia is a congenital anomaly characterized by the abnormal attachment of the lingual frenum. Etymologically, “ankyloglossia” originates from the Greek words “agkilos” (curved) and “glossa” (tongue). Wallace^[2] defined tongue-tie as “a condition in which the

tip of the tongue cannot be protruded beyond the lower incisor teeth because of a short frenulum linguae, often containing scar tissue.”

CASE REPORT

A 21-year-old healthy male patient reported with the complaint of difficulty in speech since childhood. Intraoral examination revealed partial ankyloglossia [Figures 1 and 2] and was classified as class II [Figure 3] according to Kotlow's classification. After the informed consent, lingual frenectomy was planned by using soft tissue diode laser.

Area was anesthetized by giving bilateral local infiltration in the lingual mucosa adjacent to the lingual frenum and into the substance of the tongue at the tip of the tongue. A traction suture was placed at the tip of the tongue [Figure 4], with which the tongue was firmly retracted.

| Access this article online | |
|---|----------------------------------|
| Quick Response Code: | Website: www.ijps.org |
|  | DOI: 10.4103/0970-0358.146630 |

Diode laser (810 nm) [Figure 5] was used for the frenectomy procedure. After stripping the fiber-optic wire tip, the tip was initiated by firing it into a piece of cork at 2 W in a continuous mode. An initiated tip of 200 μ m [Figure 6] was used with an average power of

2 W in a continuous mode. The diode laser was applied in a contact mode with focused beam for excision of the tissue [Figure 7]. The tip of the laser was moved from the apex of the frenum to the base in a brushing stroke cutting the frenum. The ablated tissue was continuously mopped using wet gauze piece. This takes care of the charred tissue and prevents excessive thermal damage to the underlying soft tissue [Figure 8]. No suturing was done, and the patient was prescribed with antibiotics, analgesics and warm saline rinses to facilitate faster healing.

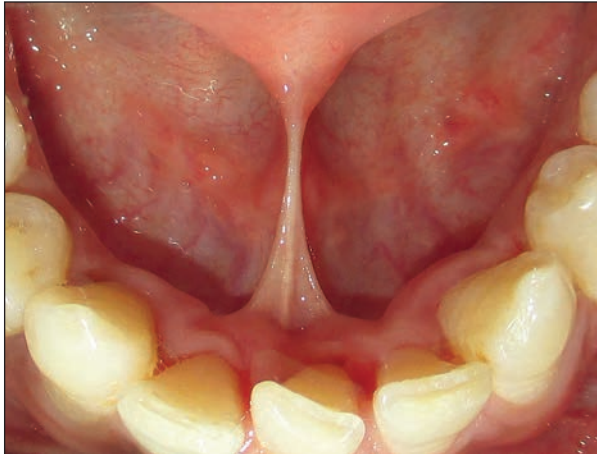


Figure 1: Ankyloglossia, occlusal view

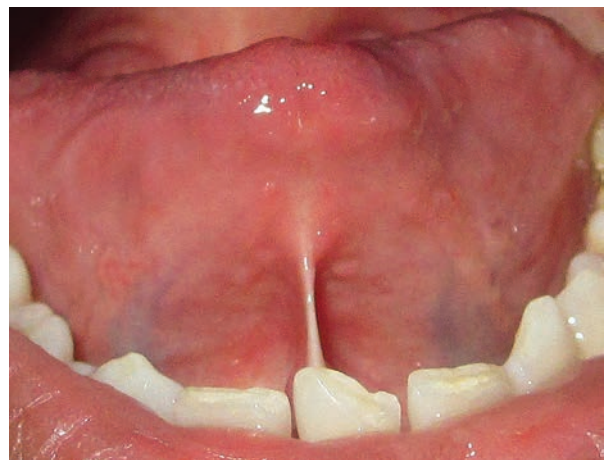

Figure 2: Ankyloglossia, front view

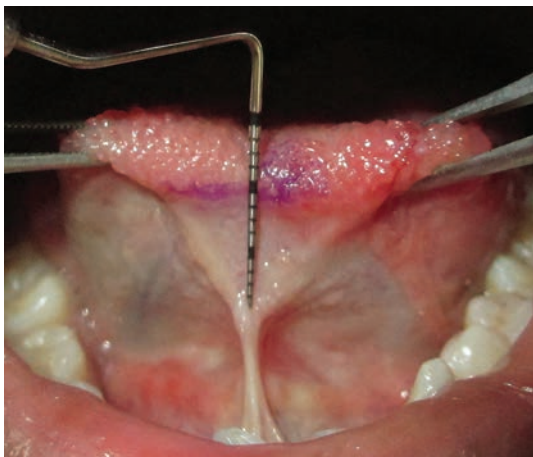


Figure 3: Kotlow's class II, moderate (10 mm) ankyloglossia

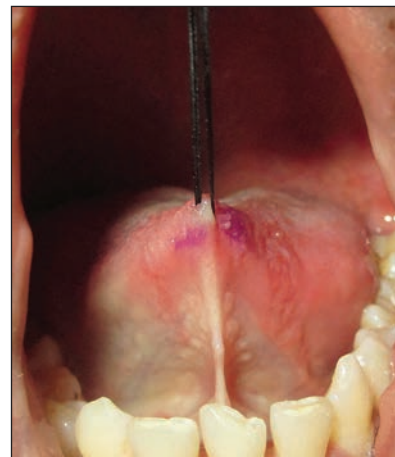


Figure 4: Traction suture at the tip of the tongue

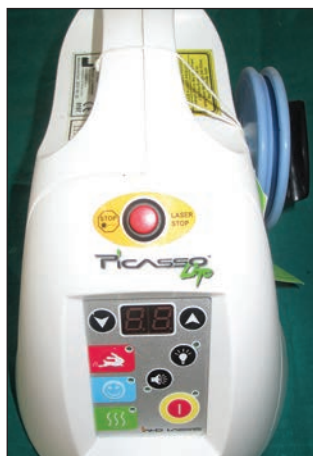

Figure 5: Diode laser unit (810 nm)



Figure 6: A fiber-optic wire tip of 200 μ m

Follow-up at 1-week showed uneventful healing in progress with “white soft scab” formation [Figure 9], and complete healing at 3 and 6 weeks [Figures 10-12] with increase in tongue mobility of ≥ 16 mm distance [Figure 13] between lingual frenum insertion and the tongue tip following laser surgery. Speech articulation was noticeably improved after the speech therapy.

DISCUSSION

Ankyloglossia represents a typical interdisciplinary problem concerning different specialties in dentistry, ranging from periodontists, pediatric dentists, to oral surgeons. It can be observed in neonates, children, or adults. Its prevalence varies from 0.1% to 10.7%,^[3,4] with slight male predilection. The exact etiopathogenesis is unknown, but genetic role with the possible involvement of human G-protein coupled receptor gene (*Lgr5*)^[5] have been suggested.

Based on the distance of the insertion of the lingual frenum to the tip of the tongue, Kotlow's classification^[6] of ankyloglossia is as follows:

1. Class I, mild ankyloglossia 12-16 mm;
2. Class II, moderate ankyloglossia 8-11 mm;
3. Class III, severe ankyloglossia 3-7 mm; and
4. Class IV, complete ankyloglossia <3 mm. In a tongue with normal function and range of movement, interincisal distance by maximal mouth opening, while maintaining contact of the tongue tip to the posterior surface of the upper central incisor teeth should be >30 mm.^[7]

A normal range of motion of the tongue is indicated by the following criteria:

1. The tip of the tongue should be able to protrude outside the mouth; without clefting,
2. The tip of the tongue should be able to sweep the upper and lower lips easily; without straining,

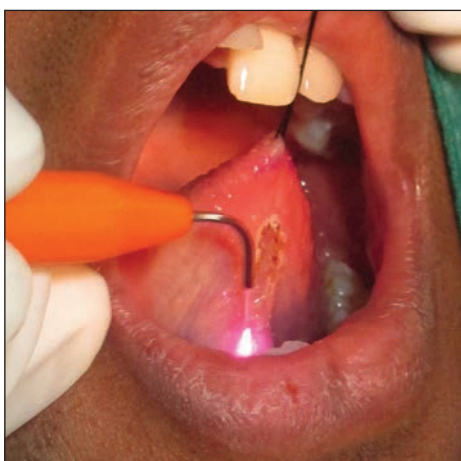

Figure 7: The laser tip initiated by firing; excision of the lingual frenum

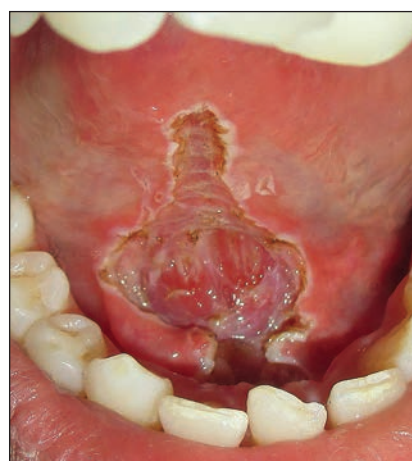


Figure 8: Immediately after the laser lingual frenectomy

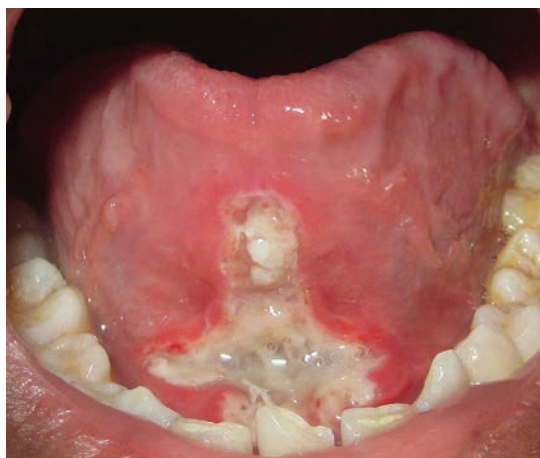

Figure 9: Post-treatment after 1-week showing “white soft scab” formation

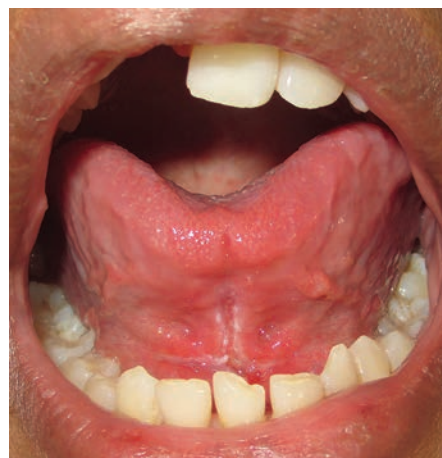

Figure 10: Post-treatment after 3 weeks with uneventful healing

3. When the tongue is retracted, it should not blanch the tissues lingual to the anterior teeth; and
4. The lingual frenum should not create a diastema between the mandibular central incisors.

The problems associated with mechanical limitation of tongue are difficulties in breast feeding among neonates, malocclusion, gingival recession, improper oral hygiene and speech difficulties in pronunciation of consonants like t, d, n, and l, and difficult to roll a “r.”

Therefore, management of ankyloglossia should be considered at any age depending on the patient’s history of speech, feeding, mechanical or social difficulties.

Treatment options include conventional surgical (scalpel) techniques (frenotomy, frenectomy, frenuloplasty) and lasers. Frenotomy is a simple incision of the frenulum. Frenectomy is defined as complete excision, that is, removal of the whole frenulum. Frenuloplasty involves various methods to release the tongue-tie and correct the anatomic situation. Complications after frenotomy, frenectomy, and frenuloplasty are rare. Disadvantages of conventional surgical frenectomies are bleeding, blockage of Wharton’s duct while suturing on the ventral surface of tongue leading to retention cyst, damage to the lingual nerve causing numbness of the tongue tip.

Diode lasers have several advantages when compared to conventional scalpel surgeries. They are compact and portable in design, with efficient and reliable benefits for use in soft tissue oral surgical procedure. Laser-assisted lingual frenectomy is easy to perform with excellent precision, less discomfort, minimal or no bleeding due to sealing of capillaries by protein denaturation and stimulation of clotting factor VII production, shortened healing time with reduced postoperative bleeding and oedema.^[8] Histologically, laser wounds have been found to contain significantly lower number of myofibroblasts,^[9] resulting in less wound contraction and scarring, and ultimately improved healing, with better postoperative perception of pain and function than with the scalpel technique.^[10]

CONCLUSION

Ankyloglossia is one of the most misdiagnosed and overlooked congenital abnormalities in the new born

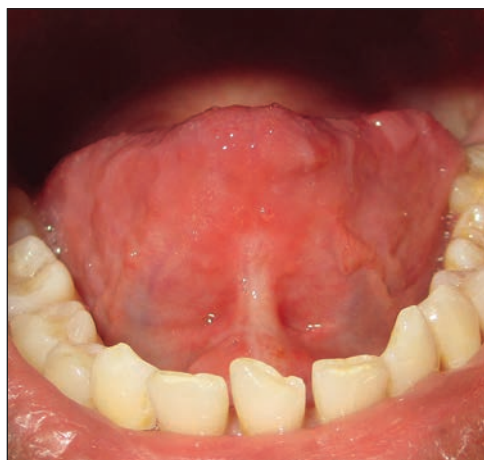

Figure 11: Post-treatment after 6 weeks with complete healing, front view

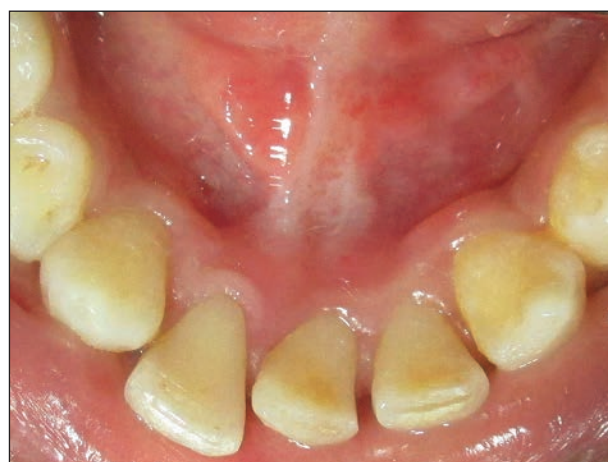

Figure 12: Post-treatment after 6 weeks with complete healing, occlusal view

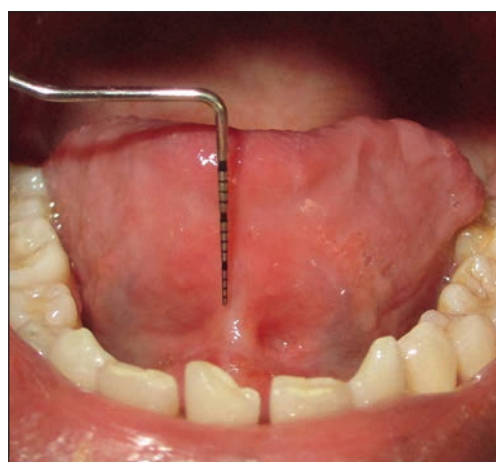


Figure 13: Post-treatment after 6 weeks, ≥ 16 mm distance between the lingual frenum insertion and tongue tip

population with prevalence rate of 3.2%,^[11] and if untreated can exert a harmful effect on many facets of life. Laser treatment being relatively simple and safe, patients could be benefited by the laser-assisted surgeries.

REFERENCES

1. Northcutt ME. The lingual frenum. *J Clin Orthod* 2009;43:557-65.
2. Wallace AF. Tongue tie. *Lancet* 1963;2:377-8.
3. García Pola MJ, González García M, García Martín JM, Gallas M, Seoane Lestón J. A study of pathology associated with short lingual frenum. *ASDC J Dent Child* 2002;69:59-62, 12.
4. Ballard JL, Auer CE, Khoury JC. Ankyloglossia: Assessment, incidence, and effect of frenuloplasty on the breastfeeding dyad. *Pediatrics* 2002;110:e63.
5. Acevedo AC, da Fonseca JA, Grinham J, Doudney K, Gomes RR, de Paula LM, *et al.* Autosomal-dominant ankyloglossia and tooth number anomalies. *J Dent Res* 2010;89:128-32.
6. Kotlow LA. Ankyloglossia (tongue-tie): A diagnostic and treatment quandary. *Quintessence Int* 1999;30:259-62.
7. Lalakea ML, Messner AH. Ankyloglossia: The adolescent and adult perspective. *Otolaryngol Head Neck Surg* 2003;128:746-52.
8. Pirnat S. Versality of an 810 nm diode laser in dentistry: An overview. *J Laser Health Acad* 2007;4:1-9.
9. Zeinoun T, Nammour S, Dourov N, Aftimos G, Luomanen M. Myofibroblasts in healing laser excision wounds. *Lasers Surg Med* 2001;28:74-9.
10. Haytac MC, Ozcelik O. Evaluation of patient perceptions after frenectomy operations: A comparison of carbon dioxide laser and scalpel techniques. *J Periodontol* 2006;77:1815-9.
11. Kotlow LA. Lasers in pediatric dentistry. *Dent Clin North Am* 2004;48:889-922, vii.

How to cite this article: Barot VJ, Vishnoi SL, Chandran S, Bakutra GV. Laser: The torch of freedom for ankyloglossia. *Indian J Plast Surg* 2014;47:418-22.

Source of Support: Nil, **Conflict of Interest:** None declared.

Staying in touch with the journal

1) Table of Contents (TOC) email alert

Receive an email alert containing the TOC when a new complete issue of the journal is made available online. To register for TOC alerts go to www.ijps.org/signup.asp.

2) RSS feeds

Really Simple Syndication (RSS) helps you to get alerts on new publication right on your desktop without going to the journal's website. You need a software (e.g. RSSReader, Feed Demon, FeedReader, My Yahoo!, NewsGator and NewzCrawler) to get advantage of this tool. RSS feeds can also be read through FireFox or Microsoft Outlook 2007. Once any of these small (and mostly free) software is installed, add www.ijps.org/rssfeed.asp as one of the feeds.