

## Case Report

# Giant rhinophyma: Excision with coblation assisted surgery

Caner Sahin, Mesut Turker<sup>1</sup>, Bulent Celasun<sup>2</sup>

Sakarya State Hospital ENT Clinic, Sakarya, <sup>1</sup>Lokman Hekim Hospital, Department of Plastic Surgery, Sincan, <sup>2</sup>Goren Pathology Lab, Ankara, Turkey

**Address for correspondence:** Dr. Caner Sahin, Beratevler No 19/1 Erenler, Sakarya, Turkey. E-mail: drcaner2001@gmail.com

### ABSTRACT

An 83-year-old man presented with an unusually severe case of rhinophyma. Giant rhinophyma is very rare in literature. The giant lesion was widely excised using sharp surgical incision and coblation assisted surgery. Using direct coblation to the nasal dorsum may cause edema in the surrounding tissue. There was minimal edema in surrounding tissue using this technique. A full thickness-skin graft was applied after excision. Cosmetic and functional postoperative results were satisfactory.

### KEY WORDS

Coblation; giant; rhinophyma

### INTRODUCTION

Rhinophyma is a rare disease characterized by progressive hypertrophy of the epidermal and dermal elements of nose. At the end of the disease a bullous, nodular hypertrophy of the nasal tip occurs.<sup>[1]</sup> Medical treatment is often inadequate. Surgical reduction is the mainstay treatment of the disease. Electrosurgery, laser ablation, dermabrasion, cryosurgery and surgical excision with the scalpel, radiosurgery, powered instrument surgery and coblation surgery are the surgical treatment options.<sup>[2-5]</sup>

Coblation (Artrocare) provides us to apply controlled, focused low heat dissection. The energized plasma

particules demolishes applied tissue at low temperatures (40-70°C). This coblation assisted dissection provides us haemostasis and minimal damage to neighbour tissue.<sup>[2]</sup> This advantage assures reduced risk formation of scar tissue and hypopigmentation.

### CASE REPORT

An 83-year-old man presented to the otolaryngology clinic complaining of nasal deformity [Figure 1]. The lesion had been present for several years, but the patient claimed growth of the mass over the previous year. The medical history revealed neither alcoholism nor any dermatological disease. On physical examination, there was a large, pedunculated, swollen, irregular mass measuring 9 cm × 8 cm, occupying the area at the tip and the dorsum of the nose. The remaining head and neck examination was normal.

The lesion was excised completely with sharp scalpel incision and coblation assisted dissection under general anaesthesia. We used Artrocare probe of coblation device designed for turbinate surgery [Figure 2]. The rhinophyma

Access this article online	
Quick Response Code: 	Website: www.ijps.org
	DOI: 10.4103/0970-0358.146663

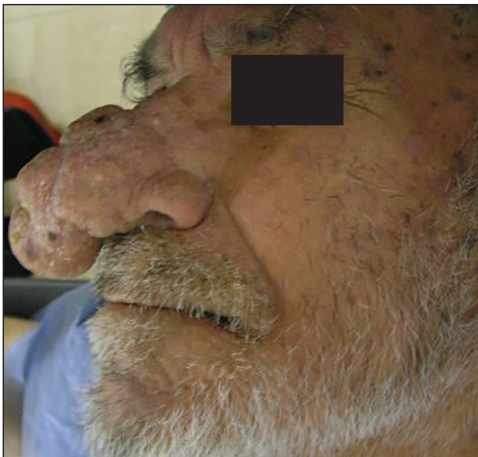was incised with 15 blade until the perichondrium of the nasal structure is reached. The perichondrium and periosteum of the osteo-cartilaginous framework were preserved. The settings of coblator are 6 for coblation and 3 for coagulation. The coblation provides both dissection and coagulation with minimum risk for scarring. Approximately 9 cm of diseased tissue is removed from dorsum the nose [Figure 3]. Reconstruction of the defect was performed with a full thickness-skin graft obtained from the upper arm [Figure 4]. No recurrence was seen during 1-year follow-up period [Figure 5].

On histopathological examination of the biopsy specimens, hyperkeratosis of the epidermis, increased sebaceous glands and cystic expansion of ducts in dermis was observed. Duct lumen was dilated and filled with keratin plugs. Fibrosis and chronic lymphoplasmocytic cell

infiltration were observed around the ducts. Neoplastic cells were not seen [Figure 6].

## DISCUSSION

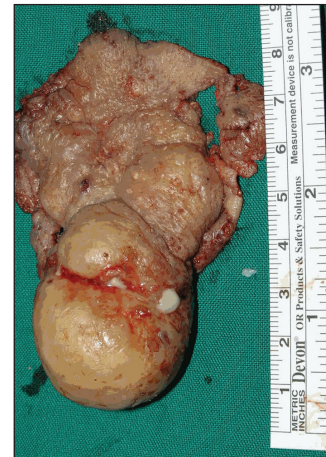Rhinophyma is a disease of progressive soft tissue hypertrophy of nasal tissue. The aetiology of the disease is unknown. Vitamin deficiency, chronic infection, androgenic hormones were accused for the disease.<sup>[2,3]</sup> There is male/female predilection (12/1),<sup>[3]</sup> Rhinophyma is usually occurs after 5<sup>th</sup> decade of life. The disease rarely shows malignant degeneration. There is 15-30 % simultaneous development of rhinophyma and carcinoma in literature.<sup>[6]</sup> The most common associated carcinoma is basal cell carcinoma.<sup>[6]</sup> In our case, there was no simultaneous carcinoma.



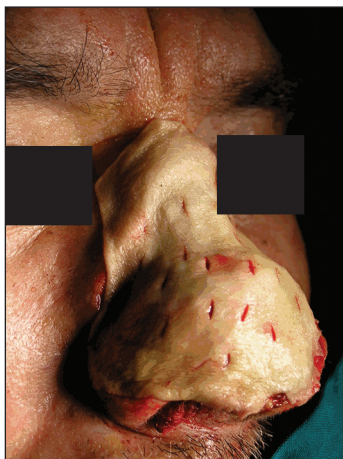**Figure 1:** The preoperative aspect of giant rhinophyma (was measured as an average of 9 cm) involving the caudal half of the nose



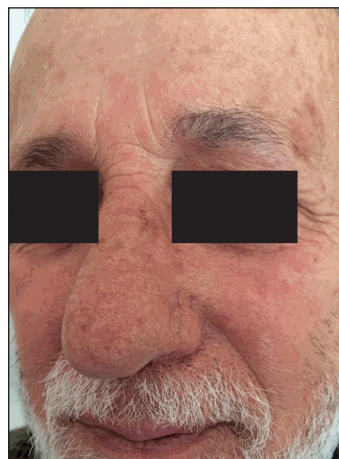
**Figure 2:** The artrocare probe used in surgery



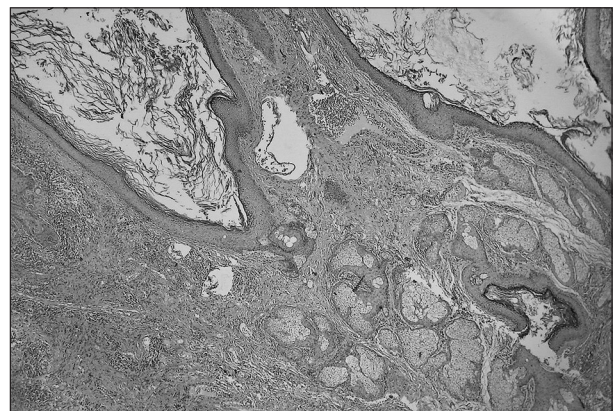
**Figure 3:** Exicion of rhinophyma from nasal dorsum



**Figure 4:** The intraoperative appearance of surgical treatment with full-thickness graft



**Figure 5:** The postoperative 1-year appearance of the patient



**Figure 6:** On histopathological examination, hyperkeratosis of the epidermis, increased sebaceous glands and cystic expansion of ducts in dermis were observed. Duct lumen is dilated and filled with keratin plugs. Fibrosis and chronic lenfoplazmositer cell infiltration around the ducts are observed. Neoplastic cells were not found (H and E, ×40)

The treatment of the disease mainly depends on the severity and extension of affected skin. The surgical resection can be made with CO<sub>2</sub> laser excision, scarpel excision, dermabrasion, excision with Weck razor, harmonic scalpel excision and electrocautery excision powered instrument surgery and the coblation surgery.<sup>[7-9]</sup>

Excision of the lesion preserving perichondrium and reconstruction with a full thickness graft provides a technically simple and effective method. Coblation dissection of the diseased tissue provides us controlled surgery and haemostasis in low temperatures. This provides us an advantage of minimal damage to adjacent perichondrium, skin and periosteum of the nasal dorsum. This advantage assures reduced risk formation of scar tissue and hypopigmentation of the nasal dorsum. There are few articles using this technique for this lesion. In some of them, the authors do not incise the skin with a blade and apply only coblation to the skin.<sup>[2,3,10]</sup> Using this kind of techniques can affect the heated adjacent skin.<sup>[10]</sup> There may be mild to moderate oedema of the adjacent tissue. In our case, there was no oedema of adjacent tissue. Various new techniques are described in the literature for treatment of rhinophyma and further studies are required to decide which one is the best.

## REFERENCES

1. Curnier A, Choudhary S. Rhinophyma: Dispelling the myths. *Plast Reconstr Surg* 2004;114:351-4.
2. Hetherington HE. Coblation-assisted decortication for the treatment of rhinophyma. *Laryngoscope* 2009;119:1082-4.
3. Bogetti P, Boltri M, Spagnoli G, Dolcet M. Surgical treatment of rhinophyma: A comparison of techniques. *Aesthetic Plast Surg* 2002;26:57-60.
4. Sadick H, Goepel B, Bersch C, Goessler U, Hoermann K, Riedel F. Rhinophyma: Diagnosis and treatment options for a disfiguring tumor of the nose. *Ann Plast Surg* 2008;61:114-20.
5. Garito J. Radiosurgery excision of rhinophyma. *Dermatol Surg* 2012;38:1760.
6. Lazzeri D, Colizzi L, Licata G, Pagnini D, Proietti A, Ali G, *et al.* Malignancies within rhinophyma: Report of three new cases and review of the literature. *Aesthetic Plast Surg* 2012;36:396-405.
7. Zide MF. Surgical removal of rhinophyma. *J Oral Maxillofac Surg* 2008;66:2168-77.
8. Somogyvári K, Battyáni Z, Móricz P, Gerlinger I. Radiosurgical excision of rhinophyma. *Dermatol Surg* 2011;37:684-7.
9. Faris C, Manjaly JG, Ismail-Koch H, Caldera S. Rapid treatment of rhinophyma with powered microdebrider. *Case Rep Otolaryngol* 2013;2013:621639.
10. Timms M, Roper A, Patrick C. Coblation of rhinophyma. *J Laryngol Otol* 2011;125:724-8.

**How to cite this article:** Sahin C, Turker M, Celasun B. Giant rhinophyma: Excision with coblation assisted surgery. *Indian J Plast Surg* 2014;47:450-2.

**Source of Support:** Nil, **Conflict of Interest:** None declared.