

Superiorly based V flap for inguinal soft tissue defect reconstruction

Sir,

Various reconstructive options are available for the soft tissue coverage over the inguinal region. We present a superiorly based “V” shaped flap, which provides stable soft tissue cover for femoral vessels, reduces the risk of wound dehiscence and lymphatic drainage problems, better tolerance to radiotherapy and decreased incidence of donor site morbidity.

Six patients with posttumour excision inguinal defects were operated for flap cover using the said technique over a period of 9 months from October 2012 to June 2013.

The vascularity of the flap is based on the excellent longitudinal network of vessels formed by the anastomoses

between branches of transverse branch of the lateral circumflex femoral and individual branches of profunda perforators, which emerge along the lateral intermuscular septum and fan out over the iliotibial tract [Figure 1].

As per requirements of the defect [Figure 2], a lateral “V” flap is planned [Figure 3] from the anterolateral aspect of the thigh, centered on the lateral intermuscular septum, with its base at the lateral end of the inguinal defect (usually at the level of the greater trochanter of femur) and the tip at distal end like a “V” shaped flap. Flap is raised from distal to proximal direction in the plane just superficial to the tensor fascia lata preserving as much of perforators to the flap from the lateral side. Then the medial flap, overlying the soft tissue of the anterior thigh, is elevated superficial to the deep fascia of the thigh. Now the two flaps are transposed as in a technique similar to “Z” plasty [Figure 4]. Hence, the “V” shaped flap will cover the inguinal defect; medial side flap mobility facilitates primary closure of the donor defect.

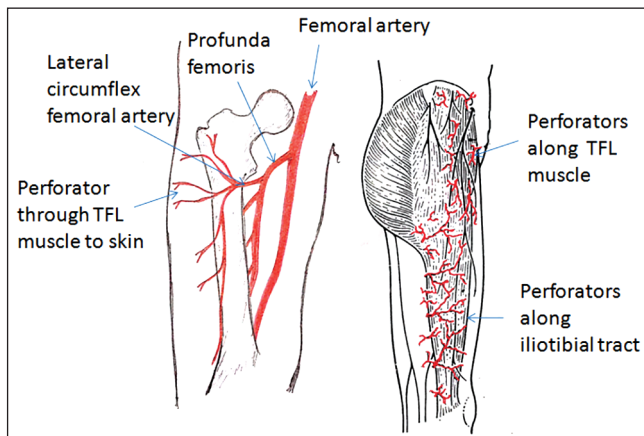


Figure 1: Anatomy of perforators through tensor fascia lata muscle

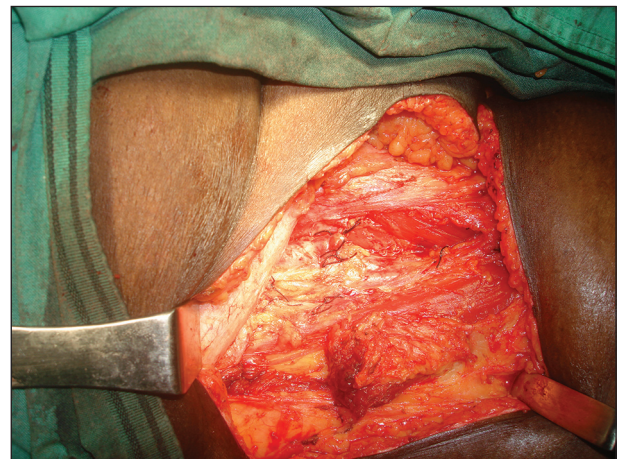


Figure 2: Postinguinal dissection soft tissue defect

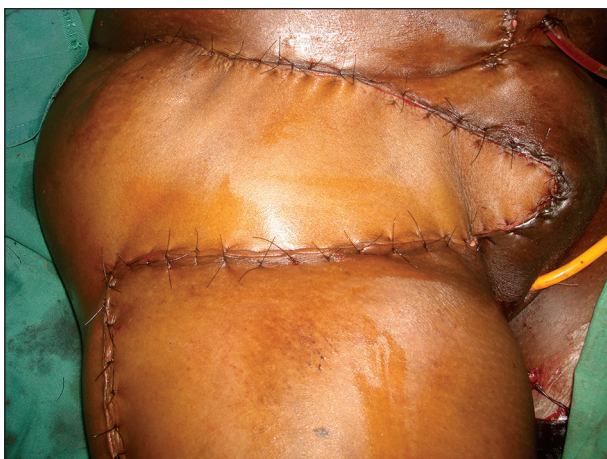

Figure 3: Immediate post-operative picture “V” flap

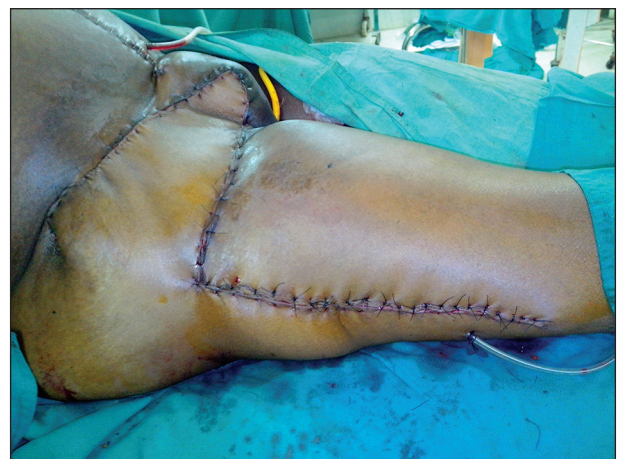

Figure 4: Immediate post-operative picture of “Z” transposition flap

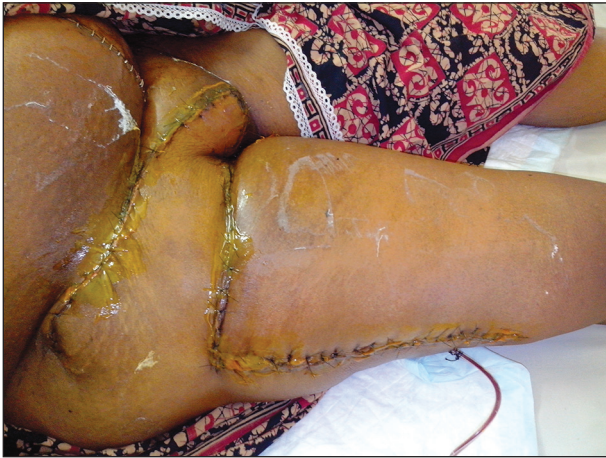

Figure 5: Post-operative day 12 following surgery

Our Flap dimensions ranged from 16 cm × 8 cm to 22 cm × 10 cm and all the donor defects were closed primarily. All the flaps did well without any complications [Figure 5].

A superiorly based “V” flap to provide a stable soft tissue cover over the femoral vessels reduces the risk of wound dehiscence and lymphatic drainage problems with minimal donor site morbidity when compared with other flaps. The technique is simple, with lesser operating time (50-60 min). It is a reliable flap for covering femoral vessels and groin with good tolerance to radiotherapy. Moreover, no muscle is sacrificed,^[1,2] and donor site is closed primarily. Superiorly based “V” flap being a single staged procedure meets the criteria formulated by Gupta *et al.*,^[3] with the blood supply of precisely known anatomy, with arterial base out of the field of resection or radiation. However, assessment of aesthetic and functional outcomes of this flap over other flaps and the “ideal” form of reconstruction for groin defects needs additional investigation with more number of patients and longer follow-up.

**Vinoth Kumar Dilliraj,
Pradeoth Korambayil Mukundan¹**

Departments of Plastic Surgery and Burns, Vijaya Hospital, Vadapalani, Chennai, Tamil Nadu, India ¹Jubilee Institute of Surgery for Hand, Aesthetic and Microsurgery, Jubilee Mission Medical College and Research Institute, Thrissur, Kerala, India

Address for correspondence:

Dr. Vinoth Kumar Dilliraj, Departments of Plastic Surgery and Burns, Vijaya Hospital, No. 434, N.S.K. Salai, Vadapalani, Chennai - 600 026, Tamil Nadu, India.
E-mail: vinothkumar.dr@gmail.com

REFERENCES

1. Wangenstein OH. Repair of recurrent and difficult hernias and other large defects of the abdominal wall employing the iliotibial tract of

fascia lata as a pedicled flap. *Surg Gynecol Obstet* 1934;59:766-80.

2. Nahai F, Hill L, Hester TR. Experiences with the tensor fascia lata flap. *Plast Reconstr Surg* 1979;63:788-99.
3. Gupta AK, Kingsly PM, Jeeth IJ. Groin reconstruction after inguinal block dissection. *Indian J Urol* 2006;22:355-9.

Access this article online

Quick Response Code:



Website:

www.ijps.org

DOI:

10.4103/0970-0358.146693