

## Invited Commentary

### White roll vermilion-turn down flap in primary unilateral cleft lip repair: A novel approach

The merit of cleft lip repair lies in getting a normal looking lip. The first step towards this is studying the normal anatomy of the baby lip, which is much different than the adult lip (which most surgeons carry an impression about). The normal baby lip has a very

prominent tubercle and this bulge normally occupies 1/3rd of the upper lip, as depicted in Figure 1, showing a drawing of the upper lip, baby lip and adult lip.

Access this article online	
Quick Response Code:	Website: <a href="http://www.ijps.org">www.ijps.org</a>
	DOI: 10.4103/0970-0358.163058

This is an open access article distributed under the terms of the Creative Commons Attribution-NonCommercial-ShareAlike 3.0 License, which allows others to remix, tweak, and build upon the work non-commercially, as long as the author is credited and the new creations are licensed under the identical terms.

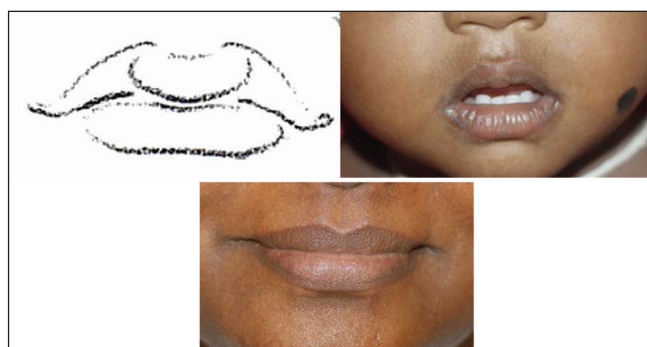
**How to cite this article:** Murthy J. White roll vermilion-turn down flap in primary unilateral cleft lip repair: A novel approach. Indian J Plast Surg 2015;48:184-6.

Modifications of cleft lip repair are widely adopted in individual practice. Most of the modifications are based on one of the two most popular techniques--Millard's or Tennison-Randall. Millard has described vermilion reconstruction either by onlay flap, as a triangular flap or as posterior inter-digitation. Millard also described transferring a lateral vermilion flap<sup>[1]</sup>, though it was without white line unlike the present author. Nevertheless, Millard warned that this modification is appropriate only if the lateral component is well-developed and carries enough soft tissue bulk medially.

The principle of the rotation advancement approach is to save maximum tissue, rearrange the natural landmarks and place the scar in the least objectionable position where it is easy to revise. Noordhoff<sup>[2]</sup>, Fisher<sup>[3]</sup> and others have modified Millard's technique for avoiding vermilion notching. These modifications give good results in some cases while thinner or bulkier vermilion in others. We are struggling to achieve consistently good results in the static face and have not yet progressed to the dynamic lip aesthetic outcome.

The present technique is described to avoid notching in the vermilion, which is often due to faulty surgical technique, inadequate rotation of Millard's technique and straight line scar (as mentioned by the author in his article as well). Therefore, attention needs to be directed to these corrections rather than only the vermilion. Mulliken and Martínez-Pérez<sup>[4]</sup> have thoughtfully modified Millard's technique by adding a small Z-plasty at a different level of skin, vermilion and mucosa to overcome the problem of notching.

The authors' technique is based on their experience of bilateral cleft lip repair using lateral segment vermilion giving good immediate results. However, if one follows

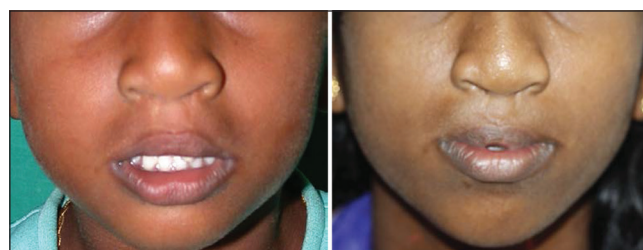

**Figure 1:** Line drawing of upper lip, upper lip in children and adults and the difference

up these children to adolescence, the aesthetic outcome is an unnatural looking lip without a tubercle in the centre [Figure 2].

The present procedure has a few shortcomings:

1. The embryological figure is simplistic. As we know cleft lip occurs for different reasons such as failure of fusion, hypoplastic mesoderm leading to disruption of fusion embryologically; when the maxillary segment is hypoplastic resulting in cleft lip, the lateral segment is likely to be smaller and may not contain adequate tissue bulk. This technique is certainly not suitable for these types of cases.
2. The medial segment has median tubercle with white roll and vermilion mucosa, though often hypoplastic. This demands augmentation rather than complete replacement. As we understand lip embryology today, the bulk of vermilion musculature comes from the lateral mesoderm, but the epidermal components like mucosa and skin of the central segment are derived from medial nasal processes.
3. Minimal discarding of tissue should be the aim of any plastic surgeon, especially precious tissue like vermilion. The white roll and vermilion of the medial segment from midline onwards is very precious tissue, and should not be routinely discarded.
4. In the presented technique, the notch of vermilion is moved from lateral to tubercle, where natural peaking is present in normal babies (as shown in the photo 2 of author's article with beautiful smile in Figure 1). End-on suturing of vermilion has the potential of creating a small depression. In addition, though the procedure provides a straight line of vermilion, there is stark absence of the tubercle, which is very prominent in the normal lip, especially in children.
5. In order to provide adequate bulk for the central vermilion with a white roll, one tends to move point 3 more laterally, compromising the horizontal length of the lip and making the lip tighter, which has many more consequences.



**Figure 2:** Bilateral cleft lip repair at age of 4 years and then 14 years

6. The presented principle of tubercle reconstruction from the lateral segment is based on bilateral cleft lip repair; if however, one carefully follows up these children, it does not look as natural in adulthood as it does in operated babies. Secondly, if one does not execute this procedure with extreme care and skill while separating the white line from the lateral segment, it can either leave extra skin or remove some part of white line, both of which will give disastrous results as the child grows.

The best way to evaluate any procedure is not by observing a single surgeon's cases presented through photographs of the best results; the best way is an assessment of a series of cases, by a clinician not involved in treatment and the satisfaction of patients/parents. The present technique lacks validity due to failure to subject it to objective evaluation.

No one method fits all cases of cleft lip; as we know each cleft is different. Plasticity of surgeons' mind to adapt and modify the technique to suit the variable nature of cleft

lip deformity is essential, but not widely practiced. The present technique contributes to the many modifications of Millard's technique. Previous studies and experience have shown that the operating surgeon matters the most in any outcome. This article supports this beautifully.

**Jyotsna Murthy**

Department of Plastic Surgery, Sri Ramachandra University,  
Chennai, Tamil Nadu, India

**Address for correspondence:**

Prof. Jyotsna Murthy, Department of Plastic Surgery,  
Sri Ramachandra University, Chennai, Tamil Nadu, India.  
E-mail: murthyjyotsna@gmail.com

## REFERENCES

1. Millard DR. Complete unilateral clefts of the lip. *Plast Reconstr Surg* 1960;25:595-605.
2. Noordhoff MS. Reconstruction of vermilion in unilateral and bilateral cleft lips. *Plast Reconstr Surg* 1984;73:52-61.
3. Fisher DM. Unilateral cleft lip repair: An anatomical subunit approximation technique. *Plast Reconstr Surg* 2005;116:61-71.
4. Mulliken JB, Martínez-Pérez D. The principle of rotation advancement for repair of unilateral complete cleft lip and nasal deformity: Technical variations and analysis of results. *Plast Reconstr Surg* 1999;104:1247-60.