Published online: 2019-08-26

Prof. Mira Sen (Banerji) CME Article

Fibrous dysplasia and cherubism

Surajit Bhattacharya, RK Mishra[1]

Department of Plastic and Reconstructive Surgery, Sahara Hospital, [1]SIPS Hospital, Lucknow, Uttar Pradesh, India

Address for correspondence: Dr. RK Mishra, SIPS Hospital, 29 Shah Mina Road, Lucknow - 226 003, Uttar Pradesh, India.
E-mail: drrkmishra@hotmail.com

ABSTRACT

Fibrous dysplasia (FD) is a non-malignant fibro-osseous bony lesion in which the involved bone/bones gradually get converted into expanding cystic and fibrous tissue. The underlying defect in FD is post-natal mutation of GNAS1 gene, which leads to the proliferation and activation of undifferentiated mesenchymal cells arresting the bone development in woven phase and ultimately converting them into fibro-osseous cystic tissue. Cherubism is a hereditary form of fibrous dysplasia in which the causative factor is transmission of autosomal dominant SH3BP2 gene mutation. The disease may present in two distinct forms, a less severe and limited monostotic form, and a more aggressive and more widespread polyostotic form. Polyostotic form may be associated with various endocrine abnormalities, which require active management apart from the management of FD. Management of FD is not free from controversies. While total surgical excision of the involved area and reconstruction using newer micro-vascular technique is the only definitive treatment available from the curative point of view, but this can be only offered to monostotic and very few polyostotic lesions. In polyostotic varieties on many occasions these radical surgeries are very deforming in these slow growing lesions and so their indication is highly debated. The treatment of cranio-facial fibrous dysplasia should be highly individualized, depending on the fact that the clinical behavior of lesion is variable at various ages and in individual patients. A more conservative approach in the form of aesthetic recontouring of deformed bone, orthodontic occlusal correction, and watchful expectancy may be the more accepted form of treatment in young patients. Newer generation real-time imaging guidance during recontouring surgery adds to accuracy and safety of these procedures. Regular clinical and radiological follow up is required to watch for quiescence, regression or reactivation of the disease process. Patients must be warned and watched for any sign of nerve compression, especially visual impairment due to optic nerve compression. Rather than going for prophylactic optic canal decompression (which does more harm than good), optic nerve decompression should be done in symptomatic patients only, and preferably be done via minimal invasive endoscopic neuro-surgical approach than the conventional more morbid open craniotomy approach. There is growing research and possibilities that newer generation bisphosphonate medication may change

Access this article online	
Quick Response Code:	Website: www.ijps.org
	DOI: 10.4103/0970-0358.173101

This is an open access article distributed under the terms of the Creative Commons Attribution-NonCommercial-ShareAlike 3.0 License, which allows others to remix, tweak, and build upon the work non-commercially, as long as the author is credited and the new creations are licensed under the identical terms.

For reprints contact: reprints@medknow.com

How to cite this article: Bhattacharya S, Mishra RK. Fibrous dysplasia and cherubism. Indian J Plast Surg 2015;48:236-48.

the management scenario, as these medications show encouraging response in not only reducing the osteoclastic activity, but simultaneously also stimulating the osteoblastic and osteocytic activities. The explosion of genetic research and stem cell therapy may lead to better understanding and subsequently better treatment of FD in future.

KEY WORDS

Bisphosphonate; cherubism; cranio-facial fibrous dysplasia; fibro-osseous bony lesion; fibrous dysplasia

FIBROUS DYSPLASIA

INTRODUCTION

Fibrous dysplasia of the bone is a lesion of unknown aetiology, uncertain pathology, diverse histology, which although not strictly a neoplasm behaves like one. Von Recklinghausen first described it in 1891.[1] It is a developmental derangement of bones caused by an aberrant activity of bone forming mesenchymal tissue resulting in abnormal proliferation of undifferentiated mesenchymal bone forming cells.[2] These undifferentiated mesenchymal cells fail to mature into lamellar bone and lead to disorganized poorly calcified fibrous bone trabeculae, so the normal bone is gradually replaced with fibrous bone tissue.[3] The bony lesion exhibits general histologic features of fibrosis with varying degree of simultaneous resorption and repair. Fibrous dysplasia can affect one or several bones, occur anywhere but are usually found in the proximal femur, tibia, humerus, ribs, and craniofacial bones in decreasing order of incidence. There is no known cure for fibrous dysplasia. Most lesions are monostotic, asymptomatic and identified incidentally and can be treated with clinical observation, patient education and surgery in selective cases. In this paper, the discussion will mostly revolve around cranio-facial fibrous dysplasia.

INCIDENCE AND DEMOGRAPHIC PRESENTATION[1,4]

Fibrous dysplasia is usually diagnosed in childhood or adolescence. They progress gradually and halt after attaining maturity, sometimes regress in few percentage of cases. Most patients with fibrous dysplasia are diagnosed in the first three decades of life. Males and females of any race are equally affected. It accounts for 7% of benign bone tumours.

This tumor is normally a monostotic (solitary) tumor that arises during periods of bone growth in older children and adolescents and slowly enlarges. Monostotic fibrous dysplasia accounts for 75 to 80% of cases. Polyostotic fibrous dysplasia may occur as multiple lesions in adjacent bones or multiple extremities. Skeletal deformities can occur as a result of repeated pathological fractures through affected bone. Cranio-facial bony involvement occurs in 27% of monostotic and up to 50% of polyostotic patients. Generalized fibrous dysplasia involving the face and skull is called "Leontiasis ossea."[5]

ETIOPATHOGENESIS

Fibrous dysplasia is linked to a gene mutation on GNAS1 gene[1,6] that affect the cells that produce bone. The mutation occurs after conception, in the early stages of fetal development. This is a somatic mutation, rather than in the germ line. That means the mutation isn't inherited from parents,[3] and can't be passed on to children. The cause of the gene mutation is not known, however, levels of transcription factor C-fos are raised in fibrous dysplasia, leading to gene over-expression and tumour formation.[1,2] There may be a relationship between the c-fos proto-oncogene and the development of fibrous dysplasia. The gene mutation causes an abnormal proliferation of undifferentiated mesenchymal bone forming cells. These undifferentiated mesenchymal cells fail to mature into lamellar bone (arrest of bone development in woven phase) and lead to disorganized poorly calcified fibrous bone trabeculae, so gradually the normal bone is replaced with fibrous bone tissue. The bony trabeculae are abnormally thin and irregular, and often likened to "Chinese character" or "Alphabet soup" (bony spicules on biopsy).[7]

The abnormality is limited to the tissues within the lesions. The cells have an increased number of hormone receptors, which may explain why these lesions become more active during pregnancy.[8,9] There are reports of increased pain in fibrous dysplasia lesions linked to monthly menstrual cycle.[10]

The same abnormality that occurs in the bone cells of fibrous dysplasia may also occur in the cells of some of the endocrinal glands. This can lead to hormonal abnormalities. This is rare and generally only happens with severe forms of polyostotic fibrous dysplasia. McCune-Albright syndrome is a condition where polyostotic fibrous dysplasia occurs with pigmented skin lesions ("cafe au lait" spots) and hormonal abnormalities.

The association of fibrous dysplasia and soft tissue tumors has been given the name Mazabraud's syndrome.[11,12] Many endocrinal abnormalities including hyperthyroidism, Cushing's disease, precautious puberty, gigantism, thyromegaly, hypophosphatemia, and hyperprolactinemia have been associated with fibrous dysplasia.[13] Fibrous dysplasia of bone may also be an associated abnormality in neurofibromatosis type-II.[14]

CLINICAL PRESENTATION

In most cases, fibrous dysplasia has no symptoms and is only diagnosed by accident during investigations for an unrelated medical problem, though pain and swelling may accompany the lesion.

Symptom of fibrous dysplasia may be divided into following categories:

Bony deformities

The most common presentation of fibrous dysplasia is swelling or lobulated deformity of involved area, mostly the maxilla,[15] zygoma, mandible, frontal or periorbital area [Figure 1]. Many patients' presents with external visible aesthetic deformity, especially when involving the skull or facial bones. Due to expansion of alveolar bony lesion, patient may present as mal-occlusion or increased gaping in between the teeth [Figure 2]. The weakened area of an affected bone can cause the bone to bend and deformity of the bone over time. Deformity of the facial bones and bowing of the leg bones can be noticeable. When the leg and pelvis bones are severely deformed, arthritis may develop in nearby joints. Fibrous dysplasia of femur is characterized by Shepherd Crook's deformity, which refers to a coxa vara angulation of the proximal femur.[16]

Bone pain

As the abnormally formed fibrous tissue grows and expands, the involved area of bone becomes weaker. The weakened area of bone can become painful. Pain is more likely to occur in the weight-bearing leg and pelvic bones. This type of pain generally begins as a dull ache that is made worse with activity and lessened with rest. It can progressively increase with time. The pain increases with weight-bearing activity, causes a limp, doesn't go away with rest and interrupts sleep. In cranio-facial fibrous dysplasia, pain is usually not a feature, but patients may complain of pain secondarily due to obstructed paranasal sinuses or compression of nerves in foramina.

Obstruction, compression or entrapment due to growing fibrous bone

As one or more bones progressively increase in size, the facial features are deformed and facial symmetry is the first casualty. The shape of the skull may change and the dysplastic bone may move into the cavities of the eye, mouth, and/or the nose and its sinuses. There may be interference of the nasal passage and intrusion of the oral cavity [Figure 3a]. Expansion of periorbital bony lesion may compress

Figure 1: Common prsentation of fibrous dysplasia as asymptomatic swellings of peri-orbital area (a), zygoma (b), maxilla (c) and palatal surface of maxilla (d)

Figure 2: Fibrous dysplasia of left side of mandible creating malocclusion and anterior open bite

over the globe. This may lead to abnormal protrusion of the eyeball (exophthalmos) and eventually may cause complete loss of vision because of the compression on the optic nerve [Figure 3b]. Fibrous dysplasia can also result in other cranial nerve compressions. If the temporal bone is affected, the patient may suffer as much as 80% hearing loss due to narrowing of inner ear canal. It may also cause facial nerve paralysis or dizziness. Any of 12 cranial nerves can be involved with fibrous dysplasia, however, the most common are optic nerve and vestibule-cochlear nerve, leading to sight and hearing loss.[17]

Fractures

Sometimes, the bone breaks through the weak area, causing sudden severe pain. This can happen after there has already been less severe pain for a time, or it may happen suddenly with no prior pain. Tooth may loosen and fall off.

Endocrine abnormalities

Rarely, fibrous dysplasia may be associated with abnormalities in the endocrine system. Young patients with hormonal abnormalities may develop early puberty. This problem is more common in girls than boys. This is usually caused by over activity of the ovaries, often occurring as early at 3-years of age. The elevated hormone levels normally associated with pregnancy may speed up the growth of fibrous dysplasia lesions, causing increased pain especially during menstruation or pregnancy.

Over activity may also occur in other glands of the body, including:[13]

- The thyroid gland (causing anxiety, loss of weight, and abnormal sweating).
- The adrenal glands (causing weight gain, and diabetes)
- The pituitary gland (causing milk production in women, gigantism, acromegaly).
- The parathyroid glands (causing high levels of calcium in the blood and/or hyperphosphatemia).

COMPLICATIONS

Severe fibrous dysplasia can cause:

- Bone deformity or fracture. The weakened area of an affected bone can cause the bone to bend or tooth to fall. These weakened bones also are more likely to fracture.
- Vision and hearing loss. The optic nerve and vestibulo-cochlear nerve may be surrounded by affected bone.

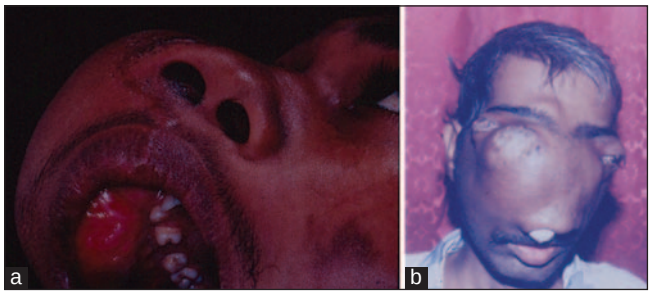

Figure 3: Fibrous dysplasia intruding into oral and nasal cavity (a). Another very severe case leading to nasal passage obstruction, proptosis and loss of vision (b)

- Arthritis. If leg and pelvic bones are deformed, arthritis may form in the joints of those bones.
- Cancer. Rarely, an affected area of bone can become cancerous. This rare complication usually only affects people who have had prior radiation therapy. Warning signs that an area of fibrous dysplasia may have become cancerous include increasing pain, particularly pain that wakes you up at night or does not go away with rest. The increase in growth rate of any mass should always be investigated.

CLASSIFICATION

Fibrous dysplasia itself is one of the categories of heterogeneous group of lesions exhibiting variety of clinic-pathological features, grossly termed as fibro-osseous lesions (FOL). WHO classified these FOL into three groups namely Fibrous Dysplasia (FD), Osseous Dysplasia (OD), and Ossifying Fibroma (OF).[18] Since the original term Fibrous dysplasia was introduced by Liechtenstein in 1938, many attempts have been made to classify this disease. Grossly, there are two types of fibrous dysplasia.

Monostotic fibrous dysplasia

It is the most common type of fibrous dysplasia, occurring in 70-80% of cases.[13] Monostotic simply means involving one bone. This is a less serious disease and usually involves the cranio-facial skeleton, long bones such as the femur, and ribs. Nearly every bone in this region can get involved individually but it is seen usually in the jawbones.

Monostotic fibrous dysplasia has often been labeled as ossifying fibroma or non-osteogenic fibroma or Leontiasis Ossea. They have to be differentiated from giant cell lesions of the jaw namely ameloblastoma, osteoclastoma, cherubism, histiocytosis X, Brown tumour of hyper-parathyroidism and aneurismal bone cysts.

It is an entity of considerable clinical and histologic variation, probably depending upon the stage and phase of disease:

- Painless swelling or bulge in the jaw, usually involving labial or buccal side, and seldom the lingual plate. Palatal or lingual surface may be involved in large or advanced lesions [Figure 4].
- Protuberant excrescences of the inferior border of mandible.
- Mal-alignment of teeth.
- Tipping or displacement of teeth due to progressive expansile lesion.
- Tenderness is a late feature.
- Mucosa is almost invariably intact over the lesion.

Fibrous dysplasia of maxilla has marked predilection for children. It is impossible to eradicate without a radical surgery, which is mutilating. These are not well circumscribed and commonly extend locally to involve maxillary sinus, zygomatic process, orbital floor and skull base resulting in severe malocclusion and marked facial asymmetry. They do not remain truly monostotic and are best described as craniofacial fibrous dysplasia. Mandibular lesions have been excised and replaced by vascularized bone flaps.

Monostotic fibrous dysplasia is a totally different disease altogether and will not march on to become polyostotic type.[13] It also does not manifest extra-skeletal lesions as seen in the polyostotic variety.

Polyostotic fibrous dysplasia

It affects 20-30% of patients.[13] Polyostotic means occurring in more than one bone [Figure 5]. The head and neck are involved in approximately half of these patients. The Polyostotic fibrous dysplasia is further classified into:

a. Fibrous dysplasia involving variable number of bones although most of the skeleton is normal and accompanied by pigmented skin lesions or café-au-lait spots – **Jaffe-Lichtenstein Syndrome** or simply, Jaffe Type.[19]
b. A most severe disease involving nearly all the bones of the skeleton, accompanied by pigmented skin or oral mucosal lesions, and endocrine disturbances of various types – **McCune Albright syndrome**.[20] It only occurs in approximately 3% of cases.

The clinical features of cranio-facial fibrous dysplasia are facial asymmetry, diplopia, proptosis, sinus infection, deafness, loss of vision, oro-nasal obstruction, malocclusion, cranial nerve involvement, raised intra-cranial and intra-orbital pressure. Oral manifestations are related to the severe disturbance in the bony tissue of the cranio-facial skeleton. The commonest lesions are in the mandible and the peri-orbital bones. Expansion and deformity of the jaw, disturbed eruption pattern of teeth are because of loss of normal support of developing teeth and endocrinal disturbances affecting the timing of eruption of the teeth.

Fibrous dysplasia in other regions present with bowing and thickening of long bones, aching and recurrent bone pains, spontaneous fractures and resultant invalidism, and possible associated skin lesions – café-au-lait spots [Figure 6].

INVESTIGATIONSAND DIAGNOSIS

- Plain X-ray.

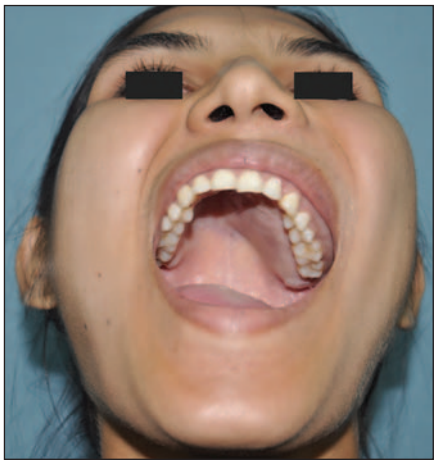

Figure 4: Fibrous dysplasia of left maxilla with involvemenet of both labial as well as palatal surface with visible left palatal bulge

Figure 5: A case of polyostotic fibrous dysplasia

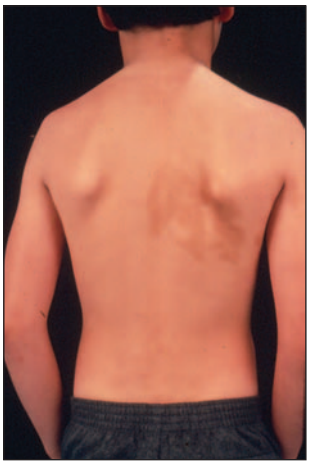

Figure 6: Typical skin pigmentation in many cases of fibrous dysplasia, the café-au-lait spots

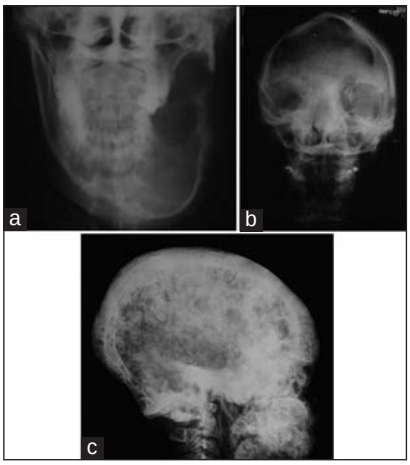

Figure 7: Spectrum of radiological appearance in various cases of fibrous dysplasias. Cystic or loccular appearance (a), Mottled appearance (b) or more opaque and generaliged groud glass appearance (c)

- Imaging tests: Computerized tomography or magnetic resonance imaging scans are used to determine how extensively the bones are affected.
- Bone scan: This test uses radioactive tracers (usually Tc-99), which are injected into the bloodstream. The damaged parts of bones (hyperactive) take up more of the tracers, which show up more brightly on the scan.
- Biopsy: A needle biopsy or an open biopsy is confirmatory.
- Biochemical tests to detect Bone Turnover Markers (BTMs) like Serum Alkaline phosphatase, monitoring the levels of various hormones if indicated.

X-Ray appearance and advanced imaging findings

Radiographically, fibrous dysplasia appears as a well-circumscribed lesion with a ground glass or hazy appearance of the matrix [Figure 7]. There is a narrow zone of transition and no periosteal reaction or soft tissue mass. Sometimes there is focal thinning of the overlying cortex, called "scalloping from within". The radiological appearance can also be cystic, pagetoid, or dense and sclerotic. These are variable there being three basic patterns:[21]

1. Small lesions with unilocular radiolucency, or somewhat larger lesions with multilocular radiolucency, both with well circumscribed borders and containing a network of fine bony trabaculae [Figure 7a].
2. Similar pattern except that increased trabaculations render the lesion more opaque, and typically mottled in appearance [Figure 7b].
3. More opaque with many delicate trabaculae giving it a 'ground glass' appearance [Figure 7c].

In all the types generally the cortical bone becomes thinner because of expansile nature of the lesion, but seldom is the bone plate perforated or the periosteal proliferation obvious. In cranio-facial fibrous dysplasia there is a characteristic mottled or pagetoid thickening and calcification of the base of skull.

There are however advantages of using multiple imaging modalities in the evaluation of these disorders. C.T. scan can show the diagnostic findings of Fibrous dysplasia and the extent of bony involvement [Figure 8], which is extremely important in planning treatment in cranio-facial lesions in particular. MRI scan show the extent and vascularity of the intra-diploeic fibrous mass, and also best demonstrates the distortion of underlying cerebral or orbital structures. MRI or CT scan can identify sarcomatous change within the lesion.

Bone scans are not helpful in diagnosing these lesions but can be useful in identifying asymptomatic lesions.[22] Tc99 HM-PAO brain scintigraphy is employed to demonstrate the adequacy of ipsilateral cerebral perfusion, thereby excluding any significant cerebral 'steal'. Tc99 bone scan uptake may be normal or increased.

Histopathology findings

On gross appearance, the tumor is a solid white or tan mass. The cut surface is gritty or sandy because of the fine bone spicules it contains. There is considerable variation in the microscopic appearance. The lesion is essentially a fibrous one, made up of proliferating fibroblasts in a compact stroma of interlacing collagen fibers; irregular trabaculae of bone are scattered throughout the lesion with no definite pattern or arrangement [Figure 9]. Characteristically C-shaped or Chinese characters shaped trabaculae, (described as "Chinese letters" or "alphabet

Figure 8: CT scan findings in cases of fibrous dysplasia to evaluate actual extent of involvement. (a) 3-D reconstruction of right sides mandibular FD, (b) transverse cut and 3-D reconstruction of left zygomatic lesion, and (c) 3-D reconstruction of right supraorbital FD lesion

soup"),[7] which are usually coarse woven bone, are seen instead of well-organized lamellar bone.

Large lesions may show histological variations from area to area, sometimes presenting greater bony reaction around the periphery than in the central core of the lesion.

MANAGEMENT

Fibrous dysplasia is a chronic disorder. It is often progressive. Although lesions may stabilize and stop growing, they usually do not disappear. Individual lesions may progress more rapidly in the polyostotic form and in growing children. McCune-Albrightsyndrome requires multidisciplinary treatment approach and involvement of endocrine physician to diagnose and manage endocrine abnormalities.

The modalities of management of fibrous dysplasia are:

Observation

Mild fibrous dysplasia that's discovered incidentally and with no signs or symptoms, the risk of developing severe deformity or fracturing the bone, particularly in the cranio-facial variety, is low. Only monitoring the condition with periodic X-rays is required. Patients should be warned for any sign of vision or hearing disturbances and any disturbing obstructive symptoms in nasal airway. Orthodontic support and braces may be needed to manage mal-occlusion or misaligned tooth. Braces may occasionally be used to prevent fracture of long bones, but they have not been effective in preventing deformity.[23]

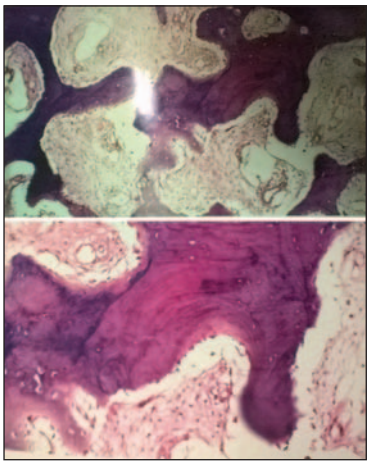

Figure 9: Histopathological features of FD showing irregular trabecullae with compact stroma of interlacing collagen fibers

Medications

Bisphosphonates are medications that inhibit the activity of osteoclasts, cells that dissolve bone. They are available in easy to take oral forms too. These medications have not been used extensively in the treatment of fibrous dysplasia, but studies have demonstrated effective relief of the pain associated with fibrous dysplasia, especially fibrous dysplasia of spine, pelvis and long bones; and reduction/normalization of the bone turnover markers.[24-27] Though the main mode of action of bisphosphonates is its inhibitory effect on osteoclasts, some recent studies suggests that they may also have stimulating effect on osteoblast and inhibit the apoptosis of osteocyte and osteoblasts.[28,29] By this way, they may help strengthen bones affected by fibrous dysplasia. This can relieve pain and help reduce the risk of fractures.

Medical therapy is typically the first and effective line of treatment for any endocrinopathies.

Surgical treatment

A biopsy may be needed to confirm the diagnosis, but asymptomatic lesion, whose behavior is latent do not need any evaluation or treatment unless there is a risk of pathologic fracture or nerve compression.[1] Surgery

Figure 10: A severe monostotic FD of right mandible (a & b) and coronal cut in CT scan (c). The lesion was excised completelly and reconstructed using vascularized free fibula (d)

has very little role in severe forms of polyostotic fibrous dysplasia, as it tends to be a progressive disease. Surgery of monostotic lesion with curettage of the lesion can be associated with risk of local recurrence. Total excision and reconstruction is the only definitive treatment for cranio-facial fibrous dysplasia.[30] Excision and replacement with recontoured bone, autogenous bone graft, autoclaved bone[31] and implants (titanium, polyrane and methyl methacrylate) have all been tried. For monostotic mandibular or maxillary lesions segmental resection of the involved segment with reconstruction by vascularized fibula or iliac crest remains the treatment of choice.[32] [Figure 10].

But in polyostotic lesions of the cranio-facial skeleton there remains a dilemma between total excision (some times very deforming) and just aesthetic recontouring of deformed craniofacial skeleton with observation. A surgical success may in fact turn out to be a social disaster if the resultant disfigurement is worse than the one produced by the disease!

Chen and Noordhoff in 1990 suggested that the surgical treatment should be based on zones of involvement:[33]

- Total excision of dysplastic bones of fronto-orbital, zygoma and upper maxillary regions and primary bony reconstruction (Zone 1);
- Conservative excision of hair bearing skull (Zone 2), central cranial base (Zone 3), and tooth bearing bones (Zone 4).

Many authors prefer aggressive definitive excision and micro-vascular reconstruction in monostotic or monofocal lesion, and reported good functional

Figure 11: Asymptomatic very slow growing fibrous dysplasia of right supraorbital area in a teenage girl presenting with aesthtic deformity (a and b). The lesion was exposed through coronal incision (c) and contoured using high speed rotating burr (d) showing postoperative aesthetic outcome (e and f)

and aesthetic results[30,32,33] While many recommend expectant management of asymptomatic patients even in the presence of radiological evidence of Cranio-facial FD, as most of the cranio-facial fibrous dysplasia remains asymptomatic on long term follow up, especially after attaining maturity.[1,34,35]

Treatment of Cranio-facial FD (CFD) should be highly individualized. Since most of the CFD cases presents with asymptomatic swellings or facial deformity, surgical recontouring after cessation of growth provide the best result[36] [Figure 11]. Cosmetic recontouring, and orthognathic surgery for malocclusion are reported by many authors.[34,35,37] Real time image guided navigation is a valuable treatment modality during cranio-facial bone contouring, shows benefit of improved accuracy and safety in complicated cases.[38]

Rarely emergency surgery is required to prevent deterioration of vision or raised intra-cranial pressure. Thus orbital decompression, cranial decompression and oro-nasal decompression is at times required in cranio-facial lesions.[4] Many studies have showed that there is

no role of prophylactic decompression of optic nerve. Surgical treatment to decompress the optic nerve should only be carried out when there are symptoms of vision disturbances. The risk of injury to the optic nerve and subsequent vision loss negates for the prophylactic optic nerve decompression.[4,17,34] In recent years, more emphasis has been given to involve minimal invasive neurosurgical team (endoscopic) to decompress optic nerves using trans-sphenoidal endoscopic approach rather than open craniotomy approach.[30,35]

Thus the following findings are associated with the need for surgery:

- Symptomatic lesions that have not responded to non-surgical treatment.
- Progressive deformity – facial asymmetry.
- To relieve pressure on a nerve, particularly if the lesion is in skull or face.
- Presence of cancer.
- Displaced fractures, hairline cracks that do not heal with casting or bracing in long bones.
- As a means to prevent large lesions from causing a fracture in long bones.

Radiotherapy has been tried with some success but the hazards of subsequent development of radiation-induced sarcoma have been reported.[39,40]

Outcomes of treatment and prognosis

Total excision and reconstruction is the only definitive treatment available but can be offered only to monostotic and a very few polyostotic cranio-facial lesions. Micro-vascular free fibular flap or iliac crest is the workhorse of reconstruction. After complete and therapeutic resection of cranio-facial fibrous dysplasia, the chances of recurrence is almost negligible. Even in cases where complete resection is not possible or undesirable to avoid severe deformity, the chances and rate of recurrence is very low and reduces progressively with increasing age. Patient may be monitored with regular radiography and serum chemical markers of bone turnover like Serum Alkaline phosphatase.[41]

Patients with symptomatic or large lesions from fibrous dysplasia should be placed on biphosphate medicines for long-term. These medicines have proven effective in reducing symptoms and increasing cortical thickness. Large, symptomatic or critical lesions can be managed with intravenous bisphosphonate medicines, including zolendronic acid.

Usually an uncomplicated fibrous dysplasia is compatible with life but deaths as a result of fibrous dysplasia have also been reported.[42] Malignant transformation into osteogenic sarcoma has been reported in both monostotic and polyostotic variety.[39,40]

RESEARCH ON THE HORIZON

1. The explosion of genetic research may lead to a better understanding of the exact mutation involved in fibrous dysplasia. That may lead to more effective nonsurgical treatments.[6,43,44]
2. Newer generations of medications, like the bisphosphonates, have made them easier to take with fewer side effects. Till now, use of these medication results in decrease or disappearance of bone turnover markers, occasionally reduction of pain, but there are no reports of cure or regression. More experience with these medications may result in more effective treatment of FD.[26,28]

CHERUBISM

Familial fibrous dysplasia (fibro-osseous lesion) of the jaw is more commonly called Cherubism because of the typical chubby facial deformity (Cherub = Sweet innocent baby or little angel) with which these patients present [Figure 12]. Seen in early childhood (3-5 years), there is a progressive painless, symmetric swelling of the jaws, producing a typical chubby face, suggestive of a cherub. Approximately 200 cases have been reported by medical journals with the majority being males. The term Cherubism was first coined and documented by Dr. W. A. Jones of Kingston, Ontario in 1933. He describes the case of three siblings of a Jewish Russian family; they

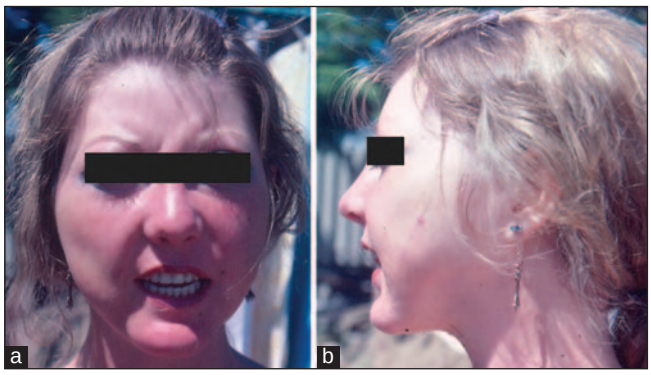

Figure 12: Typical cases of Cherubism involving maxilla with characteristic chubby cheek appearance. Front (a) and profile (b) picture

developed a characteristic swelling of jawbone, which increases gradually. By the time these children reached the age of 15-17 years, the facial deformities became grotesque, that were subsequently operated by Dr. Jones with no recurrence of swellings after 4-years.[45,46]

The condition is due to an autosomal dominant gene with 100% penetrance in male and 75% in female with variable expressivity. Male to female ratio is 2:1. Majority of cases involve only the mandible.

A painless bony expansion of mandibular angle area is the usual first presentation, which is firm to hard on palpation and may be accompanied by regional lymphadenopathy. Involvement of maxilla and zygoma is also common. Hyperactivated osteoclastic remodeling contributes to the change of normal bone to fibrous tissue and cyst formation. As noted by the name, the patient's face becomes enlarged and disproportionate due to the fibrous tissue and atypical cystic bone formation. Respiratory, masticatory, speech and swallowing function may be impaired. The sponge-like bone formations lead to early tooth loss and problems with permanent tooth eruption. The deciduous dentition may spontaneously shed prematurely, beginning as early as 3-years of age. Permanent dentition may often be defective — Absence of numerous teeth, displacement and lack of eruption. Oral mucosa is invariably intact and there are no associated systemic manifestations. The maxilla may be more severely affected in most cases than the mandible. The maxilla maybe affected up to and including the orbits and sometimes inside the orbits,[47] creating a pressure over the globe so that the eyes appear to gaze upward.[48] Continued and increasing pressure may result into diplopia, impairment or loss of vision.

The degrees of Cherubism vary from mild to severe, and classified into three groups:

- Quiescent lesions are usually seen in adults and are non-progressive.
- Non-aggressive lesions are usually seen in teenagers and are very slow growing.
- Aggressive lesions are seen in childhood, are rapidly growing, may cause tooth displacement, root resorption, and thinning of cortical bone; may require active surgical intervention to control the condition.

While the disease is rare and painless, the afflicted patients suffer the emotional trauma of disfigurement. Although progressing rapidly during early childhood, it tends to become static and may even show regression as the patient approaches puberty. In most cases, the condition fades as the child grows, but in a few even rarer cases the condition continues to deform the affected person's face. Very rare late re-activation of cherubism in adult life or re-activation in association with polycystic ovarian disease (PCOD) is also reported by some authors.[49]

Causes

The cause of Cherubism is believed to be from a mutation of gene of SH3BP2 from chromosome 4p16.3.[50] Because the disease was found to be dominant the diseased phenotype tends to be seen in every generation at some level of severity. Therefore afflicted fathers or mothers of children with Cherubism pass the phenotype to both daughters and sons.[51] Cherubism has also been found from the random mutation of a gene in an individual having no family history of the disease (sporadic non-familial cherubism). However it is not well understood why males tend to express the disease more frequently. The disease is expressed at a rate of 80 to 100% of all affected; yet children with Cherubism vary in severity in their maxilla and mandible bony lesions.

Cherubism has also been found combined with other genetic disorders including Noonan syndrome, Ramon syndrome, and Fragile X syndrome.[52] Mutations of the SH3BP2 gene are only reported in 75% of Cherubism cases.[50]

The effects of SH3BP2 mutations are still under study, but researchers believe that the abnormal protein disrupts critical signaling pathways in cells associated with the maintenance of bone tissue and in some immune system cells. The overactive protein likely causes inflammation in the jawbones and triggers the production of osteoclasts, which are cells that break down bone tissue during bone remodeling. Cherubism is displayed with genetic conformation and when excessive osteoclasts are found in the affected areas of the mandible and maxilla. Osteoclasts also sense the increased inflammation of the mandible and maxilla and are further activated to break down bone structures. Bone loss and inflammation lead to increased fibrous tissue and cyst growth. An excess of these osteoclasts contributes to the destruction of bone in the upper and lower jaws. A combination of bone loss and inflammation likely underlies the cyst-like growths characteristic of Cherubism.

Diagnosis

The disease is usually diagnosed when dental abnormalities are found. These abnormalities include premature deciduous teeth and abnormal growth of

permanent teeth due to displacement by cysts and lesions. Initial study of the patient is usually conducted using x-ray and CT scans. Radiologically, cherubism is characterized by multilocular, well-defined radiolucencies of the involved areas, especially the posterior mandible. Histologically, the lesion resembles with giant-cell granuloma. The unique histological feature of cherubism is eosinophilic perivascular cuffing of collagen surrounding capillaries. Giant cell tumor of jaw, Odontogenic keratocyst, auto-inflammatory bone disease, sterile bone inflammation in childhood, hyperparathyroidism and neurofibromatosis are the differential diagnosis. Neurofibromatosis may resemble Cherubism and may accompany the disease. Diagnosis is based on clinical symptoms and family history. Genetic testing (sequence analysis of SH3BP2 gene) is the final confirmative diagnostic tool.[50]

Treatment

Because Cherubism changes and improves over time the treatment should be individually determined. Generally moderate cases are watched until they subside or progress into the more severe range. Orthodontic treatment is generally required to avoid permanent dental problems arising from malocclusive bite, misplaced, and unerupted permanent teeth.[52] Orthodontic treatment may be used to erupt permanent teeth that have been unable to descend due to lesions and cysts being in their path of eruption.Currently, removal of the tissue and bone by surgery is the only proven treatment available, at time very deforming. Surgical recontouring of the jaw is sometimes advised in teenagers with large, bulky and aesthetically deforming but quiescent lesions. Severe cases may require surgery to eliminate bulk cysts and fibrous growth of the maxilla and mandible. Excision and bone grafting of the involved cranio-facial bone may be successful on some patients. Surgery is preferred for patients ages 5 to 15.[53] Patients with orbital issues (diplopia, proptosis, and visual loss) will require early decompression.[53] Radiation therapy is definitely contraindicated.

Few recent reports[54,55] show promising results with medical treatment. Since the hyperactive osteoclastic bone resorption in cherubism is mediated through TNF-alfa, many antagonists of TNF-alfa (Adalimubab, Etanercept) has been tried with variable results in many studies. Calcineurin inhibitor Tarcolimus is also shown some promising results by inhibiting NFATc1 (nuclear factor of activated T-cell cytoplasmic 1) dependent osteoclastogenesis. The medical management ultimately acts by reducing the bone resorption by inhibiting osteoclastogenesis, enhance bone formation by stimulating osteogenesis, ultimately reducing the size of cystic lesion and improved true bone formation in a number of patients with variable success. Salmon calcitonin administration by intranasal route is also reported with encouraging results in cherubism.[56,57] Further research and larger clinical trials are required to establish their role in the definitive medical management.

Prevention

Because this disease is genetically linked, genetic counseling may be the only way to decrease occurrences of Cherubism. Every child of the individual affected with cherubism has 50% chance of inheriting the mutation. The lack of severe symptoms in the parents may be the cause of failure in recognizing the disorder. The optimal time to be tested for mutations is prior to having children. The disease results from a genetic mutation, and this gene has been found to spontaneously mutate. Therefore, there may be no prevention techniques available.

Declaration of Patient Consent

The authors certify that they have obtained all appropriate patient consent forms. In the form the patient(s) has/have given his/her/their consent for his/her/ their images and other clinical information to be reported in the journal. The patients understand that their names and initials will not be published and due efforts will be made to conceal their identity, but anonymity cannot be guaranteed.

Financial support and sponsorship

Nil.

Conflicts of interest

There are no conflicts of interest.

REFERENCES

1. Adetayo OA, Salcedo SE, Borad V, Richards SS, Workman AD, Ray AO. Fibrous dysplasia: An overview of disease process, indications for surgical management, and a case report. Eplasty 2015;15:e6.
2. Lichtenstein L. Diseases of Bone and Joints. 2nd ed. St. Louis: CV Mosby; 1975. p. 244.
3. Greer RO Jr, Rohrer MD, Young SK. Nonodontogenic tumors, clinical evaluation and pathology. In: Thawley SE, Panje WR, editors. Comprehensive Management of Head and Neck Tumors. Philadelphia: WB Saunders; 1987. p. 1510.
4. Leong LT, Ming BJ. Craniofacial fibrous dysplasia involving the orbit: A case report and literature review. Asia Pac J Ophthalmol (Phila) 2015;4:151-4.
5. Mansilla-Lory J, Amezcua-Guerra LM, Vargas-Rodriguez A, Fernadez-Tapia S, Leboreiro I, Resnick D, *et al*. Leontiasis ossea: A paleopathologic case report. J Clin Rheumatol 2007;13: 269-72.

6. Kuznetsov SA, Cherman N, Riminucci M, Collins MT, Robey PG, Bianco P. Age-dependent demise of GNAS-mutated skeletal stem cells and "normalization" of fibrous dysplasia of bone. J Bone Miner Res 2008;23:1731-40.
7. Matthew RD, William FE. Fibrous dysplasia: Pathophysiology, evaluation, and treatment. J Bone Joint Surg Am 2005;87: 1848-64.
8. Osada H, Sakamoto R, Seki K, Sekiya S. Accelerated bone turnover in pregnant women with McCune-Albright syndrome. Gynecol Obstet Invest 2005;60:102-7.
9. Bowers CA, Altay T, Shah L, Couldwell WT. Pregnancy induced cystic degeneration of fibrous dysplasia. Can J Neurol Sci 2012; 39:828-9.
10. Kaplan FS, Fallon MD, Boden SD, Schimidt R, Senior M, Hadda JG. Estrogen receptors in bone in a patient with polyostotic fibrous dysplasia (McCune-Albright Syndrome). N Engl J Med 1988;319:421-5.
11. Munksgaard PS, Salkus G, Iyer VV, Fisker RV. Mazabraud's syndrome: Case report with literature review. Acta Radiol Short Rep 2013;2:204.
12. Wirth WA, Leavitt D, Enzinger FM. Multiple intramuscular myxomas. Another extraskeletal manifestation of fibrous dysplasia. Cancer 1971;27:1167-73.
13. Lichtenstein L, Jaffe HL. Fibrous dysplasia of bone. A condition affecting one, several or many bones, the graver cases of which may present abnormal pigmentation of skin, premature sexual development, hyperthyroidism or still other extraskeletal abnormalities. Arch Pathol 1942;33:777-816.
14. Sujatha S, Jatti D. Neurofibromatosis and fibrous dysplasia manifesting in the same patient: A rare case report. J Investig Clin Dent 2015;6:77-80.
15. Eversole LR, Sabes WR, Rovin S. Fibrous dysplasia: A nosologic problem in the diagnosis of fibro-osseous lesions of the jaws. J Oral Pathol 1972;1:189-220.
16. Kushare IV, Colo D, Bakhshi H, Dormans JP. Fibrous dysplasia of the proximal femur: Surgical management options and outcomes. J Child Orthop 2014;8:505-11.
17. Tan YC, Yu CC, Chang CN, Ma L, Chen YR. Optic nerve compression in craniofacial fibrous dysplasia: The role and indications for decompression. Plast Reconstr Surg 2007;120:1957-62.
18. Laino L, Favia G, Menditti D, De Francesco F, Salerno C, Scivetti M, *et al*. Confocal laser scanning microscopy analysis of 10 cases of craniofacial fibrous dysplasia. Ultrastruct Pathol 2015;39:231-4.
19. Jaffe HL, Lichtenstein L. Fibrous dysplasia of bone. A condition affecting one, several or many bones, the graver cases of which may present with abnormal pigmentation of skin, premature sexual development, hyperthyroidism or still other extraskeletal abnormalities. Arch Pathol 1942;33:777-816.
20. Collins MT, Singer FR, Eugster E. McCune-Albright syndrome and the extraskeletal manifestations of fibrous dysplasia. Orphanet J Rare Dis 2012;7(Suppl 1):S4.
21. Fitzpatrick KA, Taljanovic MS, Speer DP, Graham AR, Jacobson JA, Barnes GR, *et al*. Imaging findings of fibrous dysplasia with histopathologic and intraoperative correlation. AJR Am J Roentgenol 2004;182:1389-98.
22. Zhibin Y, Quanyong L, Libo C, Jun Z, Hankui L, Jifang Z, *et al*. The role of radionuclide bone scintigraphy in fibrous dysplasia of bone. Clin Nucl Med 2004;29:177-80.
23. Petrocelli M, Kretschmer W. Conservative treatment and implant rehabilitation of the mandible in a case of craniofacial fibrous dysplasia: A case report. J Oral Maxillofac Surg 2014; 72:902. e1-6.
24. Mäkitie AA, Törnwall J, Mäkitie O. Bisphosphonate treatment in craniofacial fibrous dysplasia — A case report and review of the literature. Clin Rheumatol 2008;27:809-12.
25. Egner-Höbarth S, Welkerling H, Windhager R. Bisphosphonates in the therapy of fibrous dysplasia. Relevant data and practical aspects. Orthopade 2007;36:124, 126-30.
26. Boyce AM, Kelly MH, Brillante BA, Kushner H, Wientroub S, Riminucci M, *et al*. A randomized, double blind, placebo-controlled trial of alendronate treatment for fibrous dysplasia of bone. J Clin Endocrinol Metab 2014;99:4133-40.
27. Boyce AM, Chong WH, Yao J, Gafni RI, Kelly MH, Chamberlain CE, *et al*. Denosumab treatment for fibrous dysplasia. J Bone Miner Res 2012;27:1462-70.
28. Wu D, Ma J, Bao S, Guan H. Continuous effect with long-term safety in zoledronic acid therapy for polyostotic fibrous dysplasia with severe bone destruction. Rheumatol Int 2015; 35:767-72.
29. Ganda K, Seibel MJ. Rapid biochemical response to denosumab in fibrous dysplasia of bone: Report of two cases. Osteoporos Int 2014;25:777-82.
30. Bowers CA, Taussky P, Couldwell WT. Surgical treatment of craniofacial fibrous dysplasia in adults. Neurosurg Rev 2014; 37:47-53.
31. Lauritzen C, Alberius P, Santanelli F, Vällfors B, Lilja J, Stephensen H. Repositioning of craniofacial tumorous bone after autoclaving. Scand J Plast Reconstr Surg Hand Surg 1991;25:161-5.
32. Valentini V, Cassoni A, Marianetti TM, Terenzi V, Fadda MT, Iannetti G. Craniomaxillofacial fibrous dysplasia: Conservative treatment or radical surgery? A retrospective study on 68 patients. Plast Reconstr Surg 2009;123:653-60.
33. Chen YR, Noordhoff MS. Treatment of crani-omaxillofacial fibrous dysplasia: How early and how extensive? Plast Reconstr Surg 1990;86:835-44.
34. Amit M, Collins MT, FitzGibbon EJ, Butman JA, Fliss DM, Gil Z. Surgery versus watchful waiting in patients with craniofacial fibrous dysplasia — A meta-analysis. PLoS One 2011;6:e25179.
35. Béquignon E, Cardinne C, Lachiver X, Wagner I, Chabolle F, Baujat B. Craniofacial fibrous dysplasia surgery: A functional approach. Eur Ann Otorhinolaryngol Head Neck Dis 2013; 130:215-20.
36. Menon S, Venkatswamy S, Ramu V, Banu K, Ehtaih S, Kashyap VM. Craniofacial fibrous dysplasia: Surgery and literature review. Ann Maxillofac Surg 2013;3:66-71.
37. Zeng HF, Lu JJ, Teng L, Jin XL, Xu JJ, Zhang C, *et al*. Surgical treatment of craniomaxillofacial fibrous dysplasia: Functionally or aesthetically? J Craniofac Surg 2013;24:758-62.
38. Gui H, Zhang S, Shen SG, Wang X, Bautista JS, Voss PJ. Real-time image-guided recontouring in the management of craniofacial fibrous dysplasia. Oral Surg Oral Med Oral Pathol Oral Radiol 2013;116:680-5.
39. Yabut SM Jr, Kenan S, Sissons HA, Lewis MM. Malignant transformation of fibrous dysplasia. A case report and review of the literature. Clin Orthop Relat Res 1988;228:281-9.
40. Sadeghi SM, Hosseini SN. Spontaneous conversion of fibrous dysplasia into osteosarcoma. J Craniofac Surg 2011;22:959-61.
41. Park BY, Cheon YW, Kim YO, Pae NS, Lee WJ. Prognosis for craniofacial fibrous dysplasia after incomplete resection: Age and serum alkaline phosphatase. Int J Oral Maxillofac Surg 2010;39:221-6.
42. Harris WH, Robert Dudley H Jr, Barry RJ. The natural history of fibrous dysplasia. J Bone Joint Surg Am 1962;44:207-33.
43. Bhattacharyya N, Wiench M, Dumitrescu C, Connolly BM, Bugge TH, Patel HV, *et al*. Mechanism of FGF23 processing in fibrous dysplasia. J Bone Miner Res 2012;27:1132-41.

44. Robey PG, Kuznetsov S, Riminucci M, Bianco P. The role of stem cells in fibrous dysplasia of bone and the Mccune-Albright syndrome. Pediatr Endocrinol Rev 2007;4(Suppl 4):386-94.
45. Choremis K, Papadatos C, Caterellos C. Familial multilocular cystic disease of the jaws. Helv Paediatr Acta 1959;14:396-9.
46. Jones WA, Gerrie J, Pritchard J. Cherubism — familial fibrous dysplasia of the jaws. J Bone Joint Surg Br 1950;32-B:334-47.
47. Irfan S, Cassels-Brown A, Hayward J, Corrigan A. Orbital Cherubism. Orbit 1997;16:109-12.
48. Emoto Y, Emoto H, Fujle W, Wakakura M. Uncorrectable Oblique Astigmatism and Impaired Binocular Vision in Case of Orbital Cherubism. Neuro-ophthalmology 2007;31:191-5.
49. Lenouvel D, Chapireau D, Bentley R. Late reactivation of cherubism in a patient with new-onset polycystic ovary syndrome. J Oral Maxillofac Surg 2015;73:1957-61.
50. Li CY, Yu SF. A novel mutation in the SH3BP2 gene causes cherubism: Case report. BMC Med Genet 2006;7:84.
51. Tiziani V, Reichenberger E, Buzzo CL, Niazi S, Fukai N, Stiller M, *et al*. The gene for cherubism maps to chromosome 4p16. Am J Hum Genet 1999;65:158-66.
52. van Capelle CI, Hogeman PH, van der Sijs-Bos CJ, Heggelman BG, Idowu B, Slootweg PJ, *et al*. Neurofibromatosis presenting with a cherubism phenotype. Eur J Pediatr 2007;166:905-9.
53. Carroll AL, Sullivan TJ. Orbital involvement in cherubism. Clin Experiment Ophthalmol 2001;29:38-40.
54. Hero M, Suomalainen A, Hagström J, Stoor P, Kontio R, Alapulli H, *et al*. Anti-tumor necrosis factor treatment in cherubism — clinical, radiological and histological findings in two children. Bone 2013;52:347-53.
55. Yoshitaka T, Ishida S, Mukai T, Kittaka M, Reichenberger EJ, Ueki Y. Etanercept administration to neonatal SH3BP2 knock-in cherubism mice prevents TNF-α-induced inflammation and bone loss. J Bone Miner Res 2014;29:1170-82.
56. Fernandes Gomes M, Ferraz de Brito Penna Forte L, Hiraoka CM, Augusto Claro F, Costa Armond M. Clinical and surgical management of an aggressive cherubism treated with autogenous bone graft and calcitonin. ISRN Dent 2011;2011:340960.
57. Etoz OA, Dolanmaz D, Gunhan O. Treatment of cherubism with salmon calcitonin: A case report. Eur J Dent 2011;5:486-91.