

## Letter to Editor

# A simple technique of marking the perforator of a free flap for postoperative monitoring

Sir,

Monitoring of a free flap or a perforator flap is important in the immediate postoperative period to alert the surgeon of a vascular event and to enable flap salvage by early intervention.

Monitoring is usually done by nurses.

There are many methods of flap monitoring. The conventional method<sup>[1]</sup> of flap monitoring with a hand-held Doppler is a common method employed by doctors and nurses in the immediate postoperative period. Accurately placing the Doppler on the site of the perforator is important for proper flap monitoring. The site to be assessed by the Doppler (i.e., the site of the perforator) is usually marked by scoring the skin or marking by ink on the surface of the flap at the end of surgery. We are presenting here a simple method we have employed over the past 3 years to mark the site of the perforator which has a reliable accuracy in assessing and monitoring with different observers.

The normal self-adhesive electrocardiogram (ECG) lead is taken [Figure 1], the centre part is removed, leaving a hole in the middle [Figure 2]. At the end of the surgery, the surgeon places the ECG lead with the centre directly lying on the perforator to be assessed [Figures 3 and 4]. The lead stays on the first 5 days and makes it easy for everyone to place the Doppler consistently in the right spot. Caution calls due to doubts about the vascular status of the flap have become much lower ever since we started this method for marking.

This method of marking for flap monitoring is better, because there is no need to worry about the marking being erased with sweat and moisture, as it happens when marked with ink or the scored skin not being visible due to rapid epidermal healing.



Figure 1: ECG lead (electrode)



Figure 2: ECG lead (electrode) with a hole cut in the middle

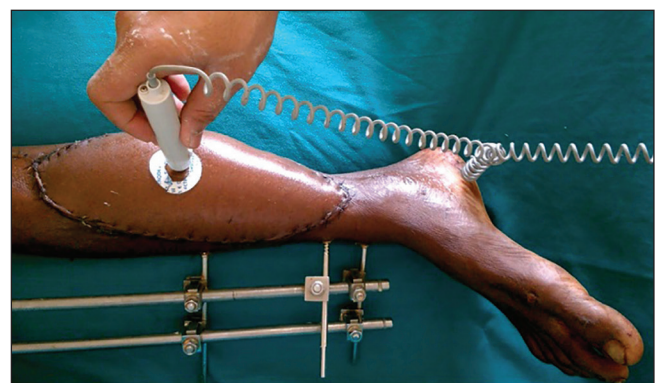
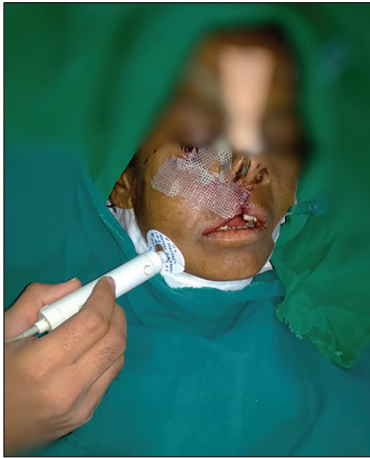

Figure 3: Doppler being done on the ALT flap perforator site marked by ECG lead (electrode)

This method of marking can be used in all places the Doppler is used, such as in monitoring the perforator in case of the anterolateral thigh (ALT) flap [Figure 3], radial



**Figure 4:** Doppler being done in a case of buried ALT flap in reconstruction of post-maxillectomy defect—vascular anastomotic site marked by ECG lead (electrode)

artery flap, free fibular flap, anastomotic site in cases of buried flap [Figure 4], when other conventional methods are not possible, and dorsalis pedis artery or radial artery in case of revascularization.

#### Financial support and sponsorship

Nil.

#### Conflicts of interest

There are no conflicts of interest.

**Hari Venkatramani, Gururaj Hosahalli,  
S Raja Sabapathy**

Department of Plastic Surgery,  
Hand Surgery,  
Reconstructive Microsurgery and Burns,  
Ganga Hospital, Coimbatore, Tamil Nadu, India.

#### Address for correspondence:

Dr. S Raja Sabapathy,  
Division of Plastic Surgery, Hand Surgery,  
Reconstructive Microsurgery and Burns,  
Ganga Hospital, 313, Mettupalayam Road,  
Coimbatore - 641 043, Tamil Nadu, India.  
E-mail: rajahand@gmail.com

#### REFERENCE

1. Smit JM, Zeebregts CJ, Acosta R, Werker PM. Advancements in free flap monitoring in the last decade: A critical review. *Plast Reconstr Surg* 2010;125:177-85.

This is an open access article distributed under the terms of the Creative Commons Attribution-NonCommercial-ShareAlike 3.0 License, which allows others to remix, tweak, and build upon the work non-commercially, as long as the author is credited and the new creations are licensed under the identical terms.

Access this article online	
Quick Response Code: 	Website: www.ijps.org
	DOI: 10.4103/0970-0358.173140

**How to cite this article:** Venkatramani H, Hosahalli G, Sabapathy SR. A simple technique of marking the perforator of a free flap for postoperative monitoring. *Indian J Plast Surg* 2015;48:321-2.