

Ideas and Innovations

Indigenous technique of fabricating vaginal mould for vaginal reconstruction and uterine drainage in McIndoe vaginoplasty using 10 ml syringe

Brijesh Mishra¹, Gaurav Janavar¹, Yashodhara Pradeep², Arun K. Singh¹, Vijay Kumar¹, Divya N. Upadhyay¹

Departments of Plastic Surgery¹, Department of Obstetrics and gynaecology², King George's Medical University, Lucknow, Uttar Pradesh, India

Address for correspondence: Dr. Brijesh Mishra, Department of Plastic Surgery, King George's Medical University, Lucknow, Uttar Pradesh, India. E-mail: drbrijeshmishra@gmail.com

ABSTRACT

Absence of vagina poses multitude of physical and psychosocial problems in woman's life. 10% of Mayer-Rokitansky-Küster-Hauser (MRKH) syndrome patients with high vaginal septum and vaginal atresia has additional issue of draining uterine cavity. MC Indoe vaginoplasty is universally acceptable and widely practiced procedure for neocolpos reconstruction. Simultaneous reconstruction of vagina with simultaneous continued uterine drainage presents surgical challenge. We offer a simple solution of creating a vaginal mould using a 10 ml disposable syringe, which enables graft application of neovaginal cavity with simultaneous protected uterine drainage per vaginum. Total 10 patients were included in this study of which 4 needed uterine drainage procedure in addition to neovaginal creation. All the patients fared well, there were no problems regarding graft loss or vaginal mould extrusion etc. Fabrication of mould for graft enables easy dressing changes with out disturbing the skin graft. This innovation offers a simple easily reproducible and cheap way of fabricating vaginal mould for McIndoe vaginoplasty. It is especially useful for neovaginal graft application and simultaneous uterine drainage.

KEY WORDS

McIndoe vaginoplasty; syringe vaginal mould; vaginal atresia (Mayer-Rokitansky-Küster-Hauser syndrome)

INTRODUCTION

The absence of vagina poses a multitude of problems in a woman's life. It has both physical and psychosocial implications. The absence of vagina *per se* can occur

as an isolated anomaly but is more commonly found as a part of Mayer-Rokitansky-Küster-Hauser (MRKH) syndrome. Vaginal atresia occurs with a frequency of 1 in 5000–10,000.^[1] Cases with transverse vaginal

This is an open access article distributed under the terms of the Creative Commons Attribution-NonCommercial-ShareAlike 3.0 License, which allows others to remix, tweak, and build upon the work non-commercially, as long as the author is credited and the new creations are licensed under the identical terms.

For reprints contact: reprints@medknow.com

How to cite this article: Mishra B, Janavar G, Pradeep Y, Singh AK, Kumar V, Upadhyay DN. Indigenous technique of fabricating vaginal mould for vaginal reconstruction and uterine drainage in McIndoe vaginoplasty using 10 ml syringe. Indian J Plast Surg 2016;49:76-80.

Access this article online	
Quick Response Code: 	Website: www.ijps.org
	DOI: 10.4103/0970-0358.182230

septum or partial vaginal atresia have an incidence of 1 in 70,000.^[2] Patients usually present at adolescence having developed normal secondary sexual characters, but failing to attain menarche. Patients usually present with cyclical lower abdominal pain, back pain, lump in abdomen and cryptomenorrhoea. This condition can lead to haematometra, haemocolpos, endometriosis or pyometra^[3] which, if left untreated can cause imminent threat to fertility.

Vaginal agenesis can be managed in various non-surgical and surgical ways.^[4-6] Abbe-McIndoe vaginoplasty has been one of the most common procedures done for neovagina reconstruction.^[7] It involves surgical creation of a vaginal cavity which has to be lined by thick split-thickness skin grafts (SSGs). Many types of local moulds have been tried to retain the grafts in place. Few special presentations such as MRKH with functioning endometrium and high transverse vaginal septum need surgical drainage of uterine contents along with neovagina reconstruction. For such cases, a draining tube needs to be passed along with the mould which is difficult to retain. Incidence of graft shearing is high while removing moulds in these cases.

Here, we describe a unique way of simultaneously reconstructing a vaginal canal and efficiently draining the uterine cavity. We propose this modification of McIndoe vaginoplasty using specially designed vaginal mould made from a 10 cc syringe. We offer this simple and convenient solution for applying graft to raw area created in neovaginal cavity with simultaneous drainage of blocked uterine cavity. This modification enables continuous drainage of the uterine cavity without disturbing graft of neovaginal cavity.

MATERIALS AND METHODS

We report 10 cases of vaginal agenesis who attended outpatient department services for common complaint of primary amenorrhoea. All the patients were evaluated for other syndromic associations. Patients of vaginal atresia presenting with or without haematometra/haemocolpos were taken up for surgery. All patients were operated under spinal anaesthesia in lithotomy position. Urinary catheter (Foley) was inserted at the beginning of procedure. Stay sutures were taken to retract labia and improve visibility. While dissecting vaginal cavity, one assistant inserted a gloved finger per

rectally so that the operating surgeon could have an idea about location of rectum and avoid injury. Cavity was created using sharp and blunt dissection by fingers. Split-thickness skin was harvested from thigh in all cases.

Initially, we fabricated vaginal moulds with sponges and gauze pieces with or without dental impression compound. We encountered problems in cases of functioning endometrium where placing a drainage tube is essential. We first tried syringe mould for one such case where Malecot's drain was passed through hollow syringe and mould was fabricated with gauze pads and tulle grass over it. It served both the purposes very well. Drain was well fixed in place. Removal of dressing was simple as syringe was taken out first leading to collapse of outer gauze pads and tulle grass, which can be removed without shearing the grafts. Encouraged by these findings, we started using syringe mould for all our cases of McIndoe vaginoplasty [Figures 1-4].

We did few more changes to make it more efficient – Fenestrations were made in the syringe walls so that secretions/blood could pass to the hollow part of syringe. Two openings were made in the side phlanges of the syringe for better fixation by taking vicryl sutures to labia minora through these holes. Overall, it improved mould retention and helped in better fixation of skin graft. Further fixation of mould was done by taking sutures between labia majora, and it was further reinforced by bandage.

Of 10 patients, needed vaginal mould with draining Malecot's catheter. Two of these patients needed

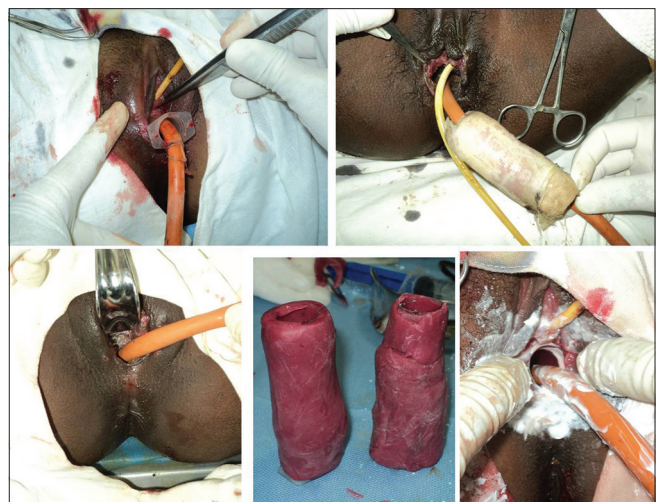


Figure 1: Modified vaginal mould made using 10 ml syringe with its placement over transcervical Malecot's drain

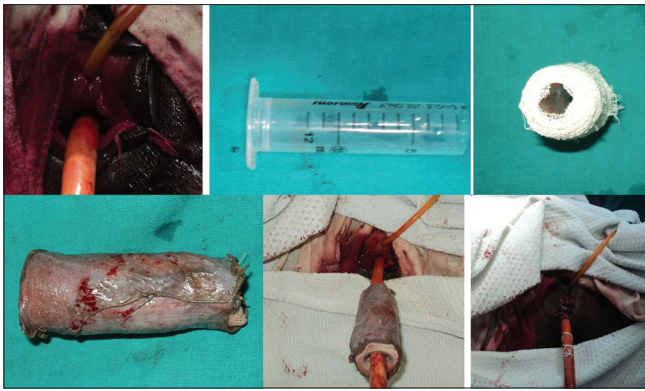


Figure 2: Removal of inner syringe part of vaginal mould, followed by collapse of gauze portion of vaginal mould

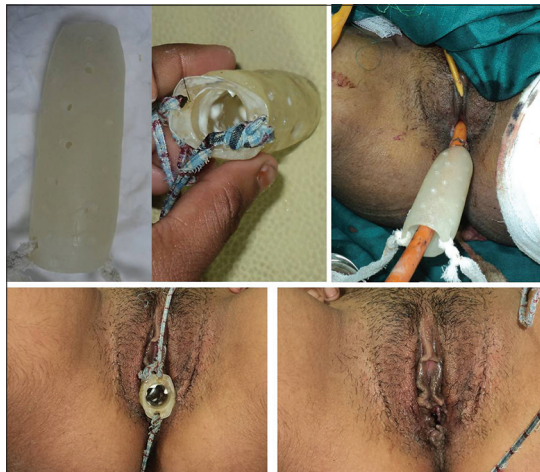

Figure 3: Fabricated acrylic mould on syringe for prevention of graft contraction

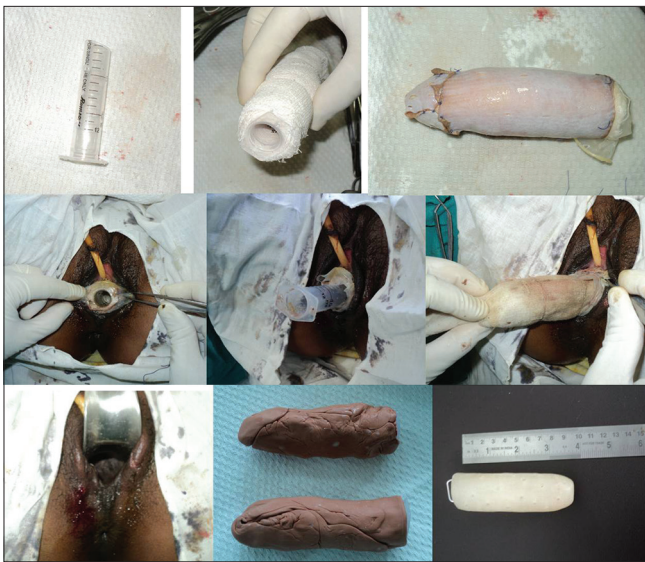

Figure 4: Vaginoplasty with syringe mould without drainage tube

abdominoperineal approach whereas two cases could be done by vaginal approach alone. These patients had haematometra with transverse vaginal septum,

here placement of draining catheter was checked by intraoperative ultrasound confirmation.

Abdominal approach will be necessary in cases of minor degree of haematometra to avoid risk of injury to bladder and bowel. For draining uterine cavity, standard lower midline abdominal exposure was done. Neovaginal cavity was then created as in Abbe-McIndoe vaginoplasty. Continuous uterine drainage was then established using Malecot's rubber drain. Malecot's catheter was positioned by railroading through abdominal and vaginal exposure. Neovaginal cavity was then grafted with intermediate thickness SSG harvested from thigh.

In patients without uterine drainage issues, simple Abbe-McIndoe procedure was done using same modified vaginal mould without any intrauterine catheter. Size of vaginal moulds ranged from 9 cm × 3 cm × 3 cm to 12 cm × 3.5 cm × 3.5 cm.

Post-operatively, all these patients needed catheterisation till first dressing change. Dressing was done after 12 days under spinal anaesthesia. Sutures were removed from labia and the syringe mould. A variable amount of secretion/discharge was found in the lumen of syringe which was sucked out. Syringe was taken out first which led to collapse of gauze and tulle grass dressings. These dressings could be removed easily without any shearing. Neovaginal cavity was irrigated with saline and made dry. Two temporary moulds of similar size were fabricated with 10 ml syringes and dental compound. One was kept in the cavity after application of antiseptic ointment. The other mould was sent to prosthetic technician for fabrication of acrylic mould. Acrylic mould was also fabricated over 10 ml disposable syringe. It was used for long-term (at least 6 months) dilatation to prevent graft contraction. Patients were usually discharged after 2 weeks with advice for self-care of acrylic mould.

RESULTS

Six out of 10 patients presented with simple vaginal agenesis without haematometra or haematocolpos. Four patients, however, required combined drainage and neovaginal creation. There were no intraoperative complications regarding during neovaginal cavity creation and abdominal exploration. We had no problems of significant graft loss; there was only one case with minor graft loss which was conservatively managed. There were no problems regarding lower abdominal discomfort

and all patients tolerated vaginal mould comfortably. There were no problems of drain expulsion or blocked drain. Patients were followed up at monthly intervals for first 3 months and then every 3rd month till 1 year post-operatively. None of the patients had complaints regarding canal stenosis. All the patients on an average had 9-10 cms of vaginal depth at end of 6 months. There were no problems regarding fistulas, constipation or per vaginal erosive bleeding.

DISCUSSION

Among surgical methods to deal with vaginal agenesis, Abbe-McIndoe has stood the test of time and is still the most commonly practised.^[8] Few special cases such as patients of vaginal agenesis with functioning endometrium, however, need special surgical attention. These patients constitute around 10% of syndromic vaginal agenesis patients.^[9] In these patients uterine contents need to be drained along with neovagina creation. Drainage of uterine contents through neovaginal cavity forbids graft application. Traditional McIndoe procedure involves placement of vaginal mould made from gauze; so problems regarding uniformity of mould size and shearing of graft during dressing changes are encountered.^[10] Our modification of preparing syringe-based vaginal mould offers the advantage of being uniform and being able to hold graft into the neovaginal cavity while draining uterine secretions. It is in effect a semi-rigid mould which helps in maintaining the length of the created cavity because of plastic syringe, but it does not lead to pressure necrosis of adjacent tissue because of soft padding. During dressing change, removal of syringe causes collapse of overlying gauze and latex layer which minimises graft shearing. Studies have found graft loss rates up to 6% during dressing change.^[11] Use of acrylic mould again fabricated over 10 ml syringe maintains neovaginal cavity volume and prevents graft contracture. It can be used with Malecot's drain *in situ* for long period.

Abbe-McIndoe procedure has been done by many different authors with various methods of using moulds. These are either inflatable soft moulds with or without suction, silicon-based or acrylic-based rigid moulds.^[12-14] None of these authors have described a technique of draining uterine secretions along with the mould for better graft uptake. With rigid ones, clinicians have found definite risk of recto vaginal fistulae, obstructive uropathy^[11] whereas the soft ones may have more chances of graft rejection. Our modification makes this time proven procedure even

easier and swifter. Fabricating vaginal mould over syringe barrel is easier, faster and reproducible as compared to conventional methods. Both hollow vaginal mould during initial days and acrylic mould in later days enable protracted drainage of uterine cavity. Intrauterine Malecot's exits through vaginal mould and is never compressed or blocked. Isolation of neovaginal milieu from uterine drainage enables satisfactory graft uptake and reduction in cavity contracture. Equal size of both first vaginal mould and post-operative acrylic vaginal mould avoids pressure over local tissues and increases patient compliance.

None of our patients had problems in using acrylic mould for long-term as they are explained about stenosis and need of resurgery. Acrylic mould can be replaced with soft silicone mould after 3 weeks for patients who find it difficult to use. For maintenance of neovaginal cavity and graft application to neovagina with simultaneous protracted uterine drainage, no commercial splints or vaginal moulds are available. Hence, our innovation of using 10 ml syringe for fabricating hollow vaginal mould is a useful tool. Multiple perforations can be made in syringe without altering its rigidity which helps in draining seroma/secretions to maximise graft take. Although we did not use negative suction, it can also be used through the syringe mould which can further improve the efficacy of mould.

CONCLUSION

Abbe-McIndoe vaginoplasty is a time-tested technique. The modified syringe-based mould offers an easy, swift, reproducible and cost-effective method to deal with special cases of MRKH presenting with haematometra or primary vaginal atresia patients. It offers distinct advantages of ease of dressing change and graft uptake even in cases not requiring drainage tube. This modification does not need any special instrumentation and so is easily reproducible at any centre.

Financial support and sponsorship

The study is not supported by any financial grant.

Conflicts of interest

There are no conflicts of interest.

REFERENCES

1. Bryan AL, Nigro JA, Counseller VS. One hundred cases of congenital absence of the vagina. *Surg Gynecol Obstet* 1949;88:79-86.

2. Opoku BK, Kwarteng RO. Transverse vaginal septum with menouria and unilateral renal agenesis: A case report. *Herbert Open Access J Gynaecol* 2015;3:1-4.
3. Nazir Z, Rizvi RM, Qureshi RN, Khan ZS, Khan Z. Congenital vaginal obstructions: Varied presentation and outcome. *Pediatr Surg Int* 2006;22:749-53.
4. Frank RT. The formation of an artificial vagina without operation. *Am J Obstet Gynaecol* 1938;35:1053-1055.
5. Rathee M, Boora P, Kundu R. Custom fabricated acrylic vaginal stent as an adjunct to surgical creation of neovagina for a young female with isolated vaginal agenesis. *J Hum Reprod Sci* 2014;7:272-5.
6. Miller RJ, Breech LL. Surgical correction of vaginal anomalies. *Clin Obstet Gynecol* 2008;51:223-36.
7. McIndoe AH, Banister AB. An operation to cure congenital absence of vagia. *J Obstet Gynaecol* 1938;45:490-494.
8. Fedele L, Frontino G, Motta F, Restelli E, Candiani M. Creation of a neovagina in Rokitansky patients with a pelvic kidney: Comparison of long-term results of the modified Vecchietti and McIndoe techniques. *Fertil Steril* 2010;93:1280-5.
9. Fritz MA, Speroff L. *Clinical Gynaecological Endocrinology and Infertility*. Philadelphia –Pennsylvania Lippincott's Williams and Wilkins; 2011.
10. de Souza AZ, Maluf M, Perin PM, Maluf Filho F, Perin LF. Surgical treatment of congenital uterovaginal agenesis: Mayer-Rokitansky-Küster-Hauser syndrome. *Int Surg* 1987;72:45-7.
11. Klingele CJ, Gebhart JB, Croak AJ, DiMarco CS, Lesnick TG, Lee RA. McIndoe procedure for vaginal agenesis: Long-term outcome and effect on quality of life. *Am J Obstet Gynecol* 2003;189:1569-72.
12. Adamson CD, Naik BJ, Lynch DJ. The vacuum expandable condom mold: A simple vaginal stent for McIndoe-style vaginoplasty. *Plast Reconstr Surg* 2004;113:664-6.
13. Barutçu A, Akgüner M. McIndoe vaginoplasty with the inflatable vaginal stent. *Ann Plast Surg* 1998;41:568-9.
14. Coskun A, Coban YK, Vardar MA, Dalay AC. The use of a silicone-coated acrylic vaginal stent in McIndoe vaginoplasty and review of the literature concerning silicone-based vaginal stents: A case report. *BMC Surg* 2007;7:13.

Author Help: Online submission of the manuscripts

Articles can be submitted online from <http://www.journalonweb.com>. For online submission, the articles should be prepared in two files (first page file and article file). Images should be submitted separately.

1) **First Page File:**

Prepare the title page, covering letter, acknowledgement etc. using a word processor program. All information related to your identity should be included here. Use text/rtf/doc/pdf files. Do not zip the files.

2) **Article File:**

The main text of the article, beginning with the Abstract to References (including tables) should be in this file. Do not include any information (such as acknowledgement, your names in page headers etc.) in this file. Use text/rtf/doc/pdf files. Do not zip the files. Limit the file size to 1 MB. Do not incorporate images in the file. If file size is large, graphs can be submitted separately as images, without their being incorporated in the article file. This will reduce the size of the file.

3) **Images:**

Submit good quality color images. Each image should be less than 4096 kb (4 MB) in size. The size of the image can be reduced by decreasing the actual height and width of the images (keep up to about 6 inches and up to about 1800 x 1200 pixels). JPEG is the most suitable file format. The image quality should be good enough to judge the scientific value of the image. For the purpose of printing, always retain a good quality, high resolution image. This high resolution image should be sent to the editorial office at the time of sending a revised article.

4) **Legends:**

Legends for the figures/images should be included at the end of the article file.