

Original Article

Functional outcomes of post-traumatic metacarpal hand reconstruction with free toe-to-hand transfer

Hari Venkatramani, Praveen Bhardwaj, Adam Sierakowski, S. Raja Sabapathy

Department of Plastic Surgery, Hand Surgery, Reconstructive Microsurgery and Burns, Ganga Hospital, Coimbatore, Tamil Nadu, India

Address for correspondence: Dr. S. Raja Sabapathy, Department of Plastic Surgery, Hand Surgery, Reconstructive Microsurgery and Burns, Ganga Hospital, 313, Mettupalayam Road, Coimbatore - 641 043, Tamil Nadu, India. E-mail: rajahand@gmail.com

ABSTRACT

Introduction: We present the functional outcomes of microvascular toe transfer to reconstruct the post-traumatic metacarpal hand deformity. Twelve toe transfers were successfully carried out in 11 patients. **Materials and Methods:** In each patient, the level of injury was classified according to the Wei classification system. Functional outcome was measured in seven patients using the Tamai score. Additional objective tests of function were carried out in three patients, including the Jepsen test, grip strength, pinch strength, web opening, static and moving two-point discrimination and Semmes–Weinstein monofilament testing. **Observation and Results:** The average Tamai score was 69 (range 60–83.5). Six patients achieved ‘good’ outcomes and one patient, with a double toe transfer, an ‘excellent’ outcome. The average follow-up time was 43 months (range 10–148 months). **Conclusion:** This study shows how even a single toe transfer can restore useful function to a hand that has otherwise lost all prehensile ability.

KEY WORDS

Functional outcome; metacarpal hand; microsurgery; reconstruction; toe transfer

INTRODUCTION

The post-traumatic metacarpal hand deformity is a devastating injury which deprives the hand of its primary function, prehension. The term ‘metacarpal hand’ refers to a hand with the complete loss of all fingers, with or without amputation of the thumb.^[1] The watershed at which the hand loses its prehensile ability appears to be when the fingers are amputated proximal to the middle of the proximal phalanx and the thumb is amputated proximal to the interphalangeal (IP)

joint. Based on this assumption, Wei *et al.* classified the deformity depending on the level of amputation of the digits and the functional status of the remaining thumb.^[2] Thus, a type 1 metacarpal hand refers to an amputation of all fingers proximal to the middle of the proximal phalanx, with either a normal thumb or a thumb amputated distal to the IP joint. In type 2 hands, all the fingers are amputated proximal to the middle of the proximal phalanx, with the thumb amputated proximal to the IP joint. Further sub-classification can be made

This is an open access article distributed under the terms of the Creative Commons Attribution-NonCommercial-ShareAlike 3.0 License, which allows others to remix, tweak, and build upon the work non-commercially, as long as the author is credited and the new creations are licensed under the identical terms.

For reprints contact: reprints@medknow.com

How to cite this article: Venkatramani H, Bhardwaj P, Sierakowski A, Sabapathy SR. Functional outcomes of post-traumatic metacarpal hand reconstruction with free toe-to-hand transfer. *Indian J Plast Surg* 2016;49:16-25.

Access this article online

Quick Response Code:



Website:

www.ijps.org

DOI:

10.4103/0970-0358.182232

depending on the adequacy of the thenar musculature and condition of the basal thumb joint [Table 1].

To restore useful prehensile function to the hand in these situations is a challenge for the reconstructive surgeon. Before even considering how to reconstruct the digits, there is often a skin shortage at the distal stump which must be addressed. Depending on the time at which the patient presents, there may also be dense scarring to contend with and a contracted first web space which requires release. With regard to the digits, microvascular toe transfer is the predominant method of reconstruction and has been used by several authors in various combinations.^[3-9] While success

using this procedure has frequently been reported, objective functional outcome data are relatively lacking. To help quantify the benefits of toe-to-hand transfer for the reconstruction of the metacarpal hand, we have undertaken objective functional assessment of our patients whenever possible. This paper presents our experience with 11 patients, spanning the entire spectrum of metacarpal hand injuries.

METHODS

Twelve toe-to-hand transfers were carried out in 11 patients between August 2002 and January 2014 [Table 2]. The patients were all men, aged between 18 and 52 years (average age 29 years) who had sustained traumatic, mutilating hand injuries. Except for patient 8, whom we treated immediately following the injury, all patients underwent initial debridement and wound closure at a local hospital before being referred to us. Eight patients required a pedicled flap to provide soft tissue cover to the stump before undergoing toe transfer. The average interval from injury to flap cover was 5 days (range 0–20 days) and from injury to toe transfer surgery was 5 months (range 2–12 months).

Classification of metacarpal hand injury

The extent of injury in each case was classified according to the system proposed by Wei *et al.*^[2] [Figure 1]. An anterior/posterior radiograph of the affected hand was

Table 1: Classification of metacarpal hand according to Wei *et al.*

Type 1	Level of amputation of fingers
1A	Distal to the MCP joint
1B	Through the MCP joint, with intact articular surface
1C	Through the MCP joint, with damaged metacarpal articular surface, or proximal to the MCP joint
Type 2	Level of amputation of thumb
2A	Distal to the metacarpal neck
2B	Proximal to the metacarpal neck with adequate thenar muscle function
2C	Any level with inadequate thenar musculature
2D	Any level with damaged CMC joint

In type 1 metacarpal hand all fingers are amputated proximal to the middle of the proximal phalanx with either a normal thumb or thumb amputated distal to the IP joint. In type 2 metacarpal hand, all fingers are amputated proximal to the middle of the proximal phalanx with thumb amputation proximal to the IP joint. MCP: Metacarpophalangeal, CMC: Carpometacarpal, IP: Interphalangeal

Table 2: Patient demographics and details of reconstruction performed

Patient number	Age (years)	Occupation	Injury type	Wei class	Pedicled flap cover of stump	Interval from injury to flap cover (days)	Transferred toe	Position of toe transfer	Interval from injury to toe transfer (months)	Recipient artery and vein
1	52	Engineer	Crush	1A	Groin flap	5	2 nd	Index	3	UA, CV
2	25	Labourer	Crush/ avulsion	1A	Groin flap	20	2 nd	Index	4	RA, CV
3	22	Shopkeeper	Crush/ avulsion	1A	Not required	N/A	2 nd	Index	5	CDA, CV
4	50	Labourer	Crush	1B	Groin flap	6	2 nd	Middle	4	UA, CV
5	18	Student	Crush	2A	Hypogastric flap	2	Great and 2 nd	Thumb and ring	Great: 2 2 nd : 7	Great: RA, CV 2 nd : UA, DV
6	29	Farmer	Crush	2A	Not required	N/A	2 nd	Little	9	UA, DV
7	32	Businessman	Crush	2A	Groin and para-umbilical flap*	0	2 nd	Middle	9	UA, CV
8	34	Labourer	Crush	2A	Groin and hypogastric flap	0	2 nd	Thumb	2	RA, CV
9	22	Farmer	Crush	2B	Not required	N/A	Great	Thumb	4	RA, CV
10	21	Farmer	Crush/ avulsion	2C	Groin and para-umbilical flap	4	2 nd	Thumb	2	RA, CV
11	15	Student	Blast	2D	Hypogastric flap*	0	2 nd	Thumb	12	RA, CV

*Pedicled flap cover of amputation stump(s) was performed elsewhere, prior to patient being treated by us. UA: Ulnar artery, RA: Radial artery, CV: Cephalic vein, CDA: Common digital artery, DV: Dorsal hand vein

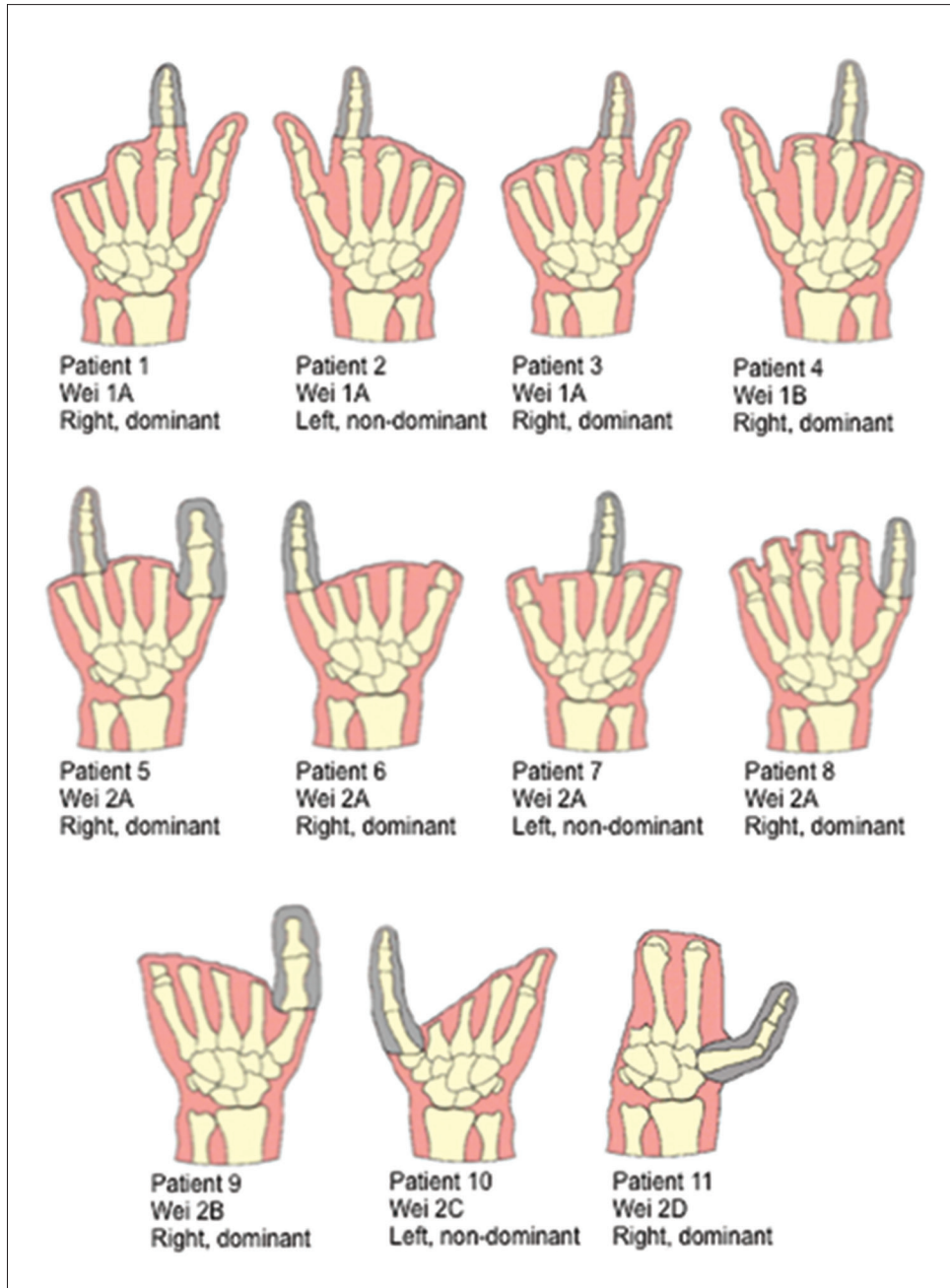


Figure 1: Schematic representation of patients who underwent reconstruction for the metacarpal hand deformity, arranged according to the Wei classification. Transferred toes are illustrated in grey

used to allow accurate determination of the level of injury. In type 1 cases where fingers were injured at different levels, the level of injury of the reconstructed finger was used for the purpose of classification. Patient 6 sustained bilateral metacarpal hand injuries, but only his right hand has been included in the study as the left hand is yet to undergo reconstruction.

Technique of toe transfer

All operations were carried out by the senior author (SRS), as part of one surgical team, under regional anaesthesia.

The second toe was transferred in all patients, except patient 9 who had only a great toe transfer. Patient 5 had a great toe and a second toe transferred, in that order, with 5 months between transfers.

The first stage of surgery is always to explore the recipient hand. This takes place under brachial block anaesthesia under tourniquet control. Skin flaps are raised and the stump is explored for recipient structures. The recipient bone end is cleared of scar tissue and freshened in preparation for toe fixation. Recipient nerve ends are

tagged for ease of localisation. We routinely connect two volar and two dorsal digital nerves.

For toes transferred to a finger position, the flexor digitorum profundus and extensor digitorum communis tendons are used as motors. For thumb reconstructions we attach the flexor pollicis longus tendon to the toe flexors, extensor pollicis brevis to extensor digitorum brevis and extensor pollicis longus to extensor digitorum longus. A thorough tenolysis of the recipient tendons must be performed to free them from scar tissue and ensure they have the adequate pull to motor the transfer.

For thumb reconstruction, our preferred recipient vessels are the cephalic vein and radial artery at the level of the anatomical snuff box, which can be accessed by extending the incision from the stump. For finger reconstruction, the ulnar artery at the level of Guyon's canal is often in a more convenient location, sometimes combined with a dorsal hand vein. Anastomoses are performed end-to-end whenever possible.

The technique of toe harvest is similar to that described by Wei *et al.*^[2] This is performed under combined spinal/epidural anaesthesia. The vascular pedicle is identified early in the first web space and the junction of the lateral digital artery of the great toe and the medial digital artery of the second toe is identified and followed proximally to identify the dominant vessel. In this series of 12 toes, seven were dorsal dominant and five plantar dominant. We give 2500 units of intravenous heparin at the time of arterial clamp release and continue to give 5000 units of heparin over 24 h for 5 days.

Toe fixation is achieved with a single axial 1.25 mm K-wire in each case. Rotational stability is secured by two to three sutures placed through the capsule/periosteum surrounding the bone ends. The metatarsophalangeal joint was included in two transfers (patients 10 and 11). Otherwise, the base of the toe proximal phalanx was freshened and attached to the stump and the toe metatarsal preserved. Since a single toe was used for reconstruction in most of the cases, the transfer was placed so that it would enable a pinch grip with the opposing stump or thumb. The donor site in the foot was closed primarily in all cases and the foot protected in a below-knee plaster slab.

Great care is taken not to place any tension or undue pressure on the vascular pedicle. We, therefore, suture

the overlying skin loosely and have a low threshold for using skin grafts.

Post-operative care and rehabilitation

Patients spend 3 days in a microvascular high dependency unit before being transferred to a plastic surgery ward. They remain in an above elbow cast until a dressing change under anaesthesia at 10 days. As most of these patients live several 100 km away, we routinely keep them as inpatients until at least the time of suture removal at 2 weeks. The K-wires are removed at 4–6 weeks, after which active mobilisation of the toe transfer is commenced. Weight bearing on the donor's foot is allowed after 1 week.

Assessment of outcome

Complete subjective and objective assessment of the reconstructed hand consisted of the following components:

Tamai score

This was originally designed by Tamai *et al.* to assess hand function after thumb or finger replantation.^[10] Since that time, it has been adapted and used successfully for the assessment of function in the metacarpal hand after toe transfer.^[3] The assessment consists of a questionnaire and a clinical examination and has both subjective and objective components. Patients are asked to rate their ability to perform 20 activities of daily living as either easy, difficult or impossible. They are also asked to rate subjective symptoms (e.g., pain and cold intolerance) and cosmetic deformities (e.g. scar, angulation) as either mild, moderate or severe. Patient satisfaction is graded as either highly satisfied, fairly satisfied, satisfied, poorly satisfied or not satisfied. Patients are asked if they remain in the same job since the injury, have had to change job, or are no longer able to work.

Sensation is evaluated according to the British Medical Research Council criteria. Scores for motion differ depending on whether a finger or a thumb (or combinations therein) have been replanted. For the purpose of this study, the toe transfer was scored depending on whether it was transferred to a finger or the thumb position. Scores for finger motion are given only for the total active range of motion, whereas scores for the thumb also incorporate the ability to oppose.

The Tamai score is calculated out of 100 and graded as follows: Excellent, 100–80; good, 79–60; fair, 59–40 and poor 39–0.

In addition to the standard Tamai score questions, patients were also asked if, given their experience, they would have the same surgery again to treat their injury.

Jebsen hand function test

This is an objective test of global hand function performed by measuring the time taken to carry out specific manual tasks.^[11] The test items include a range of fine motor, weighted and non-weighted hand activities, viz., writing (copying) a 24-letter sentence, turning over 3 × 5 inch cards, picking up small common objects such as a paper clip, bottle cap and coin, simulated feeding using a teaspoon and five kidney beans, stacking checkers, picking up large light objects (empty tin can) and picking up large heavy objects (1 lb tin can). The injured hand is compared to the contralateral, normal hand.

Objective tests of movement, strength and sensibility

The opening of the web during maximal extension between the transferred toe and the stump or between two opposing transfers was measured. This was done by measuring with a ruler the distance between the edge of the nail of the transfer and the opposing surface, whether it was the stump or the other transferred toe. A goniometer was used to measure the active range of movement of the toe transfers. It is difficult to measure reliably the range movement at the distal IP (DIP) joint of the second toe, so the DIP and proximal IP joints were considered as one IP joint. None of the toes measured had a mobile metacarpophalangeal (MCP) joint.

Strength was measured as pinch strength (pulp-to-pulp pinch or pulp-to-lateral pinch, depending on what the patient was able to do) and grip strength using a Jamar dynamometer. The reported value for strength is the best of three consecutive attempts. Measurements were compared to those obtained in the contralateral, uninjured hand. Sensibility was measured from the pulp of each of the toe transfers with Semmes–Weinstein monofilaments and static (s2PD) and moving (m2PD) two-point discrimination (2PD).

By the time of assessment, patients 2, 8, 9, and 10 were no longer contactable for review.

Patients 1, 3, 6 and 7 lived several 100 km away and were unable to attend for physical assessment. These patients underwent telephone interview to answer the components of the Tamai score relating to activities of

daily living, sensation, subjective symptoms, cosmesis, patient satisfaction and job status. To score the motion component of the Tamai score, video recordings of the patients attempting full active flexion and extension in the toe transfer at their most recent therapy appointment were used. This was sufficient to be able to place each toe into one of the brackets for total active range of movement (i.e., more than 151°, 111–150°, 71–110°, <70° and a stiff digit) with reasonable certainty.

Patients 4, 5 and 11 were able to attend for full assessment consisting of the Tamai score, Jebsen hand function test, the total active range of movement in the toe transfer(s), grip strength, pinch strength, web opening, static and moving 2PD and Semmes–Weinstein monofilament testing.

RESULTS

A total of 12 toe transfers were performed in 11 patients during the 12-year period [Table 2]. The average follow-up time from toe transfer surgery to assessment was 43 months (range 10–148 months).

In the seven patients who underwent assessment, the average Tamai score was 69 (range 60–83.5) [Table 3]. Six patients achieved ‘good’ outcomes and one patient, with a double toe transfer, an ‘excellent’ outcome. All patients were either ‘satisfied’ or ‘highly satisfied’ with the outcome, except for patient 11 who had the most severe 2D-type injury and rated the outcome as ‘adequate’.

Sensation in the transferred toe ranged from normal (S4) in one patient to skin touch, pain and temperature sensation (S2) in three patients. The only subjective symptom reported was mild pain in the reconstructed hand by three of the patients. Symptoms such as cold intolerance, numbness, paraesthesia and tightness were not considered a problem. The average cosmesis score out of 10 was 6 (range 3–8). Five patients remained in the same employment as before the injury and two were no longer able to work. All seven patients said that they would be willing to have the same operation again.

Three patients completed objective functional testing in addition to the Tamai score [Table 4]. These patients were type 1B, 2A and 2D and the configuration of their reconstructed hands differed considerably [Figures 2–4].

Table 3: Tamai score, including breakdown of results for subjective components, work status post and whether patient would have same surgery again

Patient number	Wei class	Follow-up (months)	Tamai score	Overall satisfaction	Sensation	Pain	Cosmesis score	Occupation since injury	Would have same surgery again
1	1A	64	73.5, good	Highly satisfied	S2	Mild	8	Unchanged	Yes
3	1A	10	74, good	Highly satisfied	S2	Mild	7	Unchanged	Yes
4	1B	15	63, good	Satisfied	S3	None	7	Unemployed, unable to work	Yes
5	2A	148	83.5, excellent	Highly satisfied	S3	None	7	Unchanged	Yes
6	2A	20	60, good	Satisfied	S4	None	5	Unemployed, unable to work	Yes
7	2A	11	68.5, good	Highly satisfied	S2	Mild	7	Unchanged	Yes
11	2D	31	63, good	Adequate	S3+	None	3	Unchanged	Yes

Tamai score is out of 100 - Excellent: 100-80, Good: 79-60, Fair: 59-40, Poor: 39-0. Sensation is graded according to MRC criteria - S0: No sensation, S1: Deep proprioception, S2: Skin touch, pain and temperature sensation, S3, S2 with accurate localisation but deficient stereognosis, S3+, object and texture recognition but not normal sensation, good but not normal two-point discrimination, S4, normal sensation. Cosmesis is scored out of 10, with 10 being the best, MRC: Medical Research Council

Table 4: Objective functional outcome data

	Patient 4	Patient 5	Patient 11
Wei class	1B	2A	2D
Follow-up (months)	15	148	31
Web opening (mm)	15-145	0-85	0-45
Total AROM in toe transfer	20-60	Great: 50-85 2 nd : 65-90	0-65
Grip strength (kg)	0.5 (44)	2.0 (28)	N/P
Pinch strength (kg)*	5.0 (7.5)	2.5 (5.5)	N/P
Static 2PD (mm)	10	Great: 11 2 nd : 11	8
Moving 2PD (mm)	10	Great: 11 2 nd : 11	6
S-W monofilament	4.56	Great: 3.61 2 nd : 3.61	4.31

For grip and pinch strength, values from the contralateral, uninjured, hand are shown in parentheses. For: Semmes-Weinstein monofilaments, 3.61 denotes diminished light touch, 4.31 diminished protective sensation, 4.56 loss of protective sensation.*Pinch strength in patient 4 is for key pinch, while that in patient 5 is for pulp-to-pulp pinch. AROM: Active range of movement, N/P: Not possible to test, 2PD: Two-point discrimination

The average follow-up for these patients was 65 months (range 15–148 months). The average web opening was 87 mm (range 45–130 mm) and the average total range of movement in the transferred toe(s) was 41° (range 25–65°). Patient 11 was unable to grip the dynamometer or use the pinch gauge as his hand consisted only of a 2nd toe in the thumb position articulating with a fingerless hand.

Whether or not a patient could perform key pinch or pulp-to-pulp pinch depended upon the individual reconstruction. Thus, patient 5 was able to achieve pulp-to-pulp pinch strength of 2.5 kg (45% of uninjured hand) and patient 4 a key pinch of 5 kg (67% of uninjured hand). It was difficult for both patients to grip the dynamometer and consequently grip strength was considerably weaker than the uninjured hand at 2 kg (7%

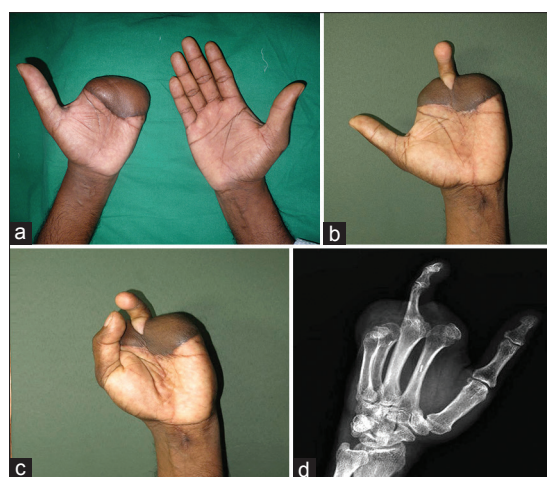


Figure 2: Patient 4, type 1B metacarpal hand. (a) Both hands, prior to toe transfer showing well-settled groin flap covering stump of left hand. (b) Left hand following 2nd toe transfer to the middle finger position, showing maximum span and (c) attempting full opposition. (d) Oblique radiograph 15 months following toe transfer showing bony union

of uninjured hand) and 0.5 kg (1% of uninjured hand), respectively.

Sensory outcomes varied considerably. Patient 4 achieved only loss of protective sensation and a static and moving 2PD of 10 mm, although this might be a reflection of his relatively short follow-up time of 15 months. Patient 5, 148 months following surgery, achieved diminished light touch in both of his transferred toes and static and moving 2PD of 11 mm. Patient 11 achieved the best outcome with regards to 2PD (8 mm static and 6 mm moving), although this did not translate to the best outcome on monofilament testing.

The results of the Jebsen hand function test are shown in Table 5. All three patients were able to perform all of

Table 5: Results of the Jebsen hand function test

Test component	Time taken (s)		
	Patient 4	Patient 5	Patient 11
	Wei Class 1B	Wei Class 2A	Wei Class 2D
Writing	Unable (15)	21 (51)	49 (13)
Card turning	10 (9)	9 (6)	15 (7)
Small common objects	20 (7)	17 (6)	26 (5)
Simulated feeding	12 (7)	11 (10)	36 (10)
Checkers	10 (4)	5 (4)	14 (4)
Large light objects	18 (7)	8 (5)	10 (4)
Large heavy objects	17 (7)	8 (5)	53 (4)

Values from the contralateral, uninjured, hand are shown in parentheses. In patient 4, the uninjured hand was the dominant hand. In patients 5 and 11, the uninjured hand was the non-dominant hand

the tasks, except patient 4 who was unable to write with his reconstructed hand. This was because his thumb was unable to fully oppose to the transferred toe, leaving a gap of 15 mm on maximum effort. As a result, he was unable to grip the pen sufficiently to prevent it falling out of his grasp. For picking up small common objects, he was able to ‘cheat’ by gripping the objects between his thumb and the radial border of the hand.

The best results were seen in patient 5, whose reconstructed hand was also his dominant hand. The overall time taken to complete the tasks was 9% faster in the reconstructed hand, mainly due to the relative ease with which he could write with this hand. The slowest results are seen in patient 11 (type 2D), who struggled with holding the pen steady and with lifting large heavy objects.

None of the toe transfers failed and no patients have required secondary procedures at the time of writing. All our transferred toes have achieved bony union using single axial K-wire fixation, as confirmed by follow-up radiographs [Figures 2-4]. All our patients are able to walk with a normal gait and continue to wear sandals or flip-flops [Figure 5].

DISCUSSION

The term ‘metacarpal hand’ may refer to any of a range of deformities which result from severe, mutilating trauma to the hand. These vary in terms of severity and, therefore, the type of reconstruction that is required. In addition to this, the individual needs of the patient must be considered, in order to provide the function that will be of most use to them in their daily life, while balancing the drawbacks of any donor site morbidity.

Metacarpal hand injuries were classified by Wei *et al.* in 1997, based on the level of amputation of the remaining

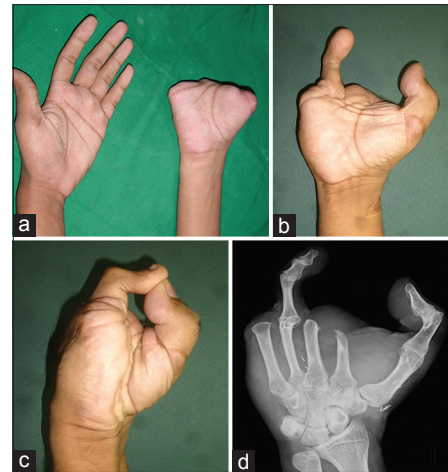


Figure 3: Patient 5, type 2A metacarpal hand. (a) Both hands, prior to toe transfer. (b) Right hand following great toe transfer to the thumb position and 2nd toe transfer to the ring finger position, showing maximum span and (c) full opposition. (d) Oblique radiograph 148 months following toe transfer showing bony union of both transfers

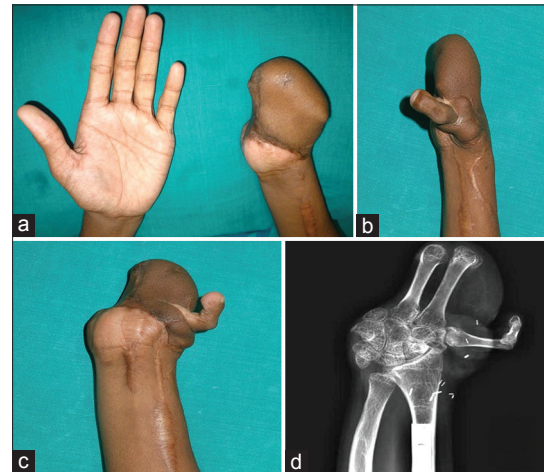


Figure 4: Patient 11, type 2D metacarpal hand. (a) Both hands, prior to toe transfer, showing hypogastric flap cover to left hand (b) Left hand following 2nd toe transfer to the thumb position, showing maximum span and (c) attempting full opposition. (d) Oblique radiograph 31 months following toe transfer showing bony union

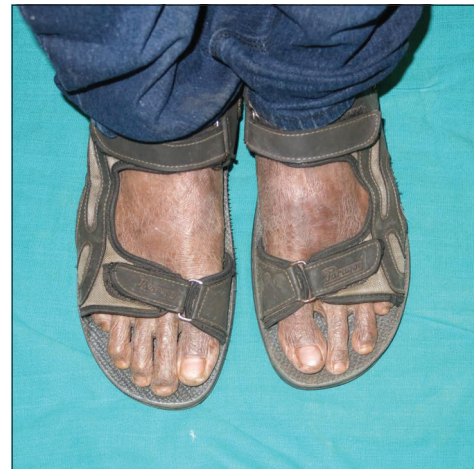

Figure 5: Feet of patient 11, 2 years following left 2nd toe harvest. Donor site morbidity is minimal

digits and the functional status of the remaining thumb.^[2] Over the years, we have encountered at least one of each type of metacarpal hand (with the exception of type 1C) and performed functional reconstruction using the toe-to-hand transfer. Where possible, we have evaluated the outcome using both subjective and objective tests.

Due to the rarity of this type of injury there are few series with which to compare our results and fewer still that provide objective functional outcome data. The most recent and most comprehensive analysis of metacarpal hand reconstructions has been by Kotkansalo *et al.*^[3] In their article, the authors summarise 14 previous studies reporting on metacarpal hand reconstruction and highlight the lack of objective outcome data available. Eight articles provide objective information regarding the range of motion achieved in the transferred toe (s) (ranging from 25° to 116° at the IP joints) and only two provide objective functional outcome data based on the Jebsen hand function test.^[12,13]

Kotkansalo *et al.* themselves report on eight patients with type 2 injuries who underwent reconstruction by 11 toe-to-hand transfers.^[3] The average follow-up time was 12 years. Six of these patients underwent single toe transfer, of which five were to the thumb position and one to the little finger position. One patient underwent a double toe transfer to the thumb and little finger positions and one a triple toe transfer to the middle, ring and thumb positions. All except one patient were satisfied or highly satisfied with the result, but only two returned to the same work as before the accident. The average modified Tamai score was 63 (good) and the average Sollerman hand function test score was 54/80 (79/80 for uninjured hand). Static 2PD was ≤ 10 mm in only two of the 11 transfers and moving 2PD ≤ 10 mm in only one of the transfers. Sensibility based on the Semmes–Weinstein monofilament test ranged from diminished light touch to loss of protective sensation. These results are broadly similar to what we have found in terms of patient satisfaction, function, and sensibility achieved in the reconstructed hand.

The ultimate success of metacarpal hand reconstruction is determined by the very first operation the patient undergoes. As we have experienced, this often takes place in emergency circumstances at a hospital local to where the injury occurred and is consequently beyond our control. Ideally, every effort should be made to try and preserve bone length, in particular, to spare the MCP

joints of the fingers or IP joint of the thumb, even if a very short phalangeal stump remains. The residual joint will improve the mobility of a future toe transfer and allow greater functional dexterity.

The majority of patients will require some form of flap reconstruction to provide soft tissue cover for the amputation stump(s). A pedicled flap based on either the superficial circumflex iliac or superficial inferior epigastric vessels (or both for very large defects) is our flap of choice as it is reliable, versatile and spares any recipient vessels for future microvascular anastomosis. As we have recently reported, proper planning of the pedicled groin flap sets the stage for successful completion of the reconstruction, particularly when the thumb is involved.^[14] Two factors have to be considered: The length of the flap and the direction in which it is inset. For example, a longer flap is required for more proximal (type 2D) injuries that might require a length of metatarsal to be transferred along with the toe. For optimum aesthetic results, the flap should be inset so that the apex points in the direction of the future thumb. At the time of toe transfer, the flap can be split into two from the apex to gain access to the base of the thumb and safely thinned and re-draped as required.

An equally important determinant of outcome is the maintenance of the first web space, which must be rigorously guarded. The high level of function achieved in patient 5 was only possible because the first web space was protected at the time of placing a hypogastric flap. This was achieved by placing a specially designed Kwire, bent into a three-dimensional 'V' shape, between the 1st and 2nd metacarpals to act as an internal splint [Figure 6], as described by Lees *et al.*^[15] If left

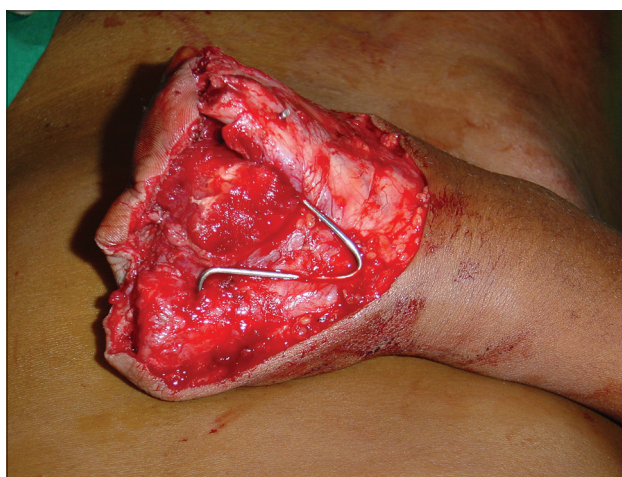

Figure 6: Intraoperative photograph of patient 5's right hand prior to cover with a pedicled hypogastric flap. A K-wire bent into the shape of a 'V' is wedged between the 1st and 2nd metacarpals to prevent contracture of the 1st web space

unprotected, the adductor pollicis will contract and the outcome will be severely affected.

All of our patients with type 1 metacarpal hands underwent reconstruction with a single toe transfer. This contrasts to Wei *et al.*, who recommend transfer of two toes in order to reconstruct tripod pinch.^[2,5-7,16-19] Amongst the benefits of double toe transfer, they cite increased lateral stability, a wider span and stronger hook grip. Similarly, in metacarpal hand type 2, they recommend two toes for finger reconstruction and one for thumb reconstruction. We have transferred just a single toe in all of our type 2 patients, with the exception of patient 5.

Unfortunately, a lack of functional outcome data to support the recommendations made by Wei *et al.* means that it is impossible to make objective comparisons between single versus multiple toe transfers in metacarpal hand reconstruction. While reconstruction with multiple toes may have functional and aesthetic advantages for the hand, the toll taken on the foot is considerably greater. Indeed, this is often too great for a patient to accept in a culture where sandals are worn daily and the feet are constantly on display. Nevertheless, our results show that satisfactory results can be obtained with even a single toe transfer in these situations. Of the three type 1 patients that completed the Tamai assessment following single second toe transfer, all achieved 'good' outcomes and were either satisfied or highly satisfied with their result.

The decision as to where to place the toe should be made in conjunction with the patient and take into account any specific functional requirements. In the case of finger replantation after multiple amputations, there is a strong argument for avoiding the second ray in favour of more ulnar reattachment. When combined with resection of the second metacarpal, the result is a more functional and cosmetically acceptable hand.^[20,21] However, a second toe is considerably shorter and less mobile than a finger, especially when the proximal phalanx of the toe is arthrodesed to the metacarpal. As a result, pinch grip and fine manipulative tasks become difficult, if not impossible, if the toe is transferred to the ulnar side of the hand. Conversely, span grip is improved, which may be an advantage in some labourers. Our own subjective opinion is that when a single toe is transferred, the result is cosmetically more acceptable when it is placed at the radial or ulnar border of the hand compared to a central position. Based on this combination of factors, our preferred position for a single toe transfer in most patients has come to be the index finger position.

Where two toe transfers are planned, we prefer to transfer the great toe first. Once this toe is moving freely, we are better able to position the second toe in a position where full pinch will be achieved. In patient 5, this so happened to be in the ring finger position.

Patient 4, in whom the toe was attached directly to the metacarpal head of the middle finger, achieved the lowest score among our type 1 patients. In this case, the transferred toe relied solely on its IP joints for flexion, without the benefit of a preserved MCP joint. Analysis of the post-operative radiograph [Figure 2d] reveals that the toe was placed a few degrees too dorsal on the metacarpal head, meaning the patient was unable to oppose fully to the thumb. This resulted in difficulties holding a pen and picking up small objects. This highlights the critical importance of positioning of the transferred toe such that contact with the opposing thumb tip is guaranteed.

In type 2 metacarpal hand, the adequacy of the remaining thenar musculature and the condition of the basal thumb joint are the prime determinants of the functional capability of any reconstruction.^[2,16] Within any type 2 subtype, however, the extent of finger loss may vary considerably (from type 1A to 1C) and this is not accounted for in the Wei classification system. This is illustrated by the different reconstructions that patients with a 2A injury underwent in our series. In patient 8, a single toe transfer to the thumb position was sufficient to allow prehension, as the remaining finger length was at the proximal phalangeal level. Contrast this to patient 5, in whom all the fingers were amputated at the distal metacarpal level and required reconstruction of both the thumb and a finger. This patient went on to achieve an 'excellent' outcome according to the Tamai criteria, with a score of 83.5 out of 100 and a high level of satisfaction.

Patients 6 and 7, with similar type 2A deformities, but with slightly longer residual thumbs, achieved only 'good' outcomes following toe transfers to the little and middle finger rays, respectively. These patients would likely achieve similar scores to patient 5 were they to undergo toe transfer to reconstruct the thumb. However, neither patient wishes to undergo any further surgery at this stage.

Three patients completed the full complement of assessments, including the Tamai score and objective functional outcome tests including the Jebsen hand function test. These patients were of type 1B, 2A and 2D and, therefore, represented different points along the spectrum of severity. It is notable

that, even following the complete loss of the thumb metacarpal and with only two remaining finger metacarpals, a 'good' outcome on the Tamai score can be achieved by a single second toe transfer to the thumb position in a type 2D patient (patient 11). In functional tests, this patient was able to hold a pen, feed himself and pick up various sized objects by grasping them between the toe and what remains of the hand, using only flexion at the toe IP joints.

The best overall results are seen in patient 5, a type 2A deformity, in whom intact thenar musculature and well-positioned toe transfers combine to make a very functional hand. This patient could achieve a grip strength of 2 kg and was able to complete the writing task faster in his dominant reconstructed hand, than his non-dominant uninjured hand.

It has been our general observation that sensory recovery in the transferred toes steadily improves with time, sometimes over several years. This is borne out in the Semmes–Weinstein monofilament test results, though not in terms of static or moving 2PD. Patient 6 reported entirely normal sensation in the transferred toe after 20 months, but there were no means of testing this objectively.

The mean cosmesis score in the Tamai assessment was 6 out of 10 (range 3–8). This is based on a subjective self-assessment by each patient. The original purpose of this part of the Tamai score was to evaluate the appearance of a hand after digit replantation. There are obvious limitations when trying to adapt this for evaluation of a metacarpal hand after toe transfer, as the hand is so far from 'normal' in appearance. How the patient scores their hand is also bound to be affected by their psychological response to the injury and how they have come to accept the reconstruction. The fact remains that a cosmetically attractive hand is not the goal of management, or even a possibility, rather a hand that is functionally useful.

CONCLUSION

Toe-to-hand transfer offers a reliable and effective means of restoring useful function to a metacarpal hand that has otherwise lost all prehensile ability. In type 1 metacarpal hand, a single toe transfer can provide high patient satisfaction and sufficient function to allow a return to work, while minimising donor site morbidity. Certain type 2 injuries can function adequately with a single toe transfer, but for optimum results, it would appear from our limited data that at least two toe transfers are required.

Financial support and sponsorship

Nil.

Conflicts of interest

There are no conflicts of interest.

REFERENCES

1. Michon J, Dolich BH. The metacarpal hand. *Hand* 1974;6:285-90.
2. Wei FC, el-Gammal TA, Lin CH, Chuang CC, Chen HC, Chen SH. Metacarpal hand: Classification and guidelines for microsurgical reconstruction with toe transfers. *Plast Reconstr Surg* 1997;99:122-8.
3. Kotkansalo T, Vilkki SK, Elo P. The functional results of post-traumatic metacarpal hand reconstruction with microvascular toe transfers. *J Hand Surg Eur Vol* 2009;34:730-42.
4. Leung PC. Thumb reconstruction using second-toe transfer. *Hand Clin* 1985;1:285-95.
5. Tan BK, Wei FC, Lutz BS, Lin CH. Strategies in multiple toe transplantation for bilateral type II metacarpal hand reconstruction. *Hand Clin* 1999;15:607-12, viii.
6. Tan BK, Wei FC, Chang KJ, Lutz BS, Chen SH. Combined third and fourth toe transplantation. *Hand Clin* 1999;15:589-96, viii.
7. Wei FC, Jain V, Chen SH. Toe-to-hand transplantation. *Hand Clin* 2003;19:165-75.
8. Wei FC, Yim KK. Single third-toe transfer in hand reconstruction. *J Hand Surg Am* 1995;20:388-94.
9. Wei FC, el-Gammal TA. Toe-to-hand transfer. Current concepts, techniques, and research. *Clin Plast Surg* 1996;23:103-16.
10. Tamai S, Michon J, Tupper J, Fleming J. Report of subcommittee on replantation. *J Hand Surg Am* 1983;8:730-3.
11. Jebben RH, Taylor N, Trieschmann RB, Trotter MJ, Howard LA. An objective and standardized test of hand function. *Arch Phys Med Rehabil* 1969;50:311-9.
12. Chung KC, Kotsis SV. Outcomes of multiple microvascular toe transfers for reconstruction in 2 patients with digitless hands: 2- and 4-year follow-up case reports. *J Hand Surg Am* 2002;27:652-8.
13. Williamson JS, Manktelow RT, Kelly L, Marcuzzi A, Mahabir RC. Toe-to-finger transfer for post-traumatic reconstruction of the fingerless hand. *Can J Surg* 2001;44:275-83.
14. Sabapathy SR, Venkatramani H, Bhardwaj P. Reconstruction of the thumb amputation at the carpometacarpal joint level by groin flap and second toe transfer. *Injury* 2013;44:370-5.
15. Lees VC, Wren C, Elliot D. Internal splints for prevention of first web contracture following severe disruption of the first web space. *J Hand Surg Br* 1994;19:560-2.
16. Lam WL, Wei FC. Toe-to-hand transplantation. *Clin Plast Surg* 2011;38:551-9.
17. Wallace CG, Wei FC. Posttraumatic finger reconstruction with microsurgical transplantation of toes. *Hand Clin* 2007;23:117-28.
18. Wei FC, Colony LH, Chen HC, Chuang CC, Noordhoff MS. Combined second and third toe transfer. *Plast Reconstr Surg* 1989;84:651-61.
19. Lutz BS, Wei FC, Chen SH, Lin CH. Functional reconstruction of the metacarpal hand with multiple toe transplantations. *Tech Hand Up Extrem Surg* 1999;3:37-43.
20. Rose EH, Buncke HJ. Selective finger transposition and primary metacarpal ray resection in multidigit amputations of the hand. *J Hand Surg Am* 1983;8:178-82.
21. Elliot D, Henley M, Sammut D. Selective replantation with ulnar translocation in multidigital amputations. *Br J Plast Surg* 1994;47:318-23.