

Original Article

Presurgical nasopalveolar moulding in unilateral cleft lip and palate

Mohammed Zuhaib, Krishnamurthy Bonanthaya, Renu Parmar, Pritham N. Shetty, Pradeep Sharma

Department of Oral and Maxillofacial Surgery, Bhagwaan Mahaveer Jain Hospital, Bengaluru, Karnataka, India

Address for correspondence: Dr. Mohammed Zuhaib, Department of Oral and Maxillofacial Surgery, Bhagwaan Mahaveer Jain Hospital Bengaluru, Karnataka, India. E-mail : dr.mohammedzuhaib@gmail.com

ABSTRACT

Context: Presurgical nasopalveolar moulding (PNAM) is a non-surgical method of reshaping the cleft lip, alveolus, palate and the nose to minimize the severity of the cleft deformity, before primary cheiloplasty and palatoplasty. In this context, PNAM proves to be an invaluable asset in the management of unilateral cleft lip and palate. **Aims:** The study was conducted to evaluate the efficacy of PNAM in the management of unilateral cleft lip and palate with the following objectives: (1) To assess and compare the degree of reduction in the size of cleft palate and alveolus (pre-PNAM and post-PNAM). (2) To evaluate and compare the improvement in columellar length and correction of columellar deviation (pre-PNAM and post-PNAM). (3) To assess the changes in the position of the alar base and the alar cartilages. **Settings and Design:** Prospective study. **Subjects and Methods:** A prospective study consisting of, which included 20 patients with complete unilateral cleft lip and palate was conducted. The age at the start of PNAM treatment of the infants ranged from 2 to 44 days of age reporting to our institute between December 2011 and August 2013. All the patients underwent PNAM therapy before primary cheiloplasty at 6 months of age; clinical parameters were assessed pre- and post-therapy using photographs and dental study models of the maxilla. **Statistical Analysis Used:** Student's t-test for paired comparisons. **Results:** Results of the study showed a promising reduction in the cleft size before the surgery, significant improvement in nasal symmetry, including the columellar length on the cleft side. **Conclusions:** PNAM is a valuable adjunct to our surgical armamentarium in dealing with the challenges of primary closure of unilateral cleft lip and palate thereby enhancing the overall surgical outcome. The advantages of this method include the simplicity of the procedure and improving the quality of surgical repair, particularly in obtaining tension free muscle closure in unilateral clefts.

KEY WORDS

Nasal moulding bulb; presurgical nasopalveolar moulding; unilateral cleft lip and palate

Access this article online	
Quick Response Code: 	Website: www.ijps.org
	DOI: 10.4103/0970-0358.182235

This is an open access article distributed under the terms of the Creative Commons Attribution-NonCommercial-ShareAlike 3.0 License, which allows others to remix, tweak, and build upon the work non-commercially, as long as the author is credited and the new creations are licensed under the identical terms.

For reprints contact: reprints@medknow.com

How to cite this article: Zuhaib M, Bonanthaya K, Parmar R, Shetty PN, Sharma P. Presurgical nasopalveolar moulding in unilateral cleft lip and palate. Indian J Plast Surg 2016;49:42-52.

INTRODUCTION

Clefts of lip and palate are the most common congenital defects involving the orofacial region. The primary goal of the treatment in the cleft patients is to restore normal anatomy and function.^[1,2]

Reconstruction of the symmetrical lip and a natural looking nose is a difficult challenge in unilateral clefts.^[3] Over the last two decades, the surgical technique has been improved considerably through a better understanding of the primary pathology and an integrated multidisciplinary approach.^[2,4]

This consists of the following:

- Presurgical management to reduce the initial deformity
- Modification of surgical techniques leading to improved soft tissue as well as skeletal conditions
- Post-operative management on scar care and maintenance of reconstructed nasal shape
- Presurgical nasoalveolar moulding (PNAM) is a non-surgical method of reshaping the alveolus, lips and nostrils before primary cleft lip and palate surgery.

PNAM addresses various problems associated with traditional methods of treating unilateral cleft lip and palate. It improves nasal asymmetry and deficient nasal tip.^[5-7] It also moulds the protruded premaxillary segment into a more normal alignment with the alveolar segments, improving the shape of the maxillary arch and also reducing the size of cleft lip, palate and the alveolus. It decreases the complexity of subsequent surgeries and also gives a more aesthetic outcome.^[8-10]

Presurgical orthopaedics has been employed since 1950 as the adjunctive procedure for correction of protruding premaxilla in the cleft. However, the original research on the neonatal moulding of the nasal cartilage was performed by Matsuo and Hirose.^[11] In 1993, Grayson *et al.* described a new technique of presurgical moulding of the alveolus, lip and nose in infants born with cleft lip and palate.^[12,13] At present, there are three different PNAM techniques routinely used, namely; Grayson's technique,^[13] Figueroa's technique^[14] and Liou's technique.^[15]

It has been shown that correction of nasal cartilage deformity and non-surgical elongation of a deficient columella can be achieved in combination with moulding of alveolar process with premaxillary retraction through

PNAM. This is possible because the cartilage has a high degree of plasticity in the neonatal period.^[16-17] The temporary plasticity of cartilage is due to high levels of hyaluronic acid, a component of proteoglycan intercellular matrix,^[12,18] which is found circulating in infants for several weeks after birth.^[19] Matsuo *et al.*,^[20] Matsuo and Hirose^[11] were the first to make use of this plasticity to lift nasal cartilage.

Although there have been a number of reports regarding the effectiveness of PNAM, there are hardly any prospective studies in the Indian cleft population regarding the results of PNAM and it is important to study the results of PNAM in these children with cleft lip and palate.

SUBJECTS AND METHODS

This is a prospective clinical study carried out during the period between December 2011 and August 2013 in our institute.

A total of 20 unilateral cleft lip and palate patients were part of this study.

All patients were with complete unilateral cleft lip and palate (CUCLP) between the age group of 2–44 days.

Inclusion criteria

- All un-operated cases
- No associated syndromes and systemic illness
- Moderately to well-nourished healthy babies.

Exclusion criteria

- Patients above 45 days of age
- Syndromic, malnourished and systemically ill babies
- Patient's/guardians who were unwilling to go through the PNAM therapy.

Following the first visit, the patients are evaluated by the surgeon and the orthodontist of the interdisciplinary cleft team. The technique followed is Liou's technique, wherein the alveolar and nasal mouldings are done at the same time. The PNAM device was composed of an acrylic dental plate and a nasal component. The nasal component was an extension of 20-gauge stainless steel wire along with a soft resin moulding bulb on the top [Figures 1 and 2]. The dental plate was held to the palate and dental arches with the help of denture adhesives. After insertion of the dental plate, the cleft lip was digitally approximated, and the 20-gauge wire was adjusted so that the cleft side

nasal cartilage was supported rather than pushed by the moulding bulb. The cleft lip was approximated by applying adhesive tapes. The tapes enabled narrowing the alveolar cleft, decreasing the width of nostrils and cinching the base of the nose.

Through biweekly modifications on the nasal moulding bulb and adjustments to the wire, the alar cartilage was carefully moulded to resemble the normal shape. The force from the adhesive taping and counterforce from the moulding bulb provide the force necessary for bringing the alveolus into proper position. Furthermore, with regular selective removal and addition of soft liner, the alveolus was moulded.

Parents or caregivers are instructed to keep the appliance in place at all times except for daily cleaning. The therapy was done for 5–5½ months until the time of the surgery.

All the patients underwent PNAM therapy under the same orthodontist.

Photographs (worms eye view) were taken at the start and the end of the PNAM therapy. These photographs were analysed for extraoral measurements through the Windows VistaDent software. DENTSPLY GAC INTERNATIONAL One CA Plaza, Suite 100 Islandia, NY 17149 800-645-5530 (in USA) 631-419-1700 631-357-8793 (fax) www.gacintl.com Casts of intraoral impressions at the start and the end of PNAM therapy were measured directly. The measurements were then tabulated, and a statistical analysis of the following was done of each patient.

RESULTS

Photographs of the 20 patients were taken before the start of PNAM and after the completion of the PNAM therapy. These photographs were subjected to analysis, for measurements, using VistaDent software, which calculated the measurements based on the pixels [Table 1 and Figures 3-22].

Intraoral models were prepared from the impression taken before the start of PNAM and after the completion of the PNAM therapy. Direct measurements were done on the models [Table 1 and Figures 23-25].

These parameter obtained were then subjected to statistical evaluation to study the effect of PNAM,

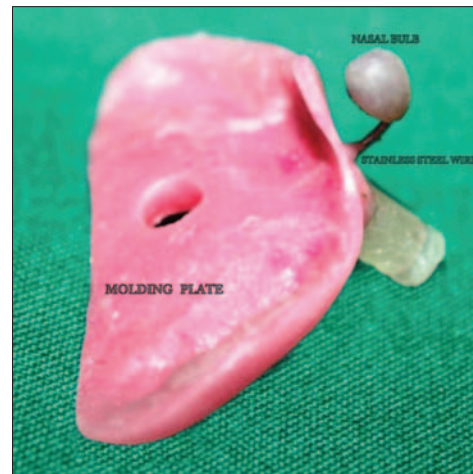


Figure 1: PNAM device- Frontal view

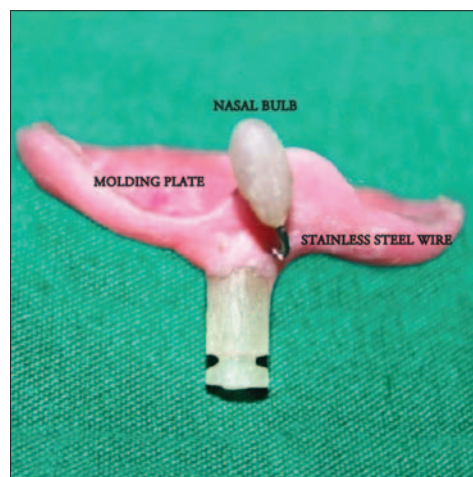


Figure 2: PNAM device- Lateral view view

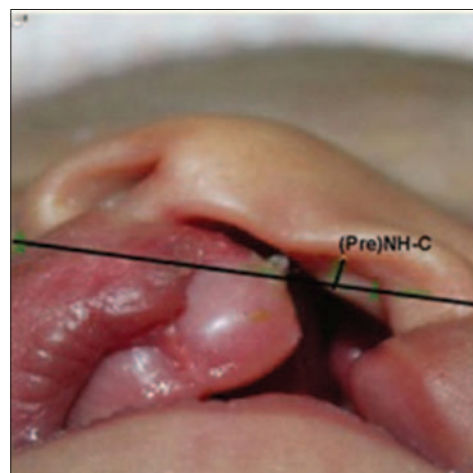


Figure 3: Nostril Height (Cleft Side) Pre PNAM

results on continuous measurements are presented as mean standard deviation (minimum-maximum). Significance has been assessed at 5% level of significance. Student's t-test has been used to find the

Table 1: Difference between cleft and noncleft side, comparison between pre- and post-surgical nasoalveolar moulding

<i>Measurements done on the photographs^(B)</i>	
<i>Cleft side</i>	<i>Noncleft side</i>
Nostril height (cleft side)	Nostril height (noncleft side)
Nostril width (cleft side)	Nostril width (noncleft side)
Nostril basal width (cleft side)	Nostril basal width (noncleft side)
Nasaldomeheight (cleft side)	Nasal dome height (noncleft side)
Columella length	Columella deviation

Measurements done on the casts

Inter-alveolar gap (A): the distance of point P and point P'.
 Length of the maxillary alveolar cleft (B): distance of point P and line TT' minus the distance of point P' and line TT'.

Palatal gap (C): distance of the widest points of the hard palate cleft

^PThe most anterior point of the non-cleft maxilla on the gingival ridge of the cleft, ^{P'}The most anterior point of the cleft maxilla on the gingival ridge of the cleft, ^Tmaxillary tuberosity of the greater segment, ^{T'}maxillary tuberosity of the lesser segment

significance of study parameters on the continuous scale within each group. Post operative results were stable at 6 m follow-up [Figures 26-29].

DISCUSSION

Millard^[21] described the unilateral and bilateral cleft deformity as a failure of mesenchyme to migrate from the maxillary process into the nasomedial processes. As a result of this failure, the maxilla and premaxilla do not form a bony union, and the muscle fibres from the maxillary processes do not enter the prolabium. This presents a discrepancy and a displacement of the components of nasomaxillary complex that persist without any appreciable improvement during growth.

In the case of a unilateral cleft, there is projection and outward rotation of the premaxilla along with retro-positioning of the anterior maxillary wall on the affected side. This causes flattening of the nasal tip and inferior displacement of the soft triangle.^[22] The nasal septum is twisted, slanted and dislocated out of the vomerine groove, resulting in a twist to the nasal tip.^[23] The columella is deflected by the deviation of the nasal septum and is vertically deficient on the cleft side. The deformed alar cartilage is dislodged from its normal anatomical position. The medial crus is lower in the columella, with the junction curve of the medial and lateral crus separated from the opposite alar cartilage. It rest below the opposite cartilage and is flattened, spread and stretched across the cleft at an obtuse angle.^[24,25]

Historically, there have also been numerous attempts at a non-surgical reduction in the size of the alveolar cleft. The start of the era of modern presurgical orthopaedic

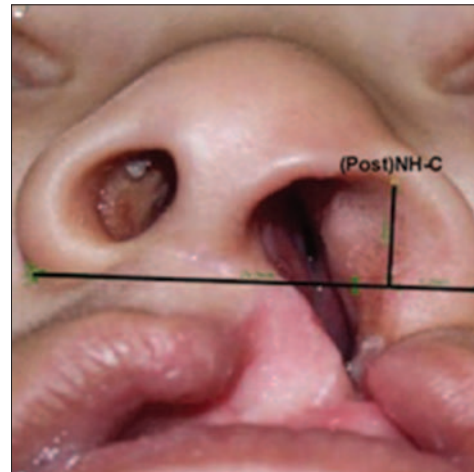


Figure 4: Nostril Height (Cleft Side) Post PNAM

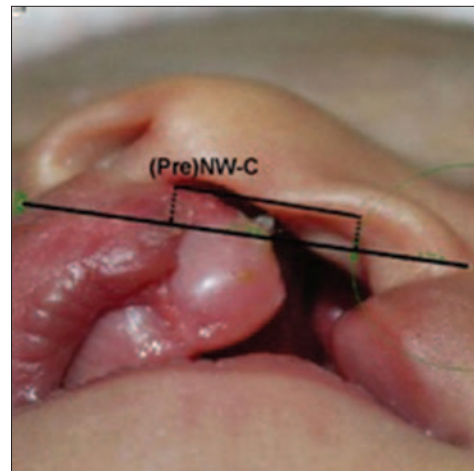


Figure 5: Nostril Width (Cleft Side) Pre PNAM

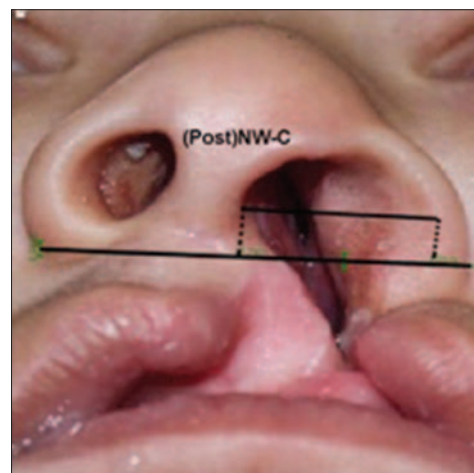


Figure 6: Nostril Width (Cleft Side) Post PNAM

appliances is usually attributed to Matsuo and Hirose.^[11] He utilised an intraoral acrylic appliance similar to an obturator to approximate the alveolar segments.

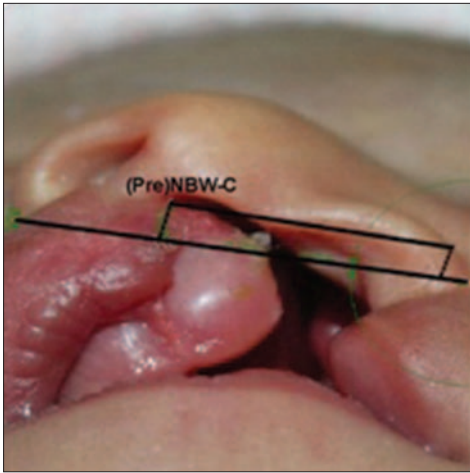


Figure 7: Nostril Basal Width (Cleft Side) Pre PNAM

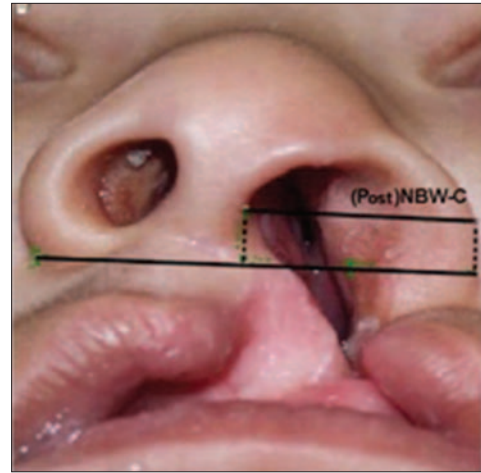


Figure 8: Nostril Basal Width (Cleft Side) Post PNAM

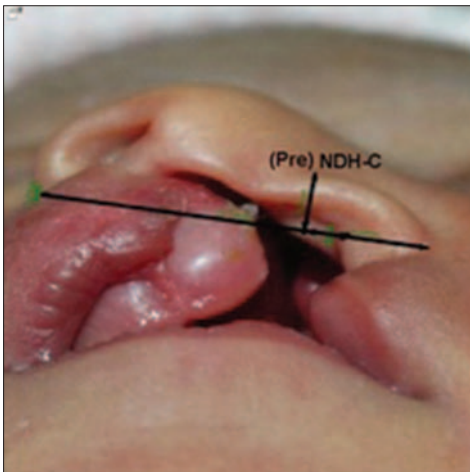


Figure 9: Nasal Dome Height (Cleft Side) Pre PNAM

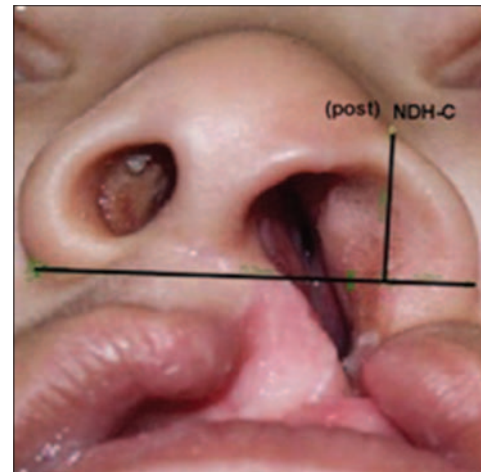


Figure 10: Nasal Dome Height (Cleft Side) Post PNAM

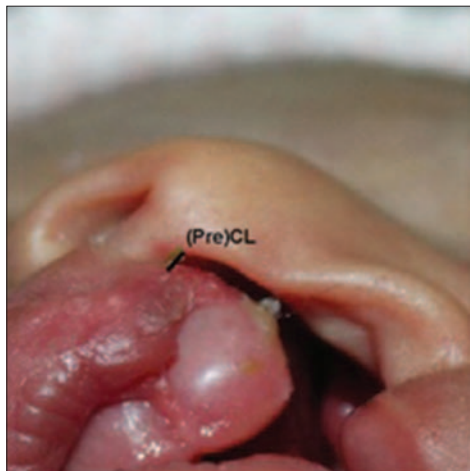


Figure 11: Columella length (Cleft Side) Pre PNAM

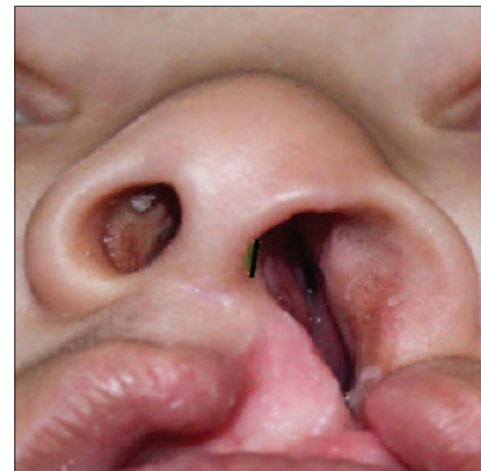

Figure 12: Columella length (Cleft Side) Post PNAM

Presurgical orthopaedic appliances have steadily evolved since then. Grayson *et al.* in 1993 first introduced the PNAM technique. Various modifications have also evolved

to this technique. Moreover, now, in this study we have used Eric Liou's technique, which is a modification of appliance described by Grayson *et al.*

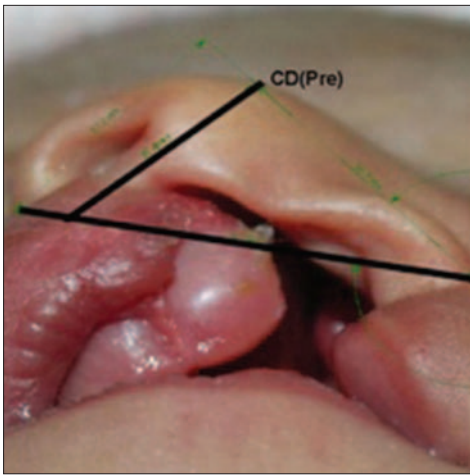


Figure 13: Columella Deviation (Cleft Side) Post PNAM

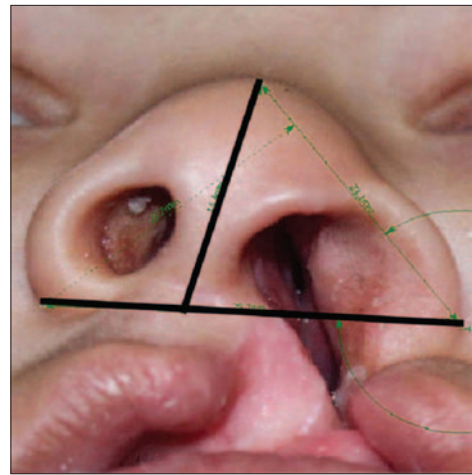


Figure 14: Columella Deviation (Cleft Side) Post PNAM

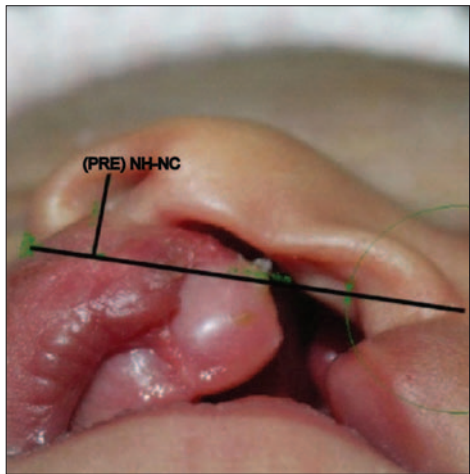


Figure 15: Nostril Height (Non Cleft Side) Pre PNAM

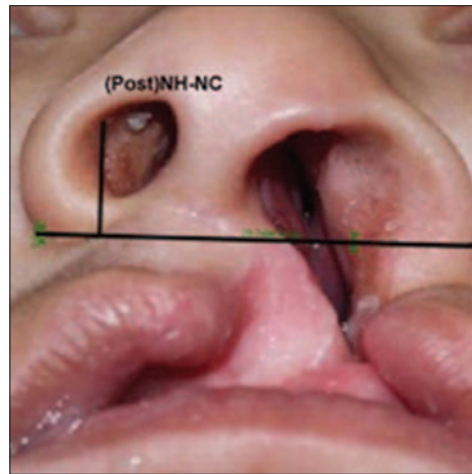


Figure 16: Nostril Height (Non Cleft Side) Post PNAM

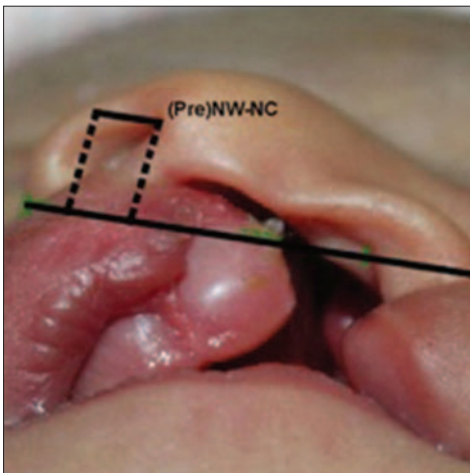


Figure 17: Nostril Width (Non Cleft Side) Pre PNAM

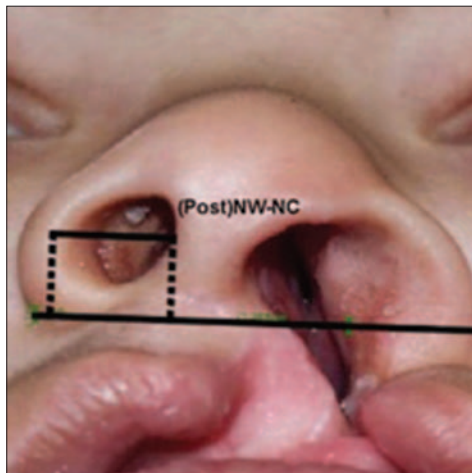


Figure 18: Nostril Width (Non Cleft Side) Post PNAM

The goal of PNAM is to align and approximate the alveolar cleft segments while at the same time achieving correction of the asymmetric nasal cartilage and soft

tissue deformity. These corrections are achieved by adding a nasal stent to the labial vestibular flange of a conventional intraoral moulding plate. The nasal stent

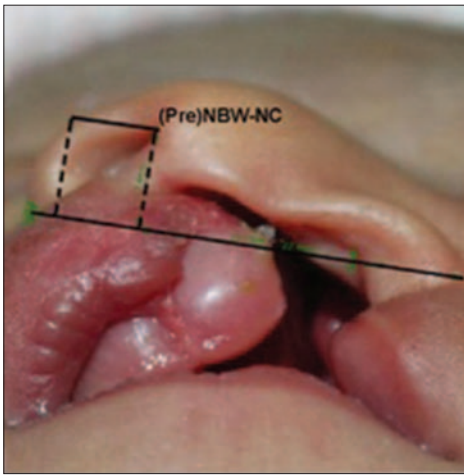


Figure 19: Nostril Basal Width (Non Cleft Side) Pre PNAM

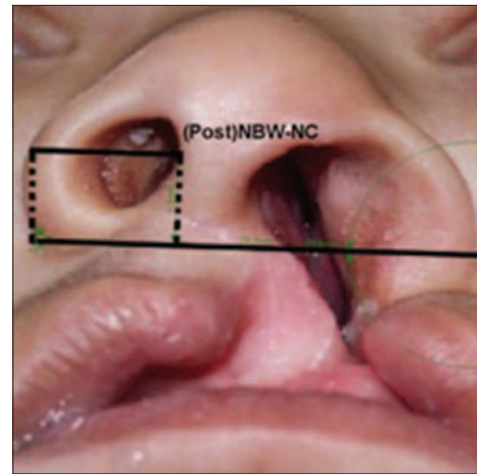


Figure 20: Nostril Basal Width (Non Cleft Side) Post PNAM

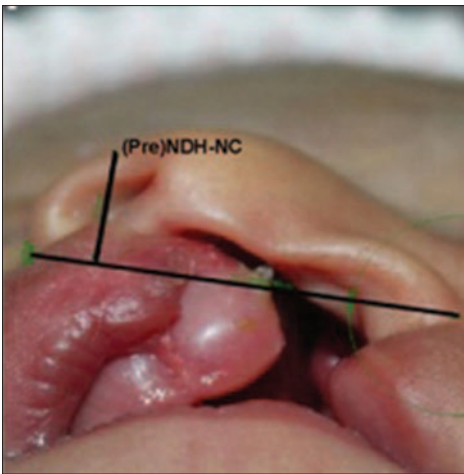


Figure 21: Nasal Dome Height (Non Cleft Side) Pre PNAM

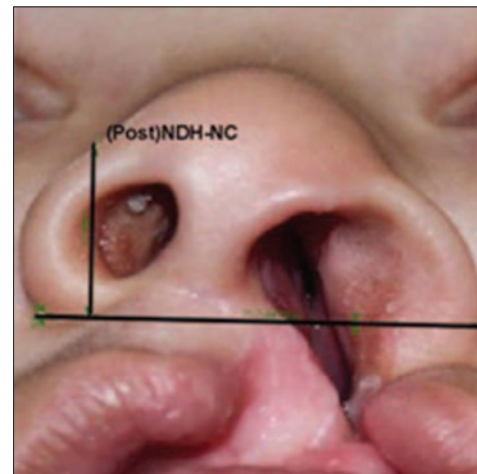


Figure 22: Nasal Dome Height (Non Cleft Side) Post PNAM

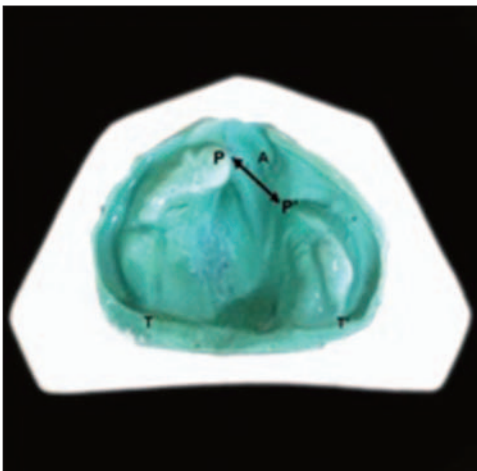


Figure 23: Inter-Alveolar Gap (A)

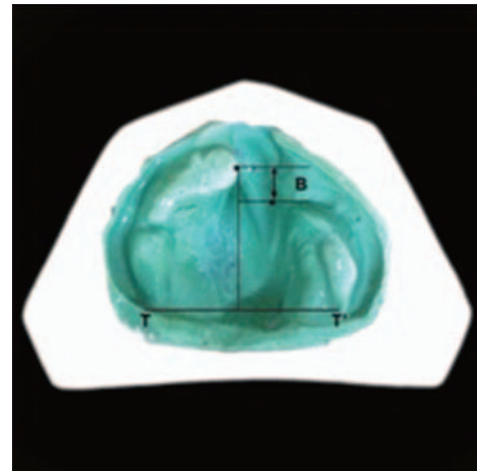


Figure 24: Length Of The Maxillary Alveolar Cleft (B)

and alveolar moulding plate are adjusted gradually over a period of 5–6 months to achieve nasal and alveolar symmetry, nasal tip projection, and approximation of

the cleft alveolar segments before primary lip, nasal, alveolar surgical repair. The nasoalveolar orthopaedic appliance is held in place with a combination of adhesive

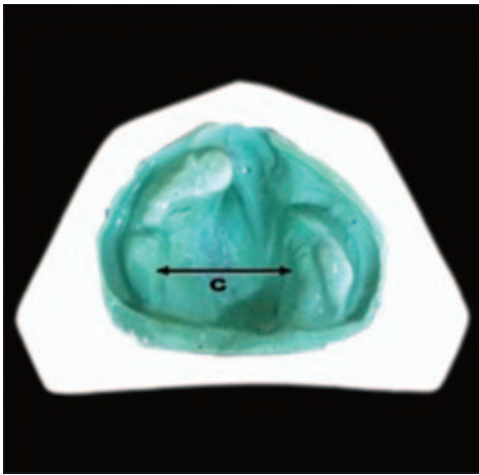


Figure 25: Palatal Gap (C)

tapes applied to the cheeks and cleft lip segments^[26]. The presurgical reduction in osseous and soft tissue cleft deformity considerably reduces the magnitude of the surgical challenge, resulting in improved surgical outcomes.^[19]

The advantages of presurgical infant orthopaedics may be considered from a soft tissue perspective as well as from the usual osseous perspective. The presurgical reduction in soft tissue and cartilaginous deformity facilitates achievement of surgical soft tissue repair under minimal tension and optimal conditions for scar formation. There is also a reduction in the number and complexity of minor soft tissue revision surgeries required to maintain acceptable nasolabial aesthetics as the nose grows.

We did this study to evaluate the outcome of PNAM in the treatment of CUCLP. The mean age at which PNAM begun was 23 days (range 2–44 days). The appliance was activated biweekly because of long distance traveling and socioeconomic status hindering the patients for regular weekly follow-ups in contrast to Liou's *et al.*, 2004 and Grayson *et al.*, 1999^[12,15] where the moulding was done on weekly basis. A total of 24 patients started the PNAM therapy, but 4 (17%) did not continue the treatment; the reasons were, lack of compliance, socioeconomic status hindering the parents to travel and get the therapy done on regular intervals, systemic illnesses and hospitalisation not allowing the patient to continue the treatment and hence, these were excluded from the study. Our patients were at the near end of the ideal cartilage moulding period, which is determined to be first 6 weeks of life.^[18] The therapy was done on an average for 120 days. Both alveolar and nasal moulding

were started at the same time irrespective of the alveolar ridges cleft distance, in contrast to Grayson *et al.*, who starts nasal moulding when the alveolar ridges were 6 mm apart.

We found that there was a significant decrease in the nostril basal width by a mean of 4.04 mm, there was a decrease in the nostril width by a mean of 4.16 mm, the columellar length increased by mean of 2.31 mm in size at the end of the therapy which was very minimal of about 0.45 mm pre-treatment, which was statistically significant. The nasal dome height increased by mean of 3.02 mm at the end of the therapy. The nostril height increased by a mean of 2.9 mm. There was a statistically significant improvement in all aspects of soft tissue nasal deformities in this study.

Another similar study was done by Liou *et al.* 2004,^[15] which showed that the nostril height increased to by a mean of 2.7 mm, whereas our study showed an increase of 2.9 mm. The nasal dome height increased in their study to 2.1 mm, and it was 3.02 mm in our study, a similar trend was also seen in columellar length which was 2.8 mm in their study as compared to our minimal increase in the length of 1.8 mm. In aspects of nostril basal width, their study showed a decrease of 1.5 mm whereas in our study it was 4.04 mm and in the case of nostril width, it was decreased to 3.4 mm in their study which was almost similar to 4.1 mm decrease in our study.

Another similar study was done by Pai *et al.*, 2005,^[26] showed that the columella deviation was increased from 53.3° to upright position of 69.9°, which is almost similar to our study which showed columella deviation moved to the midsagittal plane from 41.5° to a upright position of 61.20°.

We have compared the measurements of nostril height, nasal dome height, nostril basal width, nostril width between the cleft and the non-cleft sides, post-with pre-PNAM we found that the difference between the cleft and the non-cleft sides was much lower in the post-PNAM samples when compared to the pre-PNAM. To our knowledge, this aspect has not been reported in the literature.

Intraoral casts measurements showed that there was significant movement of the alveolar arches

by a mean of 12.3 mm pre-PNAM to 4.07 thereby reducing the alveolar gap, which was similar to study by Jaeger *et al.*,^[27] 2007 where the alveolar gap reduction was 14.8–2.7, which was almost similar. The palatal gap also was significantly reduced to a mean of 6.88, showing a significant decrease. Patel and Goyal (2012)^[28] reported cleft narrowing by 7 mm after 5 month's treatment while Pai *et al.*^[26] observed a reduction of 5.8 mm after 3–4 months of treatment. The results of the present study are in concordance with these studies [Figures 30 and 31].

On evaluation, it was shown quantitatively that, PNAM therapy significantly reduced the alveolar and palatal gap, and deviation of columella. These, in combination, helped to align the maxillary arches. Nasal symmetry was significantly improved. Columellar length significantly improved, hence increasing the nasal aesthetics. Nostril

height was significantly increased along with decreased in nostril width. All in combination improved the nasal tip projection.

CONCLUSIONS

PNAM has proved to be an effective adjunctive therapy for reducing hard and soft tissue cleft deformity before surgery. However, it is important that parents or caregivers become active members of the treatment plan. This study showed that PNAM therapy improved the nasal aesthetics, decreased the cleft size and aligned the maxillary arch with a reduction in cleft alveolus and palate size in UCLCP patients. Hence, this therapy should be advocated in all patients with UCLCP patients as a routine procedure in the treatment protocol, to improve the surgical results and enhance the aesthetics and function with minimal cost and surgeries [Figures 26-29].

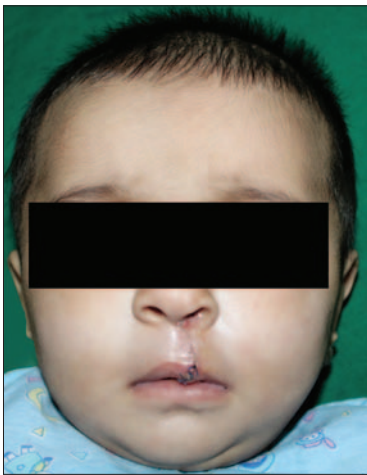

Figure 26: Immediate Post op - Frontal view

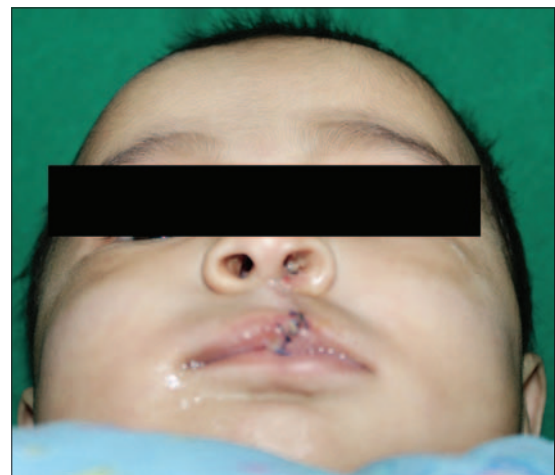

Figure 27: Immediate Post op - Worms eye view

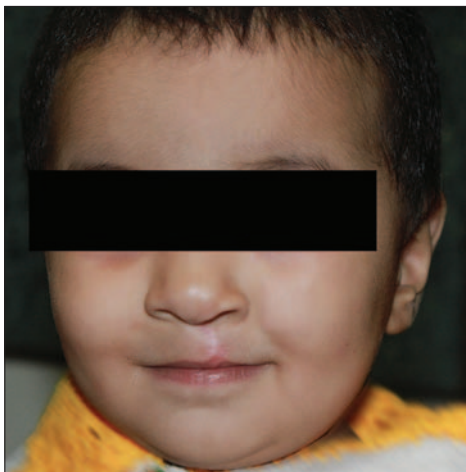

Figure 28: 6 Months Post op - Frontal View

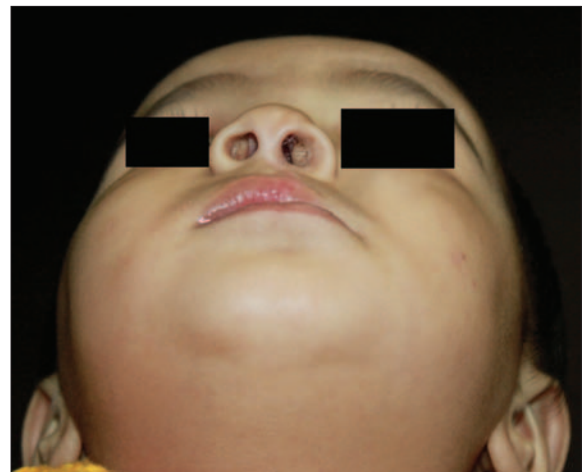

Figure 29: 6 Months Post op - Worms eye View

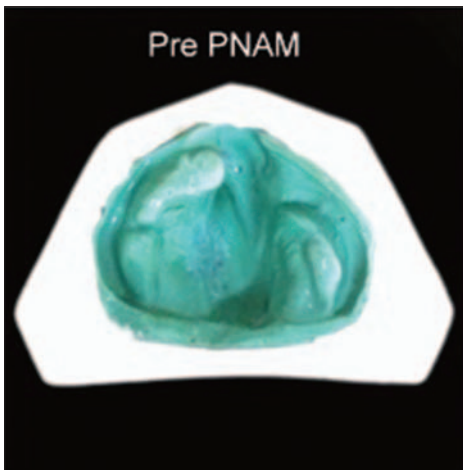


Figure 30: Pre PNAM Cast

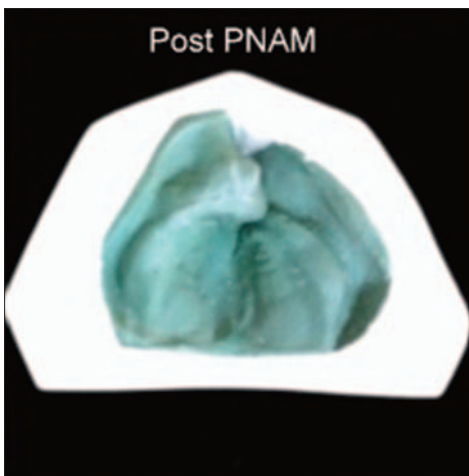


Figure 31: Post PNAM Cast

Declaration of patient consent

The authors certify that they have obtained all appropriate patient consent forms. In the form the patient(s) has/have given his/her/their consent for his/her/their images and other clinical information to be reported in the journal. The patients understand that their names and initials will not be published and due efforts will be made to conceal their identity, but anonymity cannot be guaranteed.

Financial support and sponsorship

Nil.

Conflicts of interest

There are no conflicts of interest.

REFERENCES

1. Grayson BH, Garfinkel JS. Early cleft management: The case for nasoalveolar molding. *Am J Orthod Dentofacial Orthop* 2014;145:134-42.
2. Yu Q, Gong X, Shen G. CAD presurgical nasoalveolar molding effects on the maxillary morphology in infants with UCLP. *Oral Surg Oral Med Oral Pathol Oral Radiol* 2013;116:418-26.
3. Maull DJ, Grayson BH, Cutting CB, Brecht LL, Bookstein FL, Khorrambadi D, *et al.* Long-term effects of nasoalveolar molding on three-dimensional nasal shape in unilateral clefts. *Cleft Palate Craniofac J* 1999;36:391-7.
4. Pfeifer TM, Grayson BH, Cutting CB. Nasoalveolar molding and gingivoperiosteoplasty versus alveolar bone graft: An outcome analysis of costs in the treatment of unilateral cleft alveolus. *Cleft Palate Craniofac J* 2002;39:26-9.
5. Ezzat CF, Chavarria C, Teichgraber JF, Chen JW, Stratmann RG, Gateno J, *et al.* Presurgical nasoalveolar molding therapy for the treatment of unilateral cleft lip and palate: A preliminary study. *Cleft Palate Craniofac J* 2007;44:8-12.
6. Singh GD, Levy-Bercowski D, Yáñez MA, Santiago PE. Three-dimensional facial morphology following surgical repair of unilateral cleft lip and palate in patients after nasoalveolar molding. *Orthod Craniofac Res* 2007;10:161-6.
7. Lee CT, Garfinkel JS, Warren SM, Brecht LE, Cutting CB, Grayson BH. Nasoalveolar molding improves appearance of children with bilateral cleft lip-cleft palate. *Plast Reconstr Surg* 2008;122:1131-7.
8. Ross RB, MacNamera MC. Effect of presurgical infant orthopedics on facial esthetics in complete bilateral cleft lip and palate. *Cleft Palate Craniofac J* 1994;31:68-73.
9. Kuijpers-Jagtman AM, Ross EL Jr. The influence of surgery and orthopedic treatment on maxillofacial growth and maxillary arch development in patients treated for orofacial clefts. *Cleft Palate Craniofac J* 2000;37:527-39.
10. Berkowitz S. *Cleft Lip and Palate*. 2nd ed. Berlin: Springer-Verlag; 2006.
11. Matsuo K, Hirose T. Preoperative non-surgical over-correction of cleft lip nasal deformity. *Br J Plast Surg* 1991;44:5-11.
12. Grayson BH, Santiago PE, Brecht LE, Cutting CB. Presurgical nasoalveolar molding in infants with cleft lip and palate. *Cleft Palate Craniofac J* 1999;36:486-98.
13. Grayson BH, Cutting C, Wood R. Preoperative columella lengthening in bilateral cleft lip and palate. *Plast Reconstr Surg* 1993;92:1422-3.
14. Figueroa AA, Polley JW. Orthodontics in cleft lip and palate management. In: Mathes S, Ventz V, editors. *Plastic Surgery*. 2nd ed. *Pediatric Plastic Surgery*. Vol. 4. Philadelphia: Elsevier; 2006. p. 271-310.
15. Liou EJ, Subramanian M, Chen PK, Huang CS. The progressive changes of nasal symmetry and growth after nasoalveolar molding: A three-year follow-up study. *Plast Reconstr Surg* 2004;114:858-64.
16. McNeil CK. Orthodontic procedures in the treatment of congenital cleft palate. *Dent Rec (London)* 1950;70:126-32.
17. Cho BC. Unilateral complete cleft lip and palate repair using lip adhesion combined with a passive intraoral alveolar molding appliance: Surgical results and the effect on the maxillary alveolar arch. *Plast Reconstr Surg* 2006;117:1510-29.
18. Matsuo K, Hirose T, Tomono T, Iwasawa M, Katohda S, Takahashi N, *et al.* Nonsurgical correction of congenital auricular deformities in the early neonate: A preliminary report. *Plast Reconstr Surg* 1984;73:38-51. AQ2
19. Grayson BH, Cutting CB. Presurgical nasoalveolar orthopedic molding in primary correction of the nose, lip, and alveolus of infants born with unilateral and bilateral clefts. *Cleft Palate Craniofac J* 2001;38:193-8.
20. Matsuo K, Hirose T, Otagiri T, Norose N. Repair of cleft lip with nonsurgical correction of nasal deformity in the early neonatal

- period. *Plast Reconstr Surg* 1989;83:25-31.
21. Millard DR Jr. Embryonic rationale for the primary correction of classical congenital clefts of the lip and palate. *Ann R Coll Surg Engl* 1994;76:150-60.
 22. Stenstrom SJ, Oberg TR. The nasal deformity in unilateral cleft lip. Some notes on its anatomic bases and secondary operative procedures. *Plast Reconstr Surg* 1961;28:295-305.
 23. Hogan VM, Converse JM. Secondary deformity of unilateral cleft lip and nose. In: Grabb WC, editor. *Cleft Lip and Palate – Surgical, Dental and Speech Aspects*. Boston: Little, Brown; 1971. p. 245-64.
 24. Huffman WC, Lierle DM. Studies on the pathologic anatomy of the unilateral harelip nose. *Plast Reconstr Surg* 1949;4:225-34.
 25. Millard DR. *Cleft Craft: The Evolution of Its Surgery. Bilateral and Rare Deformities*. Vol. 2. Boston: Little, Brown; 1977.
 26. Pai BC, Ko EW, Huang CS, Liou EJ. Symmetry of the nose after presurgical nasoalveolar molding in infants with unilateral cleft lip and palate: A preliminary study. *Cleft Palate Craniofac J* 2005;42:658-63.
 27. Jaeger M, Braga-Silva J, Gehlen D, Sato Y, Zuker R, Fisher D. Correction of the alveolar gap and nostril deformity by presurgical passive orthodontia in the unilateral cleft lip. *Ann Plast Surg* 2007;59:489-94.
 28. Patel D, Goyal R. Pre-surgical nasoalveolar moulding in patient with unilateral cleft of lip, alveolus and palate: Case report. *J Plast Reconstr Aesthet Surg* 2012;65:122-6.

New features on the journal's website

Optimized content for mobile and hand-held devices

HTML pages have been optimized of mobile and other hand-held devices (such as iPad, Kindle, iPod) for faster browsing speed.

Click on [**Mobile Full text**] from Table of Contents page.

This is simple HTML version for faster download on mobiles (if viewed on desktop, it will be automatically redirected to full HTML version)

E-Pub for hand-held devices

EPUB is an open e-book standard recommended by The International Digital Publishing Forum which is designed for reflowable content i.e. the text display can be optimized for a particular display device.


Click on [**EPub**] from Table of Contents page.

There are various e-Pub readers such as for Windows: Digital Editions, OS X: Calibre/Bookworm, iPhone/iPod Touch/iPad: Stanza, and Linux: Calibre/Bookworm.

E-Book for desktop

One can also see the entire issue as printed here in a 'flip book' version on desktops.

Links are available from Current Issue as well as Archives pages.

Click on  View as eBook