

Case Report

Successful microsurgical replantation of an amputated penis

Sanchit Garg, Shivprasad V. Date, Arunesh Gupta, Amresh S. Baliarsing

Department of Plastic Surgery, Topiwala National Medical College and BYL Nair Charitable Hospital, Mumbai, Maharashtra, India

Address for correspondence: Dr. Sanchit Garg, H. No. 753, Urban Estate Phase 2, Focal Point, Jamalpur - 141 010, Ludhiana, Punjab, India. E-mail: drsanchitgarg@gmail.com

ABSTRACT

Penile amputation is an uncommon injury for which immediate surgical replantation is warranted. Microsurgical replantation is the “standard” method for penile replantation. Early replantation yields a high success and low complication rate. We report a case of a 34-year-old male who presented with amputation at the proximal penile shaft which was successfully replanted using microsurgical techniques. Minor skin necrosis was noted post-operatively which was debrided and covered with skin graft. Follow-up at 6 months showed satisfactory cosmetic appearance, normal voiding, return of sensations and erectile function. The level of evidence was V.

KEY WORDS

Microsurgical replantation; penile amputation; pharmacostimulation

INTRODUCTION


Although total penile amputation is an uncommon injury, it requires the best method of repair for its unique urinary, sexual and psychological role in the life of a male. Penile amputation can be accidental, iatrogenic or self-inflicted (Klingsor syndrome). Psychiatric problems were found in about 87% of the reported patients.^[1] An epidemic of penile amputation was seen in 1970 in Thailand when wives started using this as punishment for infidelity.^[2] The first documented case of macroscopic penile replantation was described by Ehrich in 1929.^[3] Frequent complications in these cases included necrosis of the distal glans and skin, stricture,

fistula formation and erectile dysfunction.^[4] Cohen *et al.*^[5] and Tamai *et al.*,^[6] in 1977, reported successful microsurgical repair of the amputated penis in two independent case reports. Since then, several authors have successfully replanted male genitalia using microvascular techniques. Survival rates, skin loss and even return of erectile function were much improved.^[7] Today, microvascular penile replantation offers the best prospect for restoration of micturition function, return of sensations and erectile functions.^[8] Most of the reports have mentioned the presence of erectile function cursorily and have not provided any objective data which is an extremely important aspect to assess the outcome.

This is an open access article distributed under the terms of the Creative Commons Attribution-NonCommercial-ShareAlike 3.0 License, which allows others to remix, tweak, and build upon the work non-commercially, as long as the author is credited and the new creations are licensed under the identical terms.

For reprints contact: reprints@medknow.com

How to cite this article: Garg S, Date SV, Gupta A, Baliarsing AS. Successful microsurgical replantation of an amputated penis. Indian J Plast Surg 2016;49:99-105.

Access this article online	
Quick Response Code:	Website: www.ijps.org
	DOI: 10.4103/0970-0358.182257

This case highlights the management of such a patient alongwith a detailed description of relevant anatomy and physiology of erection and an objective assessment of erectile function.

CASE REPORT

We report a case of a 34-year-old male who had his penis amputated following an assault with a knife. He was taken immediately to a local hospital where the bleeding dorsal penile artery and vein were ligated. Amputate was kept in moist saline gauze and kept in a plastic bag which itself was kept in another plastic bag containing ice. Warm ischaemia time was 2 h. He was then referred to our institute. The total ischaemia time on presentation at our institute was 10 h. He was delirious due to the effect of alcohol that he had consumed and had also sustained blunt head trauma. While suprapubic cystostomy was being done in the emergency room and radiological investigations were being carried out to rule out any life-threatening internal head injury, the amputate was taken to operating room and assessed [Figures 1 and 2]. The flaccid length of the amputate was 5.5 cm. Anterior scrotal skin had come off along with the penis. Under the microscope two superficial dorsal veins, deep dorsal vein, right-sided dorsal penile artery and deep dorsal nerves were identified, ends freshened and tagged. Meanwhile after ruling out any life-threatening injury patient was taken to operation room where under general anaesthesia, the wound was thoroughly cleaned with saline and debrided minimally under microscope. The length of the penile stump was 1.5 cm from mons pubis. All the penile structures were found to be clean cut [Figure 3]. Dissection of superficial veins, deep dorsal vein, dorsal artery and nerves was done under operating microscope. Ligated parts of dorsal artery and vein were excised and its ends were clamped using microvascular clamp. Urethra along with the spongiosum was then repaired by spatulated end to end anastomosis using interrupted 4-0 polyglactin sutures over a 16F silicone Foley's catheter after appropriate mobilisation. The tunica albuginea of both corpora cavernosa and the septum were attached by interrupted 4-0 polyglactin sutures in watertight manner. The cavernosal arteries were identified but not anastomosed. The diameter of the dorsal artery was 1.2 mm and that of the vein was 1.5 mm. Vein graft was harvested from the dorsum of hand. Dorsal artery required 2.0 cm of vein graft and deep dorsal vein required 1.5 cm of the vein graft. Continuity of the artery followed by the deep dorsal vein was re-established using

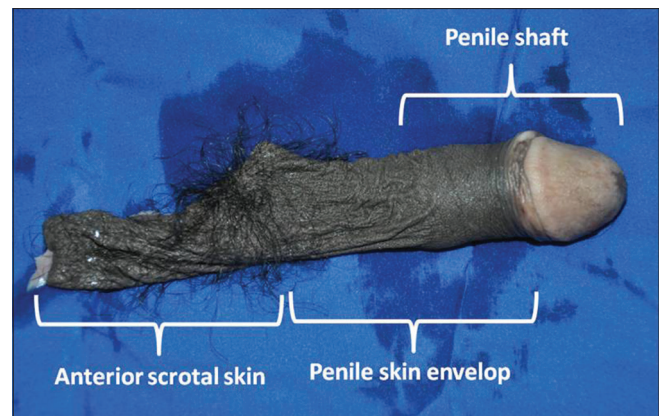


Figure 1: The amputate containing shaft with penile skin envelope and anterior scrotal skin. The length of penile skin appears more than the length of the shaft as the penis is in flaccid state and the prepucial skin has been retracted over the shaft

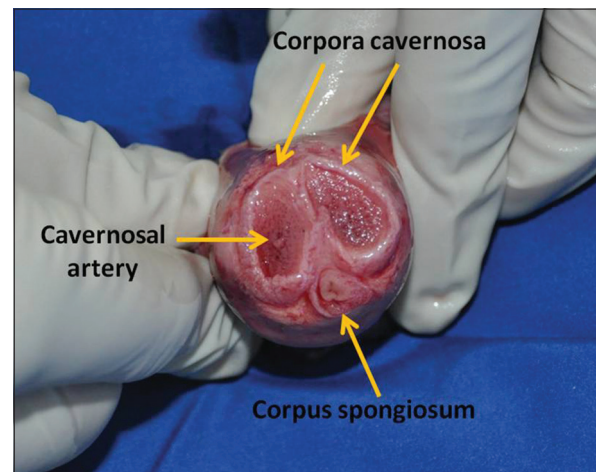


Figure 2: Cross-section of the penile stump showing corpora cavernosa, corpus spongiosum with urethra and cavernosal arteries in the centre of corpora cavernosa

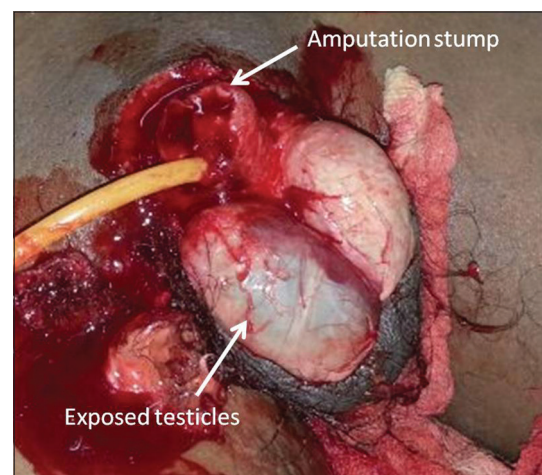


Figure 3: Amputation stump with exposed testes

interrupted 9-0 polyamide sutures [Figure 4]. Vascularity was re-established after 16 h following amputation. Following vascular anastomoses bright red bleeding from

penile skin and congested bleeding from the scrotal skin was seen. Vessels of diameter suitable for anastomosis could not be identified in scrotal skin. Glans showed normal capillary refill and pink colour. Deep dorsal nerves were coapted using 10-0 polyamide sutures. Buck's fascia was closed with 4-0 polyglactin sutures. Then one superficial vein was anastomosed with 10-0 polyamide sutures. Superficial nerves could not be identified. Finally, the skin was closed with 4-0 polypropylene sutures. Hoping that the vascularity of scrotal skin might improve in the post-operative period, it was preserved and closed primarily over corrugated rubber drain [Figure 5]. A bulky but non-constricting dressing was applied and the penis was fixed in an upright fashion.

A volume of 0.4 ml of injection enoxaparin was administered subcutaneously once daily and continuous intravenous injection of dextran 40 at the rate of 30 ml/kg/h was started intra-operatively and continued for 5 days. Two hourly post-operative monitoring of

temperature, colour and capillary refilling of glans; the colour of bleeding from the sutured edges of the skin of replanted penis; along with the monitoring of vascular patency with handheld Doppler was done. The scrotal skin and some skin over the dorsum of penis became necrotic in the post-operative period [Figure 6]. There was no haematoma or glans necrosis. On 10th post-operative day, debridement of scrotal skin with anterior transposition of posterior scrotal skin and primary closure was done. The necrotic penile skin was debrided and raw areas were skin grafted [Figure 7].

Patient started getting morning erections in 5th week [Figure 8]. At 5 weeks, transurethral catheter was removed. Retrograde urethrogram was done which showed free flow of the contrast into the bladder and no fistula in the urethra [Figure 9]. Clamping of suprapubic

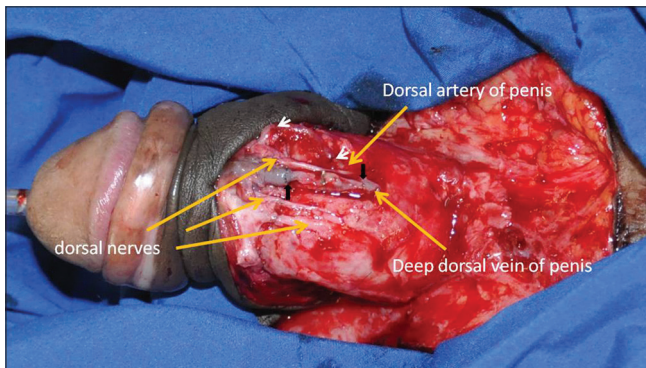


Figure 4: Repair of dorsal vessels and nerves. White arrows show vein graft anastomoses sites for arterial repair and black arrows show vein graft anastomoses sites for venous repair. There is only one dorsal penile artery on the right side. The deep dorsal nerve on the right side is lying medial to the artery

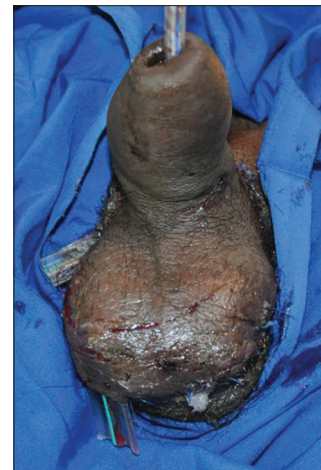

Figure 5: Replanted penis at the end of surgery. Scrotal skin has been closed over corrugated rubber drains

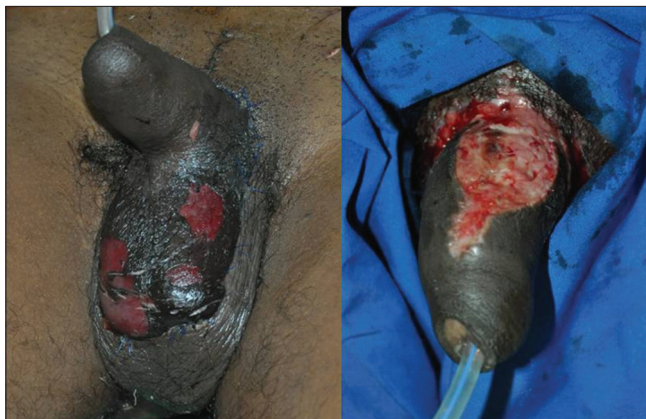

Figure 6: Anterior scrotal skin necrosis (left) and necrosis of a part of dorsal penile skin (right) at post-operative day 7

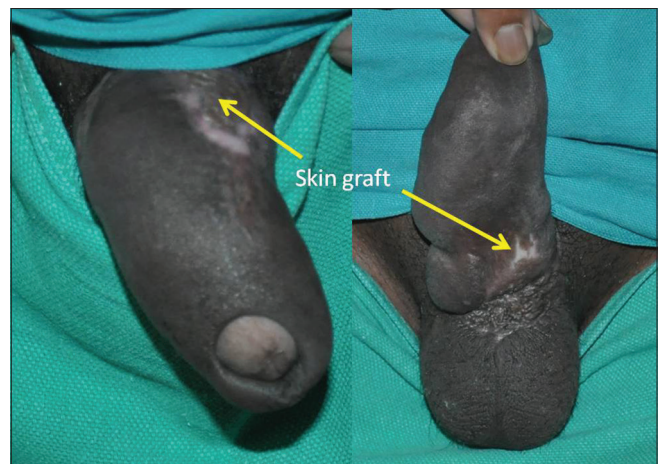

Figure 7: Post-operative pictures at 6 months show good aesthetic outcome. Skin grafted area over dorsum (left) and ventral base of penis (right) is shown. Slight oedematous appearance of penile skin can be appreciated



Figure 8: Replanted penis in erection

catheter was started and patient was allowed to pass urine per urethra. Suprapubic catheter was removed at 6 weeks after confirming normal uroflometric studies. The penile skin became little swollen. Gentle massaging of the penile skin was started which helped decreasing the oedema. Doppler studies at 6 weeks showed single dorsal penile artery with normal flow. Normal Doppler waveform changes were seen in both the cavernosal arteries suggesting the development of good collateral blood flow.

At 6 months, although penile skin is slightly oedematous, the penis has satisfactory aesthetic appearance. He is having frequent morning erections and is able to copulate, achieve orgasm and ejaculate. Length and girth parameters are given in Table 1. The turgid penile length is 12 cm and as per the patient it is almost similar to the pre-injury length. Urodynamic studies show normal urinary flow and retrograde urethrogram does not show any stricture. Erogenous and tactile sensations of the glans and prepuce skin have returned though decreased. Two-point discrimination of distal penile skin is 10 mm and that of glans is 7 mm. He can also localise touch and perceive deep pain stimuli on glans. Temperature and sharp pain sensations of glans are absent. Only crude touch sensations have recovered on penile shaft skin. Pharmacological stimulation tests to assess erectile function revealed parameters being comparable to normal individuals.

DISCUSSION

The macrosurgical replantation of penis was first described by Ehrlich.^[3] The survival of penis depends on corporal sinusoidal blood flow, with the distal

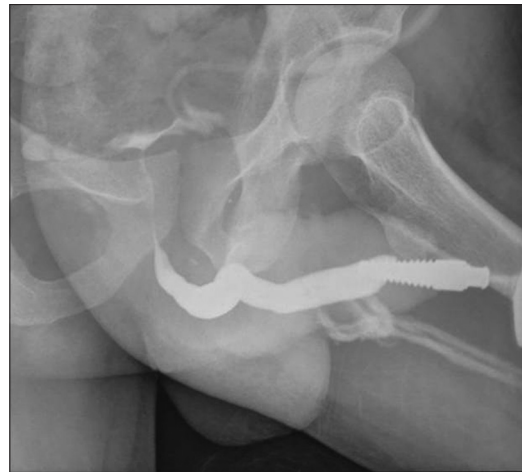

Figure 9: Retrograde urethrogram at 6 months showing no stricture in anterior urethra

Table 1: Length and girth parameters of penis

Parameters	Flaccid (cm)	Erect (cm)
Length	8	12
Girth	8	10

amputated part as a composite graft, leading to high complication rates of skin necrosis, fistula formation, loss of sensations and erectile dysfunction.^[4] Cohen *et al.*^[5] and Tamai *et al.*^[6] independently reported the first cases of microvascular replantation of penis in 1977. Microvascular replantation improved the survival rates, incidence of skin loss, urinary strictures and fistulas and even return of erectile function.^[7] Babaei and Safarinejad did comprehensive review of eighty cases of which thirty underwent microsurgical replantation. Twenty-seven of these thirty cases were of higher quality in terms of both functional as well as aesthetic outcome and hence they concluded microvascular repair to be the standard method for treatment of penile amputation.^[8]

Relevant anatomy and physiology of erection

The body of penis is formed by three longitudinal erectile connective tissue bodies - two corpora cavernosa and a corpus spongiosum. The corpora cavernosa comprise two spongy, paired cylinders contained in thick envelope of tunica albuginea. Each corpus is a conglomeration of sinusoids which are surrounded by smooth muscle trabeculae. These cavernous smooth muscles and the smooth muscles of arteriolar and arterial walls play the key role in erectile process.^[9]

The penis has dual arterial supply. The first is the pair of common penile arteries arising from the deep internal pudendal arteries. Each common penile artery

gives off three branches (bulbar, urethral, cavernosal), and terminates as the dorsal artery of the penis, which runs on either sides of deep dorsal vein distally within Buck's fascia to supply the glans and prepuce skin and its terminal branches also anastomose with the terminal branches of cavernosal artery in the glans penis. As it courses to the glans, it gives off cavernous branches and circumferential branches to the spongiosum and urethra [Figure 10].^[10] The cavernosal arteries run near the centre of corporal bodies and give branches to supply the cavernous sinuses and effects tumescence of corpus cavernosum during erection. Hence in penile replantation when only dorsal penile artery is anastomosed the glans and the prepuce skin survive through its terminal branches, corpus spongiosum and urethra through its circumferential branches and it also greatly augments cavernosal blood flow through its cavernous branches and terminal anastomoses with cavernosal arteries in the glans in lieu of sinusoidal blood flow. The porous septa between two cavernosa helps in augmenting blood flow of both the corporal bodies in cases where only one dorsal artery is anastomosed.^[9] The second blood supply of the penis is the superficial external pudendal system that supplies the dartos fascia and genital skin. Some authors have advocated the repair of two dorsal arteries and a cavernosal artery to maximise the inflow and facilitate erection of the replanted penis^[4,5] while others did not find this necessary.^[11] We repaired the single present dorsal penile artery. The artery was repaired before vein to limit the ischaemia time. The use of vein grafts to re-establish the vascular flow has not been reported earlier in penile replantation. It was required in our case since the vessels had been ligated after injury.

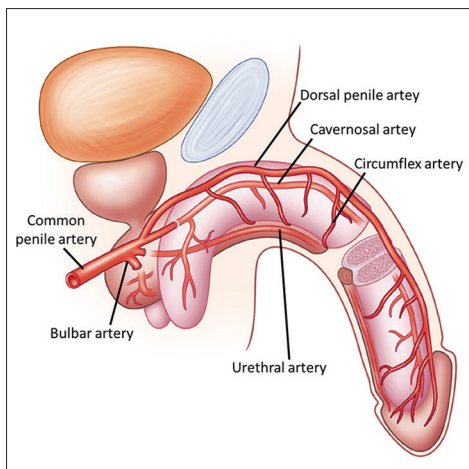


Figure 10: Arterial anatomy of penis

None of the clinical reports discussed any anatomical variations. However, in our patient, we found single dorsal artery on the right side and the right-sided dorsal nerve was found to be medial to the dorsal artery which is usually found lateral to the artery [Figure 11].^[10,12] Tansatit *et al.* found single dorsal artery in 10 of 32 cadavers, predominantly on the left.^[13] Bookstein and Lang did angiographic studies and found the incidence of unilateral hypoplasia of dorsal penile artery to be 13%.^[14]

Other critical factor for good outcome was adequacy of venous drainage. Beginning at the coronal sulcus, deep dorsal vein is the main venous drainage of glans and distal two-third of corpora cavernosa. Deep dorsal vein drains into santorini's plexus. In proximal one-third of penis, emissary veins join to form 2 to 5 cavernous veins. Penile shaft skin is drained by superficial veins into saphenous vein. Due to the dual venous drainage in the penis, the superficial and deep dorsal veins were both anastomosed for good venous return. The watertight closure of cavernosa and securing adequate haemostasis prevented formation of any haematoma. Necrosis of a part of skin of replanted penis and scrotal skin may be attributed to prolonged ischemia time (16 h) or may be because we could not identify and anastomose the external pudendal vessels. The amputated part can be maintained up to 16 h or may be up to 24 h at hypothermia.^[4] Little oedematous appearance of the penis may be attributed to lymphatic obstruction.

The penis has dual nerve supply - somatic and autonomic. The source of somatic nerve supply is again dual parallel to the arterial supply. The major sensory supply to the penis comes from the dorsal nerve of the penis which is the terminal branch of pudendal nerve. It innervates the distal shaft and inner lamina of the prepuce as well as pass directly into the glans as the major tactile and

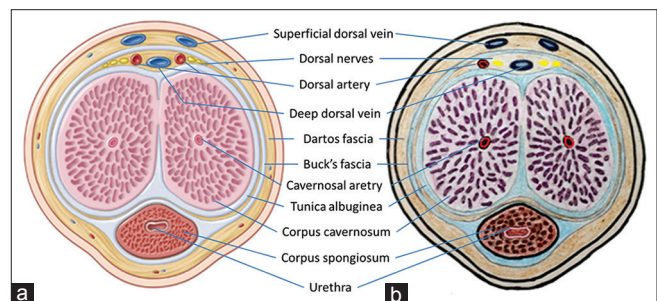


Figure 11: (a) A usual cross-section anatomy of penile shaft. [10] There are two dorsal penile arteries usually, one each on either sides of deep dorsal vein and the deep dorsal nerves lie lateral to the arteries. (b) In our case, only one dorsal penile artery was found on the right side. The deep dorsal nerve was lying medial to the artery

erogenous source of the penis. The shaft is innervated by ancillary erogenous nerves, including the ilioinguinal nerves and branches of the genitofemoral nerves that travel in dartos fascia. Inability to identify and coapt these superficial nerves is the reason of just minimal recovery of sensations of penile shaft skin in our case. Autonomic supply travels via cavernous nerves which travel alongside cavernosal arteries. They ramify in the erectile tissue to supply sympathetic and parasympathetic innervation from pelvic plexus. In the flaccid state, the smooth muscles are in tonic contraction due to tonic sympathetic output, allowing only small amount of arterial flow for nutritional purposes. Sexual stimulation results in stimulation of parasympathetic nerves and release of acetylcholine, nitric oxide and vasoactive intestinal peptide which effect relaxation of the smooth muscles and leads to following events: (1) Dilation of arterioles and arteries causing increased blood inflow in both systolic and diastolic phases; (2) trapping of incoming blood by expanding sinusoids; (3) compression of subtunical venous plexus and emissary veins reducing venous outflow. Sinusoids drain via intermediary veins into subtunical plexus immediately beneath the tunica albuginea. These plexus give rise to emissary veins which follow the oblique path between the layers of tunica and drain into circumflex veins which meet the deep dorsal vein of penis perpendicularly. Expanding sinusoids cause compression of emissary veins. All these factors raise intracavernosal pressure bringing penis into erect posture.^[9] The meticulous repair and careful orientation of the macroscopic structures, particularly the tunica around the corpora cavernosi is also of importance for the return of sexual function.^[11]

Erection returns in nearly all cases, making intercourse possible.^[4,15] Three different types of erections have been described.^[9] Reflexogenic erection is produced by tactile stimulation of genitalia. The impulses reach the spinal erection centres, and some activate the autonomic nervous system and effect erection through cavernous nerves while others follow the ascending tract resulting in sensory perception. This type of erection will be absent initially in a case of penile replantation. In our case, patient started getting reflexogenic erections at 3 months that is when the tactile sensations started reappearing.

Psychogenic erection occurs in response to audiovisual stimuli and fantasy. Nocturnal erection occurs during rapid eye movement sleep. Impulses from higher centres modulate the autonomic nervous system to cause

erection in these two types. These two types of erections are preserved in a case of penile replantation. The level of injury was (and usually is^[16]) distal to the entrance of the cavernous nerves and the cavernosal artery in the corpora. The nitric oxide and other smooth muscle relaxants produced in the proximal penile stump, where innervation is intact, is carried into the distal cavernosal bodies through re-established sinusoidal circulation achieved with watertight closure of tunica albuginea. The smooth muscle dilation along with blood inflow from cavernous and terminal branches of dorsal penile artery helps in the erection of replanted penis.^[11]

In our case, the erection was Grade 4 as per the erection hardness scale.^[17] Meuleman *et al.*^[18] performed pharmacological stimulation tests in normal subjects using intracavernosal injection of 12.5 mg of papaverine, along with duplex scan and studied four phases of erection. He showed that the peak flow velocity increases to almost double in the initial filling phase than the baseline value. The resistance index decreases in the initial filling phase, remains low in tumescence phase and in rigidity phase it becomes equal to or more than the value of resting phase. This depicts a positive erectile response. The arterial diameter increases in the tumescence phase. The values obtained in our patient after intracavernosal injection of 12.5 mg of papaverine are comparable to those found by Meuleman *et al.* in normal subjects [Table 2].

CONCLUSION

Microsurgical replantation is the 'gold standard' management for penile amputation. Prompt intervention, knowledge of the surgical anatomy and its variations, meticulous surgical technique, use of vein grafts wherever required, and optimal post-operative monitoring and care are essential for a successful outcome. A thorough documentation of all the critical factors and objective assessment of functional results is indispensable for detailed evaluation of subsequent reports of this rare entity.

Table 2: Pharmacological stimulation test parameters

Parameters	Baseline	Expected response after pharmacostimulation	Patient value
Peak flow velocity	45.8 cm/s	Increase	97.2 cm/s (initial filling phase)
Arterial diameter	0.8 mm	Dilatation	1.3 mm (tumescence phase)
Resistance index	0.90	0.9-1.0	0.90 (rigidity phase)

Financial support and sponsorship

Nil.

Conflicts of interest

There are no conflicts of interest.

REFERENCES

1. Evins SC, Whittle T, Rous SN. Self-emasculation: Review of the literature, report of a case and outline of the objectives of management. *J Urol* 1977;118:775-6.
2. Bhanganada K, Chayavatana T, Pongnumkul C, Tonmukayakul A, Sakolsatayadorn P, Komaratat K, *et al.* Surgical management of an epidemic of penile amputations in Siam. *Am J Surg* 1983;146:376-82.
3. Ehrich WS. Two unusual penile injuries. *J Urol* 1929;21:239.
4. Jordan GH, Gilbert DA. Management of amputation injuries of the male genitalia. *Urol Clin North Am* 1989;16:359-67.
5. Cohen BE, May JW Jr., Daly JS, Young HH. Successful clinical replantation of an amputated penis by microneurovascular repair. Case report. *Plast Reconstr Surg* 1977;59:276-80.
6. Tamai S, Nakamura Y, Motomiya Y. Microsurgical replantation of a completely amputated penis and scrotum: Case report. *Plast Reconstr Surg* 1977;60:287-91.
7. Wei FC, McKee NH, Huerta FJ, Robinette MA. Microsurgical replantation of a completely amputated penis. *Ann Plast Surg* 1983;10:317-21.
8. Babaei AR, Safarinejad MR. Penile replantation, science or myth? A systematic review. *Urol J* 2007;4:62-5.
9. Lue TF. Physiology of penile erection and pathophysiology of erectile dysfunction. In: Wein AJ, Kavoussi LR, Novick AC, Partin AW, Peters CA, editors. *Campbell-Walsh Urology*. 10th ed., Vol. 1. Philadelphia: Elsevier Saunders; 2012. p. 688-719.
10. Quartey JK. Microcirculation of penile and scrotal skin. *Atlas Urol Clin North Am* 1997;5:1-9.
11. Lidman D, Danielsson P, Abdiu A, Fähræus B. The functional result two years after a microsurgical penile replantation. Case report. *Scand J Plast Reconstr Surg Hand Surg* 1999;33:325-8.
12. Quartey JK. Anatomy and blood supply of the urethra and penis. In: Schreiter F, Jordan GH, editors. *Reconstructive Urethral Surgery*. Germany: Springer Medizin Verlag Heidelberg; 2006. p. 11-7.
13. Tansatit T, Jindarak S, Sampatanukul P, Wannaprasert T. Neurovascular anatomy of the penis and pelvis in Thai males: Applications to male-to-female and pelvic surgeries. *J Med Assoc Thai* 2007;90:121-8.
14. Bookstein JJ, Lang EV. Penile magnification phalloplasty: Details of intrapenile arterial anatomy. *AJR Am J Roentgenol* 1987;148:883-8.
15. Kochakarn W, Muangman V, Krauwit A. Traumatic penile amputation: Results with primary reattachment. *J Urol* 1997;157:857.
16. Carroll PR, Lue TF, Schmidt RA, Trengrove-Jones G, McAninch JW. Penile replantation: Current concepts. *J Urol* 1985;133:281-5.
17. Goldstein I, Lue TF, Padma-Nathan H, Rosen RC, Steers WD, Wicker PA. Oral sildenafil in the treatment of erectile dysfunction. Sildenafil Study Group. *N Engl J Med* 1998;338:1397-404.
18. Meuleman EJ, Bemelmans BL, van Asten WN, Doesburg WH, Skotnicki SH, Debruyne FM. Assessment of penile blood flow by duplex ultrasonography in 44 men with normal erectile potency in different phases of erection. *J Urol* 1992;147:51-6.