

Ideas and Innovations

Precise breast implant placement using percutaneous chest wall markings

Janna Joethy, Bien-Keem Tan

Department of Plastic, Reconstructive and Aesthetic Surgery, Singapore General Hospital, Singapore

Address for correspondence: Prof. Bien-Keem Tan, Singapore General Hospital, Singapore. E-mail: bienkeem@gmail.com

ABSTRACT

Background: Traditionally, pre-operative breast markings are usually made using an indelible marker. These markings are at risk of being removed by pre-operative cleaning, positional changes and parenchymal changes post-incision. We present our approach to breast surgery with rib or intercostal markings using methylene blue. **Methods:** Using an indelible marker, markings are made on the breast and the inframammary crease. A blue needle (23 G) mounted on a 1 ml syringe is prepared, and aliquots of 0.1 ml of methylene blue are injected. Excessive infiltration and pre-operative local anaesthetic infiltration result in diffusion of the dye and difficulty with accuracy. Dye is injected directly over the bony periosteum closest to the inframammary fold. **Results:** We achieved good symmetry of bilateral breast implants. Photographs were taken pre-operative and 3 months post-operative and were evaluated independently by medical officers. All results were rated as good or very good. We had 39 patients and follow-up was between 3 and 24 months. There were no implant-related complications. **Conclusions:** For accurate implant placement, a fixed position must be found. Our technique utilises the relative immobility of the ribs for accurate implant placement. Disadvantages to our method were few, and we had two cases of dizziness or patients feeling faint due to pain. There is also a potential allergic or anaphylaxis reaction, but we did not experience any allergic reaction.

KEY WORDS

Breast augmentation, breast implant, chest wall markings

INTRODUCTION

Staged breast reconstruction with implants involves mastectomy, tissue expander (TE) and implant exchange. Mastectomy usually results in extensive pocket dissection and wide clearance. Thus, tissue expansion in such a cavity can lead to asymmetric expansion and

expander migration. Furthermore, wide pocket dissection also makes accurate implant placement difficult.

We propose a two-stage approach with initial tissue expansion and delayed implant exchange. This approach

This is an open access article distributed under the terms of the Creative Commons Attribution-NonCommercial-ShareAlike 3.0 License, which allows others to remix, tweak, and build upon the work non-commercially, as long as the author is credited and the new creations are licensed under the identical terms.

For reprints contact: reprints@medknow.com

How to cite this article: Joethy J, Tan BK. Precise breast implant placement using percutaneous chest wall markings. *Indian J Plast Surg* 2016;49:234-8.

Access this article online	
Quick Response Code:	Website: www.ijps.org
	DOI: 10.4103/0970-0358.191294

allows for subtle (but crucial) corrections and critical in this are the use of internal and fixed markings. Traditional skin markings are not reliable as they are liable to change with position as well as after initial skin incisions are made on the breast. Residual breast tissue undergoes significant mobilisation which hampers accurate implant placement. Furthermore, tissue expansion leads to preferential upper pole expansion. Implants placed in these pockets tend to migrate superiorly.

Pre-operative markings in breast surgery are common practice. Traditionally, the pre-operative markings are usually made using an indelible marker with the patient standing. These markings are at risk of being removed if the chest wall and breast are cleaned and scrubbed. However, once the patient is lying down and with the effect of gravity now negated, the position of these markings moves up by 2 cm as observed empirically. Furthermore, once the incision is made and undermining is done, the position of these markings typically moves up a further 2 cm.

We present our approach to breast surgery with rib or intercostal markings using methylene blue injections. Using our method of marking, we can achieve more accurate implant placement at a pre-determined, fixed level. We highlight our cases and show the advantages of using this method. Figure 1 illustrates the position of the implant position relative to the internal methylene blue markings that we follow and relative to the nipple-areolar complex.

We initially used our percutaneous markings for breast reconstruction but have subsequently used it for breast augmentation (BA).

METHODS

Percutaneous markings are used for a variety of breast operations from reconstruction to augmentation. When expanders are used, they are typically placed in a submuscular pocket. We find that this placement can result in a more superolateral expander position due to the pectoralis major muscle contraction which we address during our implant placement. Implants are chosen based on pre-operative measurements of chest width and the patient's desired projection.

The inframammary crease is marked with the patient upright and taking implant dimensions into account.

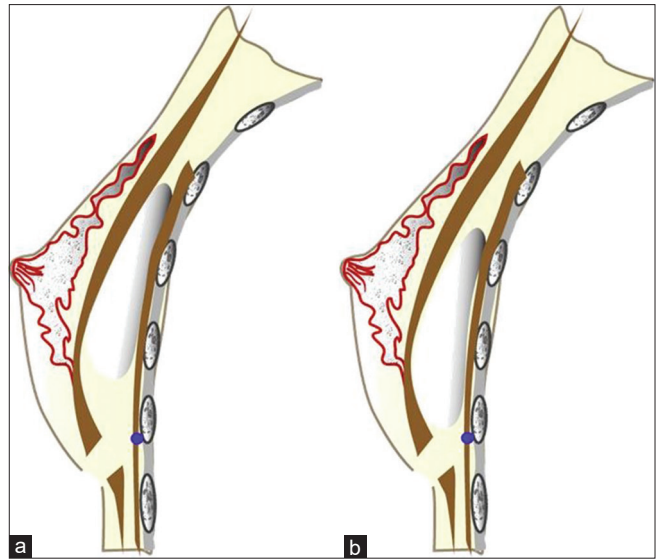


Figure 1: (a) Implant centred over nipple and (b) implant placed over methylene blue dye (internal markings). These illustrations of breast augmentation show that the latter placement is more precise and avoids a high riding implant, gave less superior pole projection and achieves better symmetry.

A blue needle (23-gauge) needle mounted on a 1 ml syringe is prepared and aliquots of 0.1 ml of blue dye are injected. This amount allows localised point staining of dye intraoperatively. Excessive infiltration and pre-operative local anaesthetic infiltration result in diffusion of the dye and difficulty with accuracy. As local anaesthesia is not infiltrated, we use topical anaesthesia and proceed with a chair or bed behind the patient in case of pain.

Dye is injected directly over the bony periosteum closest to the inframammary fold. If the bone is noted to lie above or below this fold, we mark the rib and slowly "run" the needle down to the muscle. The needle is not advanced past the rib to avoid injury to underlying structures. Dye injection is done while withdrawing the needle.

Therefore, we aim to stain the periosteum and we aspirate to ensure we are not in a vessel lumen before injecting on withdrawing the needle. This leaves a track of blue dye commencing at the bone or muscle and terminating at the skin surface. This allows for a method of marking that will stay the same with the patient lying down or standing. Both medial and inferior margins are marked.

Dissection proceeds until the expander is visualised and removed. Capsulotomy is performed more medially and inferiorly with a diathermy. Blue dye is then noted in the medial and inferior margins and forms our boundary for implant placement.

An anatomical implant (usually between 295 and 325 ml) (Silimed) is used. If a larger volume is required, this usually indicates a significant amount of ptosis that an implant cannot mimic and we prefer autologous reconstruction.

Pledged pull out sutures are used over the superolateral aspect of the pectoralis major muscle to temporarily prevent superomedial retraction of the pectoralis major. These sutures are left for at least 2 weeks. The pectoralis major muscle is repaired with vicryl 2-0 to prevent grooving and the skin is repaired in 2 layers.

RESULTS

We have used our percutaneous methylene blue injection method on the following patients [Table 1]:

1. Breast reconstruction with TE and implant
2. Tissue expansion
3. Simple BA
4. BA in unequal breasts
5. Breast reconstruction and secondary contralateral augmentation.

Post-operatively, we achieved good symmetry of bilateral breast implants. Photographs were taken pre-operative and 3 months post-operative and were evaluated independently by medical officers. Results were rated as either very good, good, minor problems, or major problems.

We had 39 patients and follow-up was between 3 and 24 months. All results were rated as good or very good. There were no implant-related complications.

DISCUSSION

In the United States, there has been a shift away from autologous tissue to implant reconstruction, and as of 2002, implants were the most popular method of breast reconstruction in the United States.^[1] In our setting, we

use breast implants for delayed breast reconstruction and where implant reconstruction is chosen by the patient. Seventy per cent of our cases involve ductal carcinoma *in situ* or early cancer that does not require radiotherapy or are sentinel lymph node negative. These patients undergo mastectomy and TE. Eventually, the expanders are exchanged for implants.

With extensive pocket dissection, implants have a tendency to ride higher. Conversely, if the implants are placed too low, there is a tendency for remnants of the nipple-areolar complex to migrate upwards. Accurate implant placement is therefore essential.

Traditional skin markings with indelible markings change position from the upright to supine position. The positional change in marking causes difficulty in implant placement. Regardless of marking technique, the position of the skin will change depending on position due to the effect of gravity and stress-relaxation of the skin.

For BA, relying on the nipple-areolar position is also fraught with difficulty as the nipple is also mobile. Nipple mobility is related to breast laxity so that if the patient has lax breasts, then the nipple is more mobile and less reliable as a marker.

Furthermore, to counter movement of the skin and to a lesser extent nipple-areolar position, it is best to sit the patient up. However, where operating tables do not allow for 90° flexion, this is not a viable option. Furthermore, sitting is not a valid simulation of standing as the abdomen can push the breasts up in the sitting position.

For accurate implant placement, a fixed position must be found. To that effect, the rib underlying the breast is relatively fixed to the overlying breast parenchyma. Our technique utilises the relative immobility of the ribs for accurate implant placement.

Our percutaneous markings are useful in many settings:

Tissue expander and implant exchange

Following breast resection, there is usually a large space to be filled by the TE. Movement or shifting of the expander occurs over time. During the final implant exchange, we need to remark the margin. We typically percutaneously mark the medial and inferior margin to aid in implant

Table 1: Indications for the use of methylene blue

Operation	Number
Breast reconstruction with tissue expander and implant	21
Tissue expansion	5
Simple breast augmentation	5
Breast augmentation in unequal breasts	3
Breast reconstruction with latissimus dorsi and tissue expander and implant	3
Breast reconstruction and secondary contralateral augmentation	2
Total	39

placement. Skin markings will not do justice as the markings will change depending on position and if skin is incised. The methylene blue injections allow for a fixed landmark from which minor placement adjustments can be made. In Figure 2, note the difference in inframammary fold that was corrected with the aid of the methylene blue dye.

Breast augmentation

The methylene blue injections are typically useful for asymmetrical patients or patients with obvious differences in inframammary folds. We prefer the inframammary approach, and the problem arises from difficulty in centring the implant. This difficulty arises partly as a result of the skin markings moving when the patient position changes from standing to supine. The methylene blue injections also come in useful if the operating bed cannot be raised to 90° (to sit the patient up). Furthermore, the sitting position is at best a mediocre substitute for standing as abdominal tissue can affect breast position in the seated position. Traditionally, the implant is centred over the nipple, but the nipple is also mobile. Nipple mobility depends on breast laxity and hence, like skin markings, can vary and is position dependent.

We utilise the fact that the rib is relatively fixed and place our markings on the rib. If our markings suggest that we need to be in the muscle, we aim to mark the rib and slowly “run” the marking down to the muscle. This way, we do not go deep and cause injury to the underlying structures.

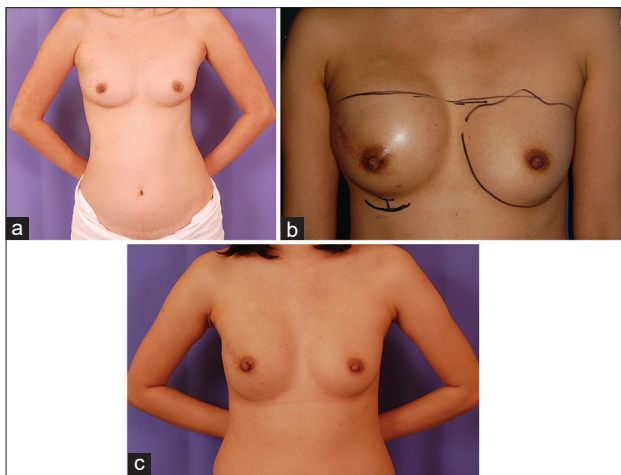


Figure 2: Pre-operative photograph of a 37-year-old lady with right sided ductal carcinoma *in situ*. (b) Post-tissue expander. Note the difference in inframammary fold. (c) Post-implant exchange. Note the inframammary fold has been lowered and the breasts are more symmetrical

In Figure 3, the patient has marked scoliosis and asymmetrical breasts. The methylene blue dye is helpful to provide a fixed landmark for implant placement.

Breast reconstruction with implants

These are cases where implant exchange is performed with or without latissimus dorsi cover. In these cases, we use methylene blue dye at the time of implant exchange. The TEs are removed and the patients are marked with methylene blue dye at the inferomedial aspect. The inferomedial markings are made to preserve the inframammary fold and prevent synmastia or injury to the internal mammary perforators. Skin markings will not do justice as the markings will change dependent on position and if skin is cut. In Figure 4, we see a complex case of bilateral breast reconstruction using implants. This patient had multiple surgeries with resultant asymmetry that we improved with the aid of methylene blue injections.

Disadvantages to our method were few, and we had two cases of dizziness or patients feeling faint due to pain. There were no other complications. There is also a potential allergic or anaphylaxis reaction, but we did not experience any allergic reaction.

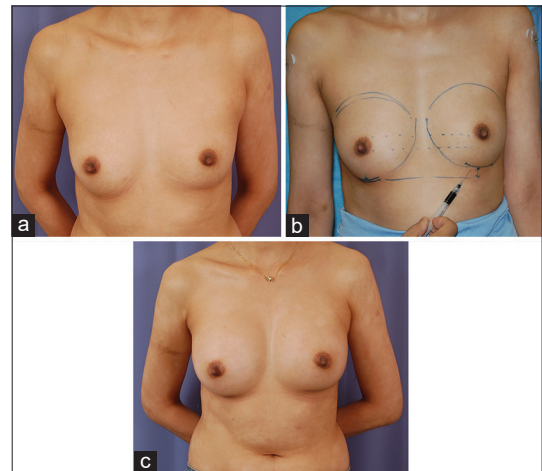


Figure 3: (a) This case illustrates breast augmentation in asymmetrical breasts in a 32-year-old woman with marked scoliosis and naturally asymmetric breasts. The left breast is higher and smaller than the right breast. (b) Pre-operative markings. The difference in the inframammary folds is seen. The injection of methylene blue dye is useful in such patients as it allows for fine tuning in a patient with asymmetric breasts. The plan was to lower the inframammary fold by 1.5 cm. (c) Right side was 255 cc, natural profile implant, left side 285 cc. In breast augmentation, the effect of the implant accentuates any natural asymmetries. Although the inframammary fold does not look level, this was an expected outcome based on the shoulder height discrepancy

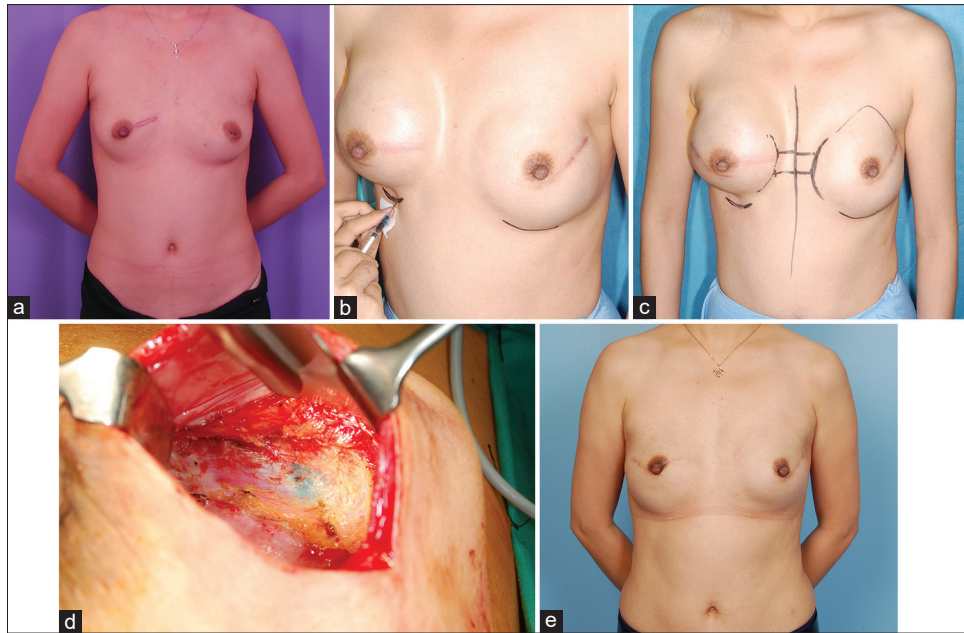


Figure 4: (a) A 40-year-old female with a previous right lumpectomy. She was subsequently found to have left ductal carcinoma *in situ* and underwent mastectomy, tissue expansion and 285 cc implant exchange. (b) Her right breast developed ductal carcinoma *in situ* and she underwent mastectomy and tissue expansion. She is shown here prior to implant exchange. The pre-operative markings show that the right inframammary fold needs to be lowered. The intended new inframammary fold is marked with both an indelible marker and by percutaneous injection with methylene blue. (c) With the 400 cc expander, there appears to be preferential superior pole expansion. (d) Intraoperative visualisation of methylene blue dye. (e) Six months post-operative photograph. In addition to the surgeries already mentioned, the patient underwent three sessions of fat grafting. Note the restoration of symmetry and inframammary folds. The right side is slightly lower, but we expect this to become less apparent with time.

Financial support and sponsorship

Nil.

Conflicts of interest

There are no conflicts of interest.

REFERENCE

1. Cemal Y, Albornoz CR, Disa JJ, McCarthy CM, Mehrara BJ, PusicAL, *et al*. A paradigm shift in U.S. breast reconstruction: Part 2. The influence of changing mastectomy patterns on reconstructive rate and method. *Plast Reconstr Surg* 2013;131:320e-6e.