

## Case Report

# Replantation in scapulothoracic avulsion amputation of the right upper limb in a 3-year-old child- A preliminary report

**Sanjay Mahendru, Rakesh Kumar Khazanchi, Vimalendu Brajesh, Akram Jawed<sup>1</sup>, Aditya Aggarwal, Hardeep Singh, Sukhdeep Singh, S. Krishnan**

Department of Plastic, Reconstructive and Aesthetic Surgery, Medanta - The Medicity, <sup>1</sup>Medanta Bone and Joint Institute, Medanta - The Medicity, Gurgaon, Haryana, India

**Address for correspondence:** Dr. Sanjay Mahendru, Department of Plastic, Reconstructive and Aesthetic Surgery, Medanta - The Medicity, Sector 38, Gurgaon - 122 001, Haryana, India. E-mail: drsanjaymahendru@gmail.com

## ABSTRACT

Replantations for major amputations of upper extremity have been widely performed. We report a unique case of successful replantation of scapulothoracic avulsion amputation in a child. In this manuscript, we discuss the various challenges faced during the procedure and chances of neural recovery.

## KEY WORDS

Replantation; scapulothoracic avulsion; upper extremity amputation

## INTRODUCTION

Replantations for major amputations of the upper limb have been widely reported and performed at many centres around the world. We report a case of successful replantation of complete avulsion amputation of the right upper limb at scapulothoracic level in a 3-year-old boy. In our literature search, we could not find such a case successfully done.

## CASE REPORT

A 3-year-old boy was brought to the emergency room around 3 h after sustaining an injury while playing in the

fields. His right upper limb accidentally got caught in the belt of a thresher machine and was avulsed from the chest wall. The child was taken to a nearby hospital with the amputated part [Figures 1 and 2] from where he was referred to our hospital.

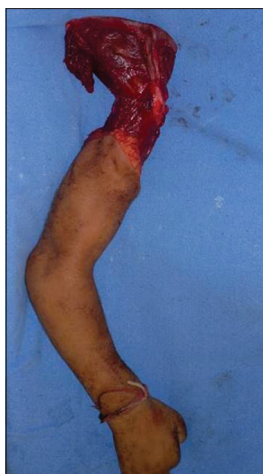On arrival, the child was stable and the amputated limb was well preserved. The patient was evaluated to rule out other injuries and prepared for surgery while an X-ray was done for the amputated part [Figures 3 and 4]. The amputated part was then shifted to the operation theatre for bench dissection.

This is an open access article distributed under the terms of the Creative Commons Attribution-NonCommercial-ShareAlike 3.0 License, which allows others to remix, tweak, and build upon the work non-commercially, as long as the author is credited and the new creations are licensed under the identical terms.

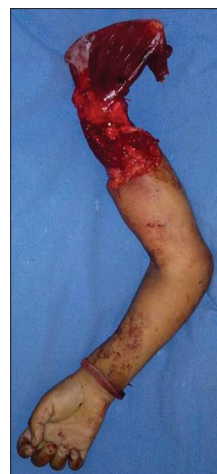**For reprints contact:** reprints@medknow.com

**How to cite this article:** Mahendru S, Khazanchi RK, Brajesh V, Jawed A, Aggarwal A, Singh H, *et al.* Replantation in scapulothoracic avulsion amputation of the right upper limb in a 3-year-old child- A preliminary report. Indian J Plast Surg 2016;49:279-82.

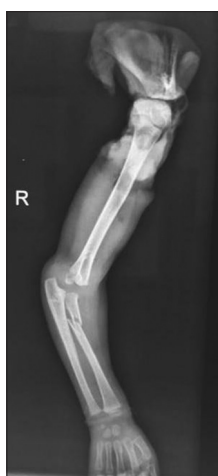Access this article online	
Quick Response Code:	Website: www.ijps.org
	DOI: 10.4103/0970-0358.191308



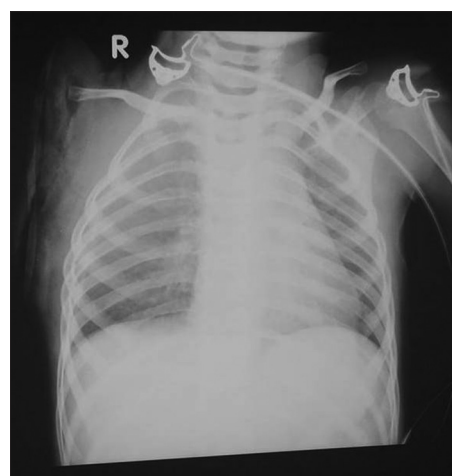
**Figure 1:** Amputated limb (dorsal aspect)



**Figure 2:** Amputated limb ( ventral aspect)



**Figure 3:** X-ray of the amputated part



**Figure 4:** X-ray of the stump

On examination, the skin disruption was found to be at axillary level while the upper limb had avulsed from the chest wall along with the scapula and its attached muscles (scapulothoracic dissociation).

The deltoid muscle was disrupted from its origin and found in the amputated stump with the skin retracted distally over it. The cut ends of brachial artery and its accompanying vein were found retracted under the biceps muscle. The brachial plexus was disrupted at cord level with distal cut ends of medial, lateral and posterior cords found alongside the transected vessels. The posterior cord was found to be of longest length suggesting higher level of avulsion.

After thorough cleaning of the amputated limb, the brachial artery and its accompanying vein were dissected out and tagged. The brachial artery was cannulated, and infusion of cold heparinised saline (5000 units in 500 ml)

started. The cut ends of medial, lateral and posterior cords were also tagged.

A fasciotomy was done on bench with diathermy. Meanwhile, the patient was shifted to the operating room and anaesthetised. On exploration of the amputation stump, the axillary artery was found to be transected after the branch to the latissimus dorsi muscle. The axillary vein was found divided at the same level. The proximal cut ends of medial and lateral cord were found and tagged. The posterior cord was not found in the wound, and an incision was given in the supraclavicular region for exploration of the brachial plexus. However, the proximal end of the posterior cord could not be found.

Since the level of transection of the axillary artery was after the take-off of the thoracodorsal and circumflex scapular arteries, the anticipated blood supply to the scapular

muscles after replantation would have been doubtful. Furthermore, the approach to debride the subscapularis muscle in the event of necrosis following replantation would have been cumbersome and dangerous. Hence, the subscapularis muscle was debrided before replantation. The supraspinatus and infraspinatus muscles were left attached to the scapula as even in the scenario of necrosis of these muscles following replantation, they would potentially be easily approached from the dorsal side.

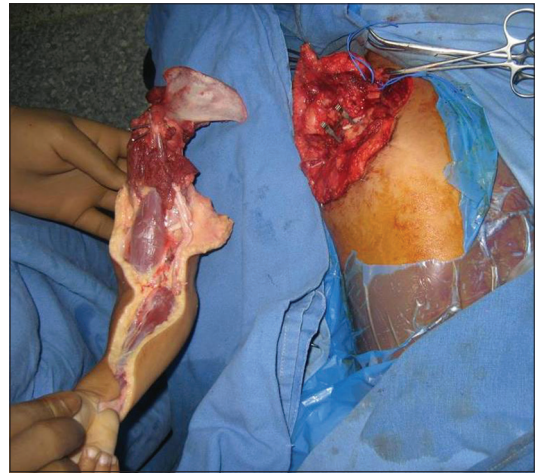The amputated limb was then brought into the operative field [Figure 5]. Bony fixation was achieved with the help of orthopaedic team. The dislocation of shoulder joint was reduced and fixed with a 1.5 mm K-wire. The fracture of glenoid neck was reduced and stabilised with two 1.5 mm K-wires. The scapula was then slipped under the skin dorsally. Acromioclavicular joint was fixed by a K-wire, and acromioclavicular joint capsular repair was performed by figure of 8 non-absorbable sutures. The associated elbow dislocation was managed with closed reduction, and the fracture of ulna was managed by splinting.

Axillary vessels were dissected to the healthy end. Since no bone shortening was feasible in this case, an end-to-end vascular anastomosis was not possible. An 18 cm long saphenous vein graft was harvested from the left lower leg to reconstruct the segmental defects of the axillary artery and vein (8 cm each). Arterial anastomosis was followed by venous anastomosis. Good perfusion was obtained. The total ischaemia time was nearly 8 h (1 h warm/7 h cold). Neural repair was then done. End-to-end repair of the medial and lateral cord was done. The distal end of the posterior cord was anastomosed end to side with the proximal medial cord. The skin was closed partly. There was persistent ooze from the scapular side, which was packed with laparotomy sponges. All wounds were dressed and splint applied. Intraoperatively, the patient was given unfractionated heparin and 3 paediatric units of blood were transfused.

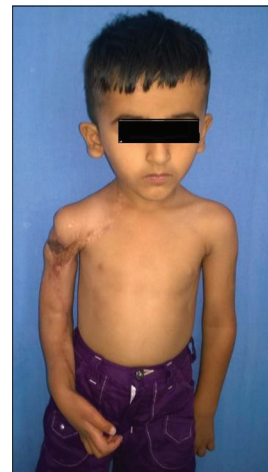Post-operatively, the patient was shifted to the paediatric intensive care unit. The replanted limb continued to be well perfused. After 48 h, the sponge packs were removed from scapular site in the operating room and no further oozing was encountered. The supraspinatus and infraspinatus muscles were found to be necrotic and were debrided.

Post-fasciotomy raw area was covered with split-thickness skin graft on day 20. He was discharged on post-operative

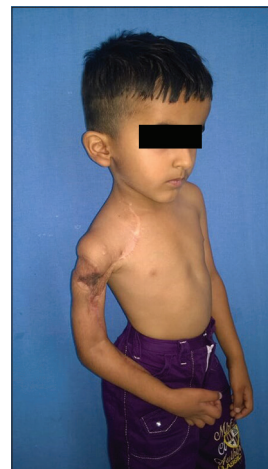day 27. The K-wires were removed on day 90 in the outpatient department, and the arm supported in a sling, and physiotherapy started [Figures 6 and 7]. The last follow-up at 18 months post-operative showed evidence



**Figure 5:** Amputated limb following fasciotomy and prepared amputation stump



**Figure 6:** One year post-operative (frontal view)



**Figure 7:** One year post-operative (oblique view)

of recovery of crude touch sensations up to the digits. No motor recovery has been noted so far.

## DISCUSSION

Major upper limb replantations proximal to the elbow are rare. Nonetheless, they are worthwhile as reported in a large series by Sabapathy *et al.* in 2007 as patients with successful replants put the hand to greater use.<sup>[1]</sup> Furthermore, as reported by Otto *et al.* in 2015, replantation of a traumatically amputated arm leads to good function and higher satisfaction rates than a prosthesis.<sup>[2]</sup> Although few reports are available of successful shoulder level replantation, there is none for scapulothoracic level. Although Venkatarama *et al.* in 2015 have reported a case of scapulothoracic avulsion amputation in a 18-year-old male, the replanted limb had to be amputated due to ensuing sepsis.<sup>[3]</sup>

Hence, to our knowledge, this is the first reported case of a successful replantation of a limb separated at scapulothoracic level.

Literature is rife with reports of cases with scapulothoracic dissociation which is a closed avulsion injury caused by a severe traction injury and associated with massive soft tissue swelling of the shoulder, lateral displacement of the scapula and severe neurovascular injury. Functional outcomes are very poor, and the condition is associated with high mortality.<sup>[4,5]</sup>

Replantation at this level presents many challenges. Scapulothoracic muscles are devascularised and have to be debrided. With no muscles being available for scapulothoracic fixation, the scapula has to be fixed directly to the chest wall. Bone shortening is not possible, and therefore, vascular reconstruction would always involve vein grafts.

Extent of neural recovery in this injury will remain questionable. However, with the patient being a child, a reasonable degree of neural recovery is expected. Furthermore, the replanted upper limb at this level would be better than any available prosthesis. The child and family have been saved the stigma of an amputation which can have serious psychosocial issues. Although the child is doing fine at present, there is still a long road ahead for a reasonable functional recovery, and the secondary reconstructive procedures may be required.

## Declaration of patient consent

The authors certify that they have obtained all appropriate patient consent forms. In the form the patient(s) has/have given his/her/their consent for his/her/their images and other clinical information to be reported in the journal. The patients understand that their names and initials will not be published and due efforts will be made to conceal their identity, but anonymity cannot be guaranteed.

## Financial support and sponsorship

Nil.

## Conflicts of interest

There are no conflicts of interest.

## REFERENCES

1. Sabapathy SR, Venkatramani H, Bharathi RR, Dheenadhayalan J, Bhat VR, Rajasekaran S. Technical considerations and functional outcome of 22 major replantations (The BSSH Douglas Lamb Lecture, 2005). *J Hand Surg Eur Vol* 2007;32:488-501.
2. Otto IA, Kon M, Schuurman AH, van Minnen LP. Replantation versus prosthetic fitting in traumatic arm amputations: A systematic review. *PLoS One* 2015;10:e0137729.
3. Aniketh Venkataram, Naren Shetty, Narendra S. Mashalkar *et al.* Forequarter Replantation and the Lessons Learnt. *Plast Reconstr Surg Open*. 2015 Sep; 3 (9):e509
4. Witz M, Korzets Z, Lehmann J. Traumatic scapulothoracic dissociation. *J Cardiovasc Surg (Torino)* 2000;41:927-9.
5. Zelle BA, Pape HC, Gerich TG, Garapati R, Ceylan B, Krettek C. Functional outcome following scapulothoracic dissociation. *J Bone Joint Surg Am* 2004;86-A: 2-8.