

Original Article

Diagnostic tools in maxillofacial fractures: Is there really a need of three-dimensional computed tomography?

Sheerin Shah, Sanjeev K. Uppal, Rajinder K. Mittal, Ramneesh Garg, Kavita Saggar¹, Rishi Dhawan

Departments of Plastic Surgery and ¹Radiodiagnosis, Dayanand Medical College and Hospital, Ludhiana, Punjab, India

Address for correspondence: Dr. Sheerin Shah, HJ 103, Housing Board Colony, B.R.S Nagar, Ludhiana - 141 001, Punjab, India.

E-mail: sheerinkathpal@gmail.com

ABSTRACT

Introduction: Because of its functional and cosmetic importance, facial injuries, especially bony fractures are clinically very significant. Missed and maltreated fractures might result in malocclusion and disfigurement of the face, thus making accurate diagnosis of the fracture very essential. In earlier times, conventional radiography along with clinical examination played a major role in diagnosis of maxillofacial fractures. However, it was noted that the overlapping nature of bones and the inability to visualise soft tissue swelling and fracture displacement, especially in face, makes radiography less reliable and useful. Computed tomography (CT), also called as X-ray computed radiography, has helped in solving this problem. This clinical study is to compare three-dimensional (3D) CT reconstruction with conventional radiography in evaluating the maxillofacial fractures preoperatively and effecting the surgical management, accordingly. **Materials and Methods:** Fifty patients, with suspected maxillofacial fractures on clinical examination, were subjected to conventional radiography and CT face with 3D reconstruction. The number and site of fractures in zygoma, maxilla, mandible and nose, detected by both the methods, were enumerated and compared. The final bearing of these additional fractures, on the management protocol, was analysed. **Results:** CT proved superior to conventional radiography in diagnosing additional number of fractures in zygoma, maxilla, mandible (subcondylar) and nasal bone. Coronal and axial images were found to be significantly more diagnostic in fracture sites such as zygomaticomaxillary complex, orbital floor, arch, lateral maxillary wall and anterior maxillary wall. **Conclusion:** 3D images gave an inside out picture of the actual sites of fractures. It acted as mind's eye for pre-operative planning and intra-operative execution of surgery. Better surgical treatment could be given to 33% of the cases because of better diagnostic ability of CT.

KEY WORDS

Computed tomography scan in maxillofacial fracture; diagnostic tools in facial fractures; radiography in maxillofacial fractures; three-dimensional computed tomography in facial fractures

Access this article online	
Quick Response Code:	Website: www.ijps.org
	DOI: 10.4103/0970-0358.191320

This is an open access article distributed under the terms of the Creative Commons Attribution-NonCommercial-ShareAlike 3.0 License, which allows others to remix, tweak, and build upon the work non-commercially, as long as the author is credited and the new creations are licensed under the identical terms.

For reprints contact: reprints@medknow.com

How to cite this article: Shah S, Uppal SK, Mittal RK, Garg R, Saggar K, Dhawan R. Diagnostic tools in maxillofacial fractures: Is there really a need of three-dimensional computed tomography?. Indian J Plast Surg 2016;49:225-33.

INTRODUCTION

In a developing nation like India, maxillofacial skeletal injuries account for a large number of emergency department admissions to hospital. A recent increase in the incidence of facial fractures has been noted, because of increase in road traffic accidents.^[1] Restoration of facial aesthetics and function such as mastication, symmetrical movements of the eyeballs and their optimal position to avoid double vision and speech, after facial trauma is essential aims of a plastic surgeon. The primary definitive treatment of open reduction and rigid fixation using mini-microplates and if necessary, immediate bone grafting is now the standard of care, offering the optimal result in facial fractures.^[2] To achieve accurate open reduction internal fixation, we need to delineate fracture lines to maximum possible level. In massive facial trauma patient, clinical evaluation was difficult because of massive oedema or bleed. It was also noted that due to overlapping nature of bones and the inability to visualise soft tissue swelling and fracture displacement, especially in face, radiography was less reliable and useful.^[3] Various conventional radiography views were difficult to carry out in polytrauma patients where cervical spine status was not yet clear. The need for better diagnostic modality ended in 1970, with the advent of computed tomography (CT), which accurately represents facial skeleton and its spatial relations, thereby facilitating surgical exploration, fracture reduction and selection, and contouring of rigid plates. The helical multislice CT is an easier and faster modality to image patients with spine injuries or head injuries.^[4] It has been shown that CT decreases the delay in diagnosis and also decreases the incidence of malunion, nonunion and aesthetic disfigurement, thereby reducing the need of future revision surgeries. Both axial and coronal images obtained from helical CT are used to construct three-dimensional (3D) images using computer software. Various advantages and disadvantages of 2D over 3D have been reported.

This clinical study was done to compare CT face along with 3D reconstruction with conventional radiography for evaluating the maxillofacial fractures preoperatively and effecting the surgical management of these fractures, accordingly.

MATERIALS AND METHODS

This prospective clinical study has been conducted in the Department of Plastic Surgery, on fifty patients with suspected maxillofacial fractures, irrespective of their sex, age and aetiology.

Technique

After stabilisation of the patient, conventional radiography and CT face with 3D reconstruction were done in the same sitting (after written informed consent). The view of X-ray depended on the suspected injured area as per clinical examination. The record of suspected sites of fracture on clinical examination was maintained.

Various views that were done are

- X-ray paranasal sinus (PNS) (Water's view) for fractures of maxilla and zygoma
- X-ray nasal bone lateral (Left/Right) for nasal bone fracture
- X-ray mandible lateral oblique (Left/Right), anteroposterior for mandible fractures.

All conventional radiography was carried on Alpha 600 digital radiography machine. X-ray PNS was obtained at 70 kV and 80 mAs, X-ray nasal bone at 70 kV and 8 mAs and X-ray mandible (all views) at 64 kV and 32 mAs.

Subsequently, CT face with 3D reconstruction was done. The CT used in this study was Siemens Somatom Definition AS plus. The volumetric acquisition of data was done at 128 mm × 0.6 mm (slice thickness of 0.6 mm) and the pitch of 0.8 mm. The patients were placed in supine position, and lateral tomogram was obtained to establish the region of the face to be examined. Continued volume scan was taken for the region extending from the chin to a point 3–4 cm above supraorbital margins. The imaging data were then transferred to the computer console, and 3D CT reconstruction was done using Osteo window of kernel H70h very sharp for bones and cerebrum window H30s medium smooth for soft tissue along with axial and coronal images. The reporting of radiographs and CT scans was done by a radiologist from the Department of Radiodiagnosis. The number and site of facial fractures enumerated by conventional radiography were compared to fractures and their site by CT face with 3D reconstruction. Wilcoxon Matched-Pairs Signed-Rank test was used to compare two methods. The value of

$P < 0.05$ was considered statistically significant and $P < 0.005$ was considered as very significant.

RESULTS

It was found that most of the patients in the study were in the age group of 21–30 years. The mean age of the study was 33.7 ± 15.2 years. Most of the patients in the study were males (44), whereas females were only 6 in number. It was observed that 88% patients had facial fractures because of roadside accident. The next common cause was fall from height followed by assault.

On clinical examination, conventional radiography and CT, it was observed that zygoma was the most common suspected site for fracture, followed by mandible, maxilla and then nasal bone [Table 1].

Table 2 shows the site and the number of fractures detected on X-ray PNS. The most common finding on X-ray PNS was fracture zygomaticofrontal (ZF) area, found in 15 cases. Hazy maxillary sinus was found in 12 cases. There were ten fractures each located in zygomaticomaxillary (ZM) complex and inferior orbital rim. Eight fractures of nasal pyramid could be appreciated.

Table 3 shows the comparison of a number of zygomatic fractures detected on conventional radiography with CT (both 2D and 3D). It was observed that CT could detect 7 additional ZF suture fractures, more accurately by 2D coronal images. CT could detect 5 additional fractures at inferior orbital rim, more accurately by coronal images. It was also noticed that CT could detect 8 additional fractured at ZM complex ($P = 0.046$), especially accurately by coronal images. Axial images could detect 6 additional zygomatic arch fractures ($P = 0.043$). CT diagnosed four orbital floor fractures, by coronal images, which were totally missed on X-rays ($P = 0.034$). In total, it was found that CT could diagnose 32 additional zygomatic fractures. It was thus very significant ($P = 0.006$) than conventional radiography in detecting these fractures. It was also found that coronal CT images are 100% accurate in detecting fractures of ZF suture, inferior orbital rim, ZM buttress, orbital floor and body. It is also shown that axial images are 100% accurate for arch fractures. It was observed that 3D images are 80–90% accurate in detection of fractures of ZF suture, rim, ZM buttress and arch. It is only 50% accurate in detection of orbital floor fracture.

Table 4 shows the number of additional maxillary fractures found by CT (both 2D and 3D) in comparison to conventional radiography. Axial images detected 5 additional lateral wall fractures, whereas 3D detected 4. CT was thus shown to be significantly useful in detecting lateral maxillary wall fracture ($P < 0.05$). Three additional fractures were detected at anterior maxillary wall by axial images and 2 by 3D. Axial images could demonstrate 3 fractures at posterior maxillary wall and 2 at medial maxillary wall, whereas none was shown by 3D. CT also diagnosed 4 fractures of nasomaxillary suture fractures, which were not clear on X-ray ($P < 0.05$). It was found that axial images were 100% accurate in diagnosing fractures of anterior, posterior, medial-lateral maxillary wall and palatal fractures. Coronal images depict nasomaxillary suture fractures more accurately. The accuracy of 3D images was also $< 2D$ images in visualising posterior and medial maxillary wall fractures. Figure 1 shows

Table 1: Number of fractures detected

Bone	On clinical examination	On conventional radiography	On CT
Zygoma	34	41	73
Mandible	15	17	22
Maxilla	11	13	20
Nose	6	8	11
Total	66	79	126

CT: Computed tomography

Table 2: Fractures on conventional radiography X-ray paranasal sinuses (water's view)

Finding	Left	Right	Total
Fracture ZF suture	9	6	15
Hazy maxillary sinus	5	7	12
Fracture zygomaticomaxillary buttress	5	5	10
Fracture inferior orbital rim	5	5	10
Nasal pyramid fracture	5	3	8
Fracture zygomatic arch	3	1	4
Zygomatic body fracture	1	1	2
Palate fracture			1

ZF: Zygomaticofrontal

Table 3: Comparison between zygomatic fractures on X-ray and computed tomography

Fracture	X-ray	2D-axial	2D-coronal	3D-CT	Total on CT	P
ZF suture	15	20	22	18	22	0.101
ZM buttress	10	15	18	16	18	0.046
Inferior orbital rim	10	12	15	12	15	0.117
Arch	4	10	8	9	10	0.043
Orbital floor	0	2	4	2	4	0.034
Fracture body	2	4	4	4	4	0.143
Total	41	63	71	61	73	0.006

2D: Two-dimensional, CT: Computed tomography, 3D: Three-dimensional, ZM: Zygomaticomaxillary, ZF: Zygomaticofrontal

radiological images of a patient with mid face fractures as seen on X ray and CT.

Table 5 shows site and number of mandibular fractures detected by conventional radiography and CT. It was observed that X-ray could diagnose seven fractures at parasymphyseal site. Four cases of subcondylar fracture were detected. X-ray diagnosed three angle fractures and three symphyseal fractures. On CT, it was observed that seven cases of parasymphyseal fractures, eight fractures of subcondylar area were detected. Angle fracture was found in three cases. One fracture of coronoid was detected on CT [Figure 2]. CT diagnosed four additional fractures in subcondylar area ($P = 0.101$). CT was

helpful in detecting a coronoid fracture. CT could not diagnose any additional fractures in parasymphyseal, angle and symphyseal area [Figure 3]. It was found that 2D coronal views were 100% accurate in showing all sites of mandibular fractures, whereas axial CT accuracy ranges from 66% to 90%. The X-ray shows 100% accuracy in fracture detection if present in areas of symphyseal, parasymphyseal and angle. 3D reconstructed images are also 100% accurate in detection of all fracture sites in mandible.

Table 6 shows a number of nasal bone fracture detected on X-ray and CT. On conventional radiography, it was found that there was one case detected with simple undisplaced

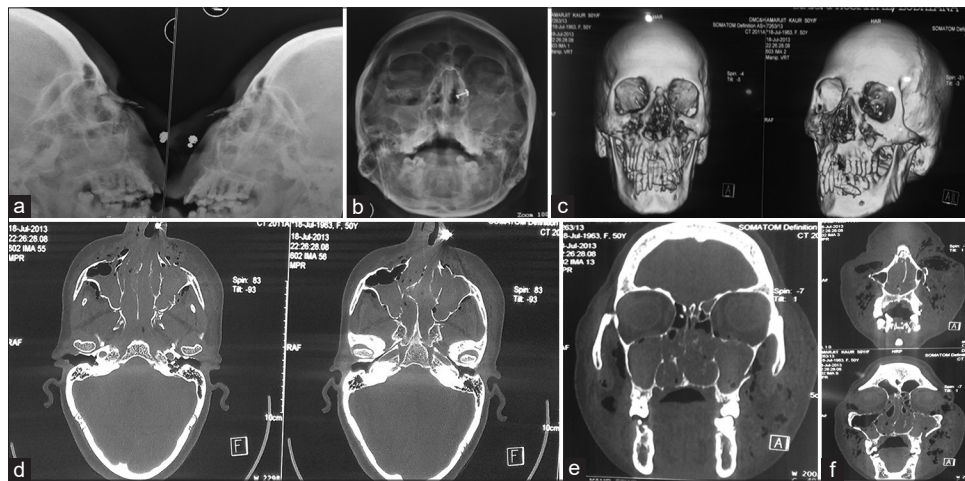


Figure 1: (a) X-ray nasal bone lateral views showing bilateral displaced nasal bone fracture, (b) fracture bilateral nasal bone (pyramid), fracture right body of zygoma, missing lower incisors, (c) fracture inferior orbital rim of right zygoma, fracture body of zygoma, fracture left lateral maxillary wall, fractured lower incisors, fracture left inferior orbital rim, Fracture bilateral nasal bone fracture, (d) axial images, (e) coronal images, (f) fracture bilateral zygomaticomaxillary complex, fracture frontonasal process, fracture nasomaxillary suture and septum

Table 4: Comparison between maxilla fracture on X-ray and computed tomography

Findings	X-ray	2D-axial	2D-coronal	3D-CT	Total on CT	P (X-ray/total CT)
Hazy maxillary sinus	12					
Lateral wall fracture	0	5	4	4	5	0.035
Anterior wall fracture	0	3	2	2	3	0.096
Posterior wall fracture	0	3	2	0	3	0.096
Medial wall fracture	0	2	2	0	2	0.190
Nasomaxillary fracture	0	3	4	3	4	0.049
Palate fracture	1	3	3	3	3	0.170
Total	13	19	17	12	20	0.90

2D: Two-dimensional, CT: Computed tomography, 3D: Three-dimensional

Table 5: Comparison between mandibular fracture on X-ray and computed tomography

Fractures	X-ray	2D-axial	2D-coronal	3D-CT	Total on CT	P (X-ray/total CT)
Parasymphyseal	7	7	7	7	7	NA
Subcondylar	4	6	8	8	8	0.101
Angle	3	2	3	3	3	NA
Symphyseal	3	3	3	3	3	NA
Coronoid	0	0	1	1	1	0.117
Total	17	18	22	22	22	0.107

NA: Not available, 2D: Two-dimensional, CT: Computed tomography, 3D: Three-dimensional

Table 6: Comparison between nasal bone fractures on X-ray and computed tomography

Findings	X-ray	2D-axial	2D-coronal	3D	total on CT	P (X-ray/total CT)
Simple undisplaced fracture	1	1	1	1	1	NA
Simple unilateral displaced fracture	3	3	3	3	3	NA
Simple unilateral displaced fracture with septal fracture	0	1	1	1	1	0.210
Simple bilateral displaced fracture	3	2	2	2	2	0.190
Simple bilateral displaced fracture with septal fracture	0	3	3	3	3	0.096
Comminuted fracture	1	1	1	1	1	NA
Total	8	10	11	11	11	0.109

NA: Not available, 2D: Two-dimensional, CT: Computed tomography, 3D: Three-dimensional

fracture, three cases each with simple unilateral displaced fractures, bilateral displaced fracture and one comminuted nasal bone fracture. CT detected one simple undisplaced fracture, three simple unilateral displaced fractures and one unilateral displaced fracture with septal fracture. Two simple bilateral displaced fractures and three simple bilateral displaced fractures with septal fractures were also detected on CT. On comparison of CT with X-ray lateral views, it was found that CT detected one additional simple unilateral displaced fracture with septal fracture and three additional bilateral displaced fractures with septal fracture. Table 7 enumerates number of additional fractures on computed tomography and their surgical management.

DISCUSSION

Traumatic injuries are a global health burden.^[5] Facial trauma, also called maxillofacial trauma, is defined as any physical insult to face. Facial fractures may initially go unnoticed if a patient has multiple system trauma or other pressing medical concerns.^[6] In addition, intoxicated, sedated and intubated patients are unable to clearly report such injuries. Early clinical knowledge of facial fractures could assist in earlier treatment and possible mitigation of related sequelae. Direct and indirect complications of facial fracture can include nerve damage, brain injury, facial cosmetic changes, infections, along with difficulties related to eating, speaking, hearing and seeing.^[7] Furthermore, life-threatening injuries have been reported in 6.2% of facial fractures patients in a Taiwanese study, with mortality causes including haemorrhagic shock and compromised airway.^[8] Diagnosis of these fractures is very important as to decide the treatment plan, analyse the mode of injury and anticipate the functional and cosmetic side effects.

Although not fully sufficient, clinical examination plays a very important role in the initial diagnosis of these

Table 7: Site and the number of additional fractures on computed tomography and their surgical management

Additional fracture		Surgical management
Area	Number	
ZF suture	7	ORIF with plating
ZM complex	8	ORIF with plating
Inferior orbital rim	5	ORIF with plating
Zygomatic arch	6	Closed reduction
Orbital floor	3	ORIF with plating
	1	ORIF with bone graft
Zygomatic body	2	ORIF with plating
Anterior maxillary wall	3	Conservative
Posterior maxillary wall	3	Conservative
Lateral maxillary wall	5	ORIF with plating
Medial maxillary wall	2	Conservative
Nasomaxillary suture	4	ORIF with plating
Sub condylar	3	ORIF with plating
	1	Intermaxillary fixation

ORIF: Open reduction internal fixation, ZM: Zygomaticomaxillary, ZF: Zygomaticofrontal

fractures, especially with findings such as asymmetry of the face, palpated injuries and facial pain such as discomfort from contracting jaw muscles. The diagnostic modalities most commonly used for diagnosis are conventional radiography and CT. Various studies report advantages and pitfalls of conventional radiography as well as CT, separately in diagnosing facial fractures.

In the present study, the most common age group affected was 21–30 years (19/50) followed by 31–40 years (9/50). The mean age group affected was 33.7 years. In a similar study by van Hoof *et al.*,^[9] the most common age group to get facial fractures in European countries is 20–30 years. People of this group are more engaged in rash driving, violence and dangerous sport activities as compared to other age groups, thereby increasing incidence in this group. In the present study, it was found that the incidence is significantly higher in males (88%) as compared to females (12%). In a study conducted by Sohns *et al.*,^[10] on 784 patients, it was noticed that incidence of facial fractures is 64% in males and 36% in females. Males outnumber females in rash driving and various forms of assaults.

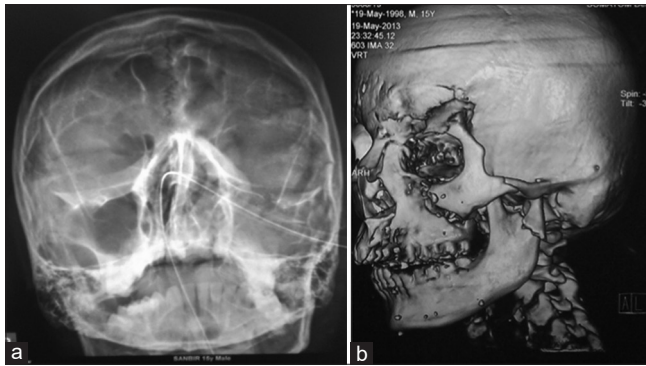


Figure 2: (a) Anteroposterior view of X-ray mandible, (b) three-dimensional computed tomography image showing fracture coronoid process

In our study, the most common mode of injury causing maxillofacial fractures was reported to be road traffic accidents, found in 44 out of fifty cases (88%), followed by fall from height found in three cases (6%), assault in 2 (4%) and animal hit in 1 case. It has been shown in previous studies^[11,12] that in developing countries, most common mode of injury is road traffic accident. In developing nations, the bad maintenance of roads, poor driving skills, lack of enforcement of traffic rules and regulations such as the use of seat belts and helmets are probable reasons responsible for extensive maxillofacial fractures. In developed nations, assault is the most common cause.^[13]

It was found in our study that on clinical examination, conventional radiography and CT, most common area of suspected fractures was orbitozygomatic followed by mandible fractures, maxillary fractures and nasal fractures. It was found in our study that almost all fractures were more common on the left side. This is perhaps due to the aetiology that most of the affected road traffic accident cases were on motorbikes, and they usually tend to fall on the left side as the opposite side traffic is from right, in India.

Sohns *et al.*^[10] and Smith *et al.*^[6] in their study, also found orbitozygomatic area as most commonly fractured region followed by maxillary and then nasal area.

For suspicion of maxilla, zygoma and orbital fractures, the view of radiography done was X-ray PNS water's view. This view also gave information on nasal pyramid fractures. Our study depicts the advantage of CT in diagnosing various zygomatic fractures as compared to conventional radiography. It has been shown that CT with 2D images and 3D reconstruction significantly increases the diagnosis of Zygomaticomaxillary complex,

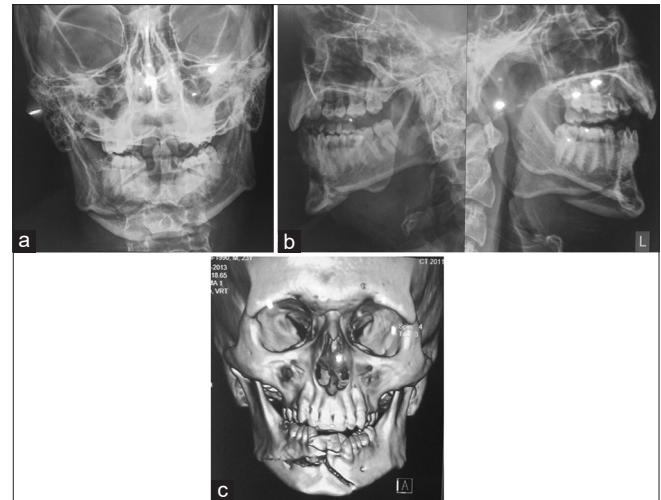


Figure 3: (a) Anteroposterior view of X-ray mandible showing fracture of symphyseal and parasymphyseal area, (b) lateral views of X-ray mandible showing symphyseal and parasymphyseal fractures, (c) three-dimensional computed tomography image showing the same fractures

zygomatic arch and inferior orbital floor ($P < 0.05$). It has been statistically proved in our study that difference in diagnosing a total number of zygomatic fractures by CT as compared to those diagnosed by conventional radiography is significantly very high ($P < 0.005$).

Tanrikulu and Erol^[14] have found a similar result in their study where they compared conventional radiography with CT in diagnosing midface fractures. They reported that CT scan is very significantly superior in diagnosing zygomaticomaxillary complex fracture ($P = 0.001$) and zygomatic arch ($P = 0.0008$) than radiography, especially the axial and coronal cuts. This study also reported a significant difference in diagnosing orbital floor fracture as compared to radiography ($P < 0.001$). They further reported that CT is statistically superior in diagnosing ZF suture than radiography ($P < 0.001$) though the same is not noted in our study ($P = 0.10$). Similar results in diagnosing zygomatic-orbital fractures have been found in a study by Reuben *et al.*,^[15] which shows that the percentage of correct fracture diagnosis is 75.7% with 3D CT and 71% with conventional radiography. It has been reported in a study by Gillespie *et al.*,^[16] that 3D images gave no significant additional information in diagnosing orbital rim fractures. There is a great advantage of CT in comparison with conventional radiography because of its ability to image soft tissue and evaluate extraocular muscles, optic nerve and globe. On further evaluation, it was found that 2D images – axial and coronal, which were taken for reconstruction of 3D images are very informative, especially in case of minimally displaced fractures of midface. In our study, we noticed that coronal

images were better in depicting inferior orbital rim and floor (100% sensitivity) than axial images. Tanrikulu and Erol have noted similar results in a study, that there was a significant difference in diagnosing fractures of rim and floor with 2D images as compared with conventional radiography ($P < 0.01$ and $P < 0.001$, respectively). They also depicted that coronal images are better useful to classify orbital and midface fractures into blowout, tripod and various Le Fort types.^[14] We noticed in our study that the accuracy of 3D images in showing ZF suture, inferior orbital rim, and zygomaticomaxillary buttress is 80–88% as compared to 100% by coronal images. Minor undisplaced fractures are not well shown on 3D because of computerised reconstruction error.

On CT, maxillary areas fractured were appreciable more clearly than conventional radiography, which showed hazy maxillary sinus only. There was a significant difference in diagnostic capability of CT for fractures of lateral maxillary wall ($P = 0.035$). Posterior and medial maxillary wall were better depicted on axial images than 3D. Four cases had nasomaxillary suture fracture on CT, whereas none was reported on X-ray. CT thus had significantly better chances of visualising fractures of nasomaxillary suture ($P < 0.049$). It was also found that palatal fracture was reported in three cases on CT and in one case on X-ray. On further analysis, it was noted that 2D images were very accurate for depicting maxillary fractures. Axial images were 100% accurate for diagnosing fractures of anterior, posterior, medial and lateral maxillary walls, whereas coronal images were 66–87% accurate. For nasomaxillary area, coronal images were 100% sensitive and axial images were 75% sensitive. Tanrikulu and Erol^[14] noted similar finding when they reported that axial images were most useful for imaging of anterior and posterior walls ($P < 0.01$). They also reported that coronal as well as axial views was significantly better for medial and lateral wall ($P < 0.01$) than conventional radiography. We observed that 3D images have lower accuracy in diagnosing areas of anterior, posterior, medial and lateral walls than 2D views. Dos Santos *et al.*^[17] reported similar finding in their study on 56 patients of maxillofacial fractures. The possible reason to the same perhaps was difficulty in assessing thin maxillary sinus walls using 3D tools thereby missing undisplaced fractures. Furthermore, the anterior maxillary wall hides the posterior and medial walls after 3D reconstruction.

In suspected mandibular fractures, various views done were mandibular anteroposterior view, lateral oblique

left and right. On CT, a total of 24 mandibular fractures were found with most common site of fracture being subcondylar, where four additional fractures were found, quantifying that conventional radiography missed these fractures. This study thus shows that the role of CT along with 3D reconstruction in diagnosing mandibular fractures, is appreciable only in subcondylar area, but the difference is not significant ($P = 0.1$). Klenk and Kovacs^[18] have observed similar results in their retrospective study on 121 patients with maxillofacial pathology. They reported that condylar area is satisfactorily demonstrated with posteroanterior mandibular radiographs, and CT in this area does not give significant additional information. In our study, it was noted that coronal and axial images taken to reconstruct to 3D pictures were more informative than reconstructed 3D images. Coronal images were better in depicting 4 additional fractures in subcondylar region. Whereas axial image detected 2 angle fractures, coronal and X-ray could detect 3. It was found that in these areas, the coronal images (accuracy-100%) were better diagnostic than axial (accuracy-60–80%). The extent of medial and lateral rotation of condyle and the width of displacement was better measured on coronal images. This has a significant bearing on pre-operative planning of these fractures. CT has helped in diagnosing a coronoid fracture which was missed on conventional radiography. The possible reason of this could be the overlapping nature of bones. Coronoid fractures are better depicted in 2D and 3D images. The same has been reported by Klenk *et al.* in their study that 3D offers the possibility of directly viewing the fracture line, the size or extent of the fracture, degree and direction of displacement and its spatial relations to the ramus and fossa.

For nasal bone evaluation, X-ray nasal bone lateral left/right were done. X-ray PNS gave information on nasal pyramid fractures. A total of eight patients were found to have nasal bone fracture out of which four were of the left side. On CT, a total number of 11 cases were found to have nasal bone fracture. The two common patterns of fracture were simple unilateral displaced fractures and simple bilateral displaced fractures with septal fractures. Both X-ray and CT could detect one comminuted nasal fracture but the extent of displacement, collapse and widening were better visualised on CT. CT diagnosed one additional simple unilateral displaced fracture with septal fracture, which was unnoticed on X-rays. In total, there were three additional fractures detected by CT. Similar results were found in a study by Baek *et al.*,^[19] where unilateral and bilateral simple displaced fractures formed 69.3% of total

cases (88). They showed that accuracy of nasal bone X-ray in detection of fracture ranged from 66% to 76%. They found CT was 90% accurate in detection of these fractures and missed detecting none cases of simple transverse nasal fracture, which were easily detected on X-ray. They concluded that at a slice thickness of their CT (3 mm), few undisplaced fractures could be easily missed. Similar finding was not recorded in our study, as the slice thickness used by CT data acquisition was 0.6 mm. In our study, 8 out of a total of 11 nasal bone fractures (72%) were detected on X-ray. CT could detect 3 additional fractures, but a comparative higher significance could not be obtained because of low volume of nasal bone fracture cases. The fracture segment, its displacement and overlap were better demonstrated by CT coronal and axial images.

The variations in X-ray exposure, positional restriction in trauma patients and multiple number of views needed for actual detection of a particular site, makes conventional radiography cumbersome and less useful in trauma patients. Thus, a CT scan is easier and faster to obtain in a trauma patient whose spine status is not confirmed. Although the radiation exposure in conventional radiography which is approximately 0.007 mSv to 0.01 mSv for each facial X-ray, is much <1 CT face (2.1 mSv), the advantage that CT does not require positional changes of the neck, makes it more convenient and helpful for early diagnosis. Furthermore, the amount of radiation exposure is within the permissible limits. There is no additional radiation risk in 3D CT reconstruction as it is formatted using 2D images only.

CONCLUSIONS

For a plastic surgeon, to maintain facial aesthetics and function after trauma is a challenge. Early and accurate diagnosis is the key in this situation. Whereas conventional radiography is time-consuming and delayed in case of suspected cervical fractures and other polytrauma conditions, CT is easy, fast and convenient even in polytrauma or cervical trauma patients. Fractures missed on X-rays are easily detected on CT, thereby helping us to plan and fix fractures by open reduction and internal fixation.

The various conclusions made by this study are:

In zygomatic fractures:

- CT is significantly superior than conventional radiography, in detecting additional fractures of:
 - Zygomaticomaxillary complex

- Zygomatic arch
- Orbital floor.
- 2D coronal images are 100% accurate in detection of all zygomatic fractures except arch where accuracy of axial images is more
- The accuracy of 3D images is less than coronal images in detection of undisplaced zygomatic fractures.

In maxilla fractures:

- CT is significantly superior than conventional radiography in detection of additional maxillary fractures of:
 - Lateral maxillary wall
 - Nasomaxillary suture.
- Axial images are 100% accurate in detection of anterior, posterior, medial and lateral maxillary walls, whereas 3D images are less accurate.

In mandible fracture:

- Conventional radiography along with coronal images is appropriate for mandibular fractures.

In nasal fractures:

- CT helps in a better delineation of fractures of nasal bone and their displacement.

Better surgical treatment could be given to 33% of the cases because of better diagnostic ability of CT.

3D images, though are less accurate than multiplanar 2D images, give surgeon/non-radiologist, an easier and faster view of fracture sites and helps in assessment of extent of displacement.

We recommend a longer follow-up of almost 5–10 years, to assess the functional and cosmetic outcome of the patients, who have undergone plating of additional fractures detected by CT.

Financial support and sponsorship

Nil.

Conflicts of interest

There are no conflicts of interest.

REFERENCES

1. Saheeb BD. Influence of positions on the incidence and severity of maxillofacial injuries in vehicular crashes [corrected]. *West Afr J Med* 2003;22:146-9.

2. Prysi AF, Sargent LA, Franklin JD. Rigid facial skeletal fixation: Advances in treatment. *South Med J* 1989;82:727-32, 735.
3. Johnson DH Jr. CT of maxillofacial trauma. *Radiol Clin North Am* 1984;22:131-44.
4. Mayer JS, Wainwright DJ, Yeakley JW, Lee KF, Harris JH Jr., Kulkarni M. The role of three-dimensional computed tomography in the management of maxillofacial trauma. *J Trauma* 1988;28:1043-53.
5. Chandran A, Hyder AA, Peek-Asa C. The global burden of unintentional injuries and an agenda for progress. *Epidemiol Rev* 2010;32:110-20.
6. Smith H, Peek-Asa C, Nesheim D, Nish A, Normandin P, Sahr S. Etiology, diagnosis, and characteristics of facial fracture at a midwestern level I trauma center. *J Trauma Nurs* 2012;19:57-65.
7. Giroto JA, MacKenzie E, Fowler C, Redett R, Robertson B, Manson PN. Long-term physical impairment and functional outcomes after complex facial fractures. *Plast Reconstr Surg* 2001;108:312-27.
8. Tung TC, Tseng WS, Chen CT, Lai JP, Chen YR. Acute life-threatening injuries in facial fracture patients: A review of 1,025 patients. *J Trauma* 2000;49:420-4.
9. van Hoof RF, Merckx CA, Stekelenburg EC. The different patterns of fractures of the facial skeleton in four European countries. *Int J Oral Surg* 1977;6:3-11.
10. Sohns JM, Staab W, Sohns C, Schwarz A, Streit U, Hosseini AS, *et al.* Current perspective of multidetector computed tomography (MDCT) in patients after midface and craniofacial trauma. *Clin Imaging* 2013;37:728-33.
11. Erol B, Tanrikulu R, Görgün B. Maxillofacial fractures. Analysis of demographic distribution and treatment in 2901 patients (25-year experience). *J Craniomaxillofac Surg* 2004;32:308-13.
12. Oji C. Maxillofacial injuries. *Plast Reconstr Surg* 1996;97:866-8.
13. Brown RD, Cowpe JG. Patterns of maxillofacial trauma in two different cultures. A comparison between Riyadh and Tayside. *J R Coll Surg Edinb* 1985;30:299-302.
14. Tanrikulu R, Erol B. Comparison of computed tomography with conventional radiography for midfacial fractures. *Dentomaxillofac Radiol* 2001;30:141-6.
15. Reuben AD, Watt-Smith SR, Dobson D, Golding SJ. A comparative study of evaluation of radiographs, CT and 3D reformatted CT in facial trauma: What is the role of 3D? *Br J Radiol* 2005;78:198-201.
16. Gillespie JE, Isherwood I, Barker GR, Quayle AA. Three-dimensional reformations of computed tomography in the assessment of facial trauma. *Clin Radiol* 1987;38:523-6.
17. Dos Santos DT, Costa e Silva AP, Vannier MW, Cavalcanti MG. Validity of multislice computerized tomography for diagnosis of maxillofacial fractures using an independent workstation. *Oral Surg Oral Med Oral Pathol Oral Radiol Endod* 2004;98:715-20.
18. Klenk G, Kovacs A. Do we need three-dimensional computed tomography in maxillofacial surgery? *J Craniofac Surg* 2004;15:842-50.
19. Baek HJ, Kim DW, Ryu JH, Lee YJ. Identification of nasal bone fractures on conventional radiography and facial CT: Comparison of the diagnostic accuracy in different imaging modalities and analysis of interobserver reliability. *Iran J Radiol* 2013;10:140-7.