

## Original Article

# Effect of external volume expansion on the survival of fat grafts

Raghuv eer Reddy, Subramania Iyer, Mohit Sharma, Sundeep Vijayaraghavan, P. Kishore, Jimmy Mathew, A. K. K. Unni<sup>1</sup>, P. Reshmi<sup>1</sup>, Rakesh Sharma<sup>2</sup>, Chaya Prasad<sup>3</sup>

Departments of Plastic and Reconstructive Surgery and <sup>3</sup>Clinical Pathology, Amrita Institute of Medical Sciences, <sup>1</sup>Animal Research Facility, Amrita Institute of Medical Sciences, <sup>2</sup>Department of Oral Pathology, Amrita Institute of Dental Sciences, Kochi, Kerala, India

**Address for correspondence:** Dr. Raghuv eer Reddy, Department of Plastic and Reconstructive Surgery, Tower 1, Floor 4, Amrita Institute of Medical Sciences, AIMS Ponekkara, Kochi - 682 024, Kerala, India. E-mail: drreddyprs@gmail.com

### ABSTRACT

**Introduction:** External volume expansion (EVE) is one method, which has been utilised for increasing the survival of adipose tissue grafts. EVE releases positive pressure from the graft and also induces intense levels of edema that decreases diffusion of metabolites essential for graft survival initially. The ideal timing of external volume expansion in relation to the injection of the fat to facilitate survival is not yet clear. **Aims and Objectives:** This study was undertaken to evaluate and compare the efficacy of external volume expansion applied at variable time points in relation to the injection of the fat. **Materials and Methods:** Athymic mouse was the animal model and human lipo-aspirate mixed with PRP was used as graft. An indigenous dome shaped silicone device was fabricated to deliver a negative pressure of -30 mm of Hg. The EVE was applied at variable time intervals. At the end of 4 weeks visual, histological and radiological features of the injected fat were compared. The adipose tissue was stained with human vimentin to ascertain the origin of the retained fat. **Results:** All the grafts, which had EVE, had significantly better volume retention and vascularity. The groups which underwent a delayed EVE or prior expansion followed by concomitant graft injection and expansion showed the most optimal vascularity and graft retention. **Conclusions:** A delayed EVE or prior expansion followed by concomitant graft injection and expansion may be the most ideal combinations to optimize graft take. However, on account of the relatively small sample size, there was a limitation in drawing statistically significant conclusions for certain variables.

### KEY WORDS

External volume expansion; fat graft; fat graft with external volume expansion

Access this article online	
Quick Response Code: 	Website: www.ijps.org
	DOI: 10.4103/0970-0358.191322

This is an open access article distributed under the terms of the Creative Commons Attribution-NonCommercial-ShareAlike 3.0 License, which allows others to remix, tweak, and build upon the work non-commercially, as long as the author is credited and the new creations are licensed under the identical terms.

**For reprints contact:** reprints@medknow.com

**How to cite this article:** Reddy R, Iyer S, Sharma M, Vijayaraghavan S, Kishore P, Mathew J, *et al.* Effect of external volume expansion on the survival of fat grafts. *Indian J Plast Surg* 2016;49:151-8.

## INTRODUCTION

**F**at grafting for soft tissue defects and volume expansion presents an appealing alternative or adjunct to reconstruction with flaps or implants because of its simplicity of technique and low morbidity associated with it. However, the unpredictable survival (30%–80%) and the inverse correlation of survival to injection volume have led to skepticism about its utility.<sup>[1-3]</sup> This is further compounded by the requirement for multiple sessions to achieve the desired results.<sup>[4,5]</sup> There has been extensive research on methods to improve engraftment, but only very few of these have been replicated clinically. The mechanism of survival of the injected fat has similarities to that of skin grafting. It has shown that the nature of the recipient site plays a pivotal role in the skin graft take.<sup>[6]</sup> This principle is true in the case of survival of the injected fat, where it relies initially on diffusion and later on new vessels sprouting from the recipient site. Poor vessel density-to-grafted volume ratio and high subcutaneous compartment pressures after fat injection are the likely factors that negatively affect fat engraftment.<sup>[7]</sup> External volume expansion (EVE) devices mechanically stretch and stimulate tissues by suction in a non-invasive manner. Stretch releases the skin<sup>[8]</sup> and it has been postulated by different studies that the mechanism of action could be direct mechanical action on individual cells,<sup>[9,10]</sup> induction of ischemia,<sup>[11,12]</sup> inflammation and soluble mediators<sup>[13]</sup> which stimulates cell proliferation, adipogenesis<sup>[14]</sup> and, most importantly, vascular remodelling. This was the conceptual basis for EVE to be used empirically for pre-operative site preparation for fat grafting.<sup>[15,16]</sup> EVE releases positive pressure from the graft and also induces intense levels of oedema that decreases diffusion of metabolites essential for graft survival initially. A plausible alternative approach may be to re-initiate EVE after an interim period of 1 week, following the grafting during which the graft take is generally believed to have occurred. This could strategically affect the period of remodelling and increase the adipogenic potential of the graft. The timing of EVE in relation to the injection of the fat to facilitate survival is not yet clear. Another unresolved issue is the origin of the surviving fat. Certain studies have suggested that it is not the injected fat that survives, rather that the injected fat provides a stimulus for neo-adipogenesis by its paracrine effect.<sup>[17]</sup>

This study was undertaken to evaluate and compare the efficacy and historadiological changes in fat grafts with

and without EVE applied at variable time points in relation to the injection of the fat. An effort was made to identify the origin of the retained fat. Platelet-rich plasma (PRP) has been reported to have a beneficial effect on fat graft survival.<sup>[18,19]</sup> Hence, we decided to use PRP-enriched fat as the study material rather than fat graft alone.

### Aims and objectives

#### Primary objectives

- To compare the survival of PRP-enriched fat grafts with or without EVE
- To compare the survival and retention of volume of the injected fat without and with EVE at different time points in relation to the fat graft injection – prior, concurrent, 1 week post and a combination of prior and concurrent.

#### Secondary objective

- To see whether the final fat graft volume had its origin from the injected fat or the host environment.

## MATERIALS AND METHODS

The Institutional Review Board and Animal Ethical Committee clearance were taken before the commencement of the study.

### Preparation of the fat graft

Lipoaspirate was harvested by the standard liposuction technique after having procured informed consent from the healthy adult patients presenting for body-contouring procedures. Through a 4 mm incision, the tumescent solution (1000 ml of lactated Ringer's solution containing 30 ml of 1% lidocaine with epinephrine plus 1 mg of epinephrine resulting in a 1:1,000,000 concentration of epinephrine) was infiltrated into the subcutaneous tissue of the surgical site. The lipoaspirate was procured using syringe technique with a blunt-tip 3 mm Mercedes cannula. Aspirate was collected into sterile containers and taken to the laboratory. This lipoaspirate was then centrifuged at 3000 rpm for 3 min. After centrifugation, the upper oily layer from ruptured adipocytes was removed by absorbent pipette from above, and the lowermost layer comprising blood and cellular debris was discarded by draining. The middle layer containing viable adipocyte cells was then transferred into 1 ml syringes for injection.

### Platelet-rich plasma

100 cc of whole blood was taken and processed in the blood bank to get 10 cc of PRP. Due informed consent was taken for this, and the lipoaspirate and PRP were

used in multiple studies being conducted at the institute at the same point in time.

### Animal model

Athymic mice of either sex weighing between 18 and 25 g bred in our animal facility were chosen as the animal model. This allowed negation of the effects of immune rejection of injecting human adipose tissue into the animals.

An indigenous dome-shaped silicone device with an internal diameter of 1 cm [Figure 1] was fabricated and connected to a suction device (Negative Pressure Wound Therapy, Triage Meditech, India) at a pressure of  $-30$  mm of Hg. The device was applied over the dorsum of the mouse, and a sterile adhesive drape (IOBAN – 3M™) was used to hold it in place [Figure 2]. All the mice were housed in a sterile athymic mouse facility maintaining stringent aseptic precautions at all points in time. 0.5 cc of fat graft enriched with PRP (0.4 cc of fat graft + 0.1 cc of PRP) was infiltrated using an 18-gauge needle and a 1 cc syringe over the selected site along the dorsal midline [Figure 3]. The dorsal midline was chosen as the site all other areas could be subject to trauma due to the movement and position of the mice.

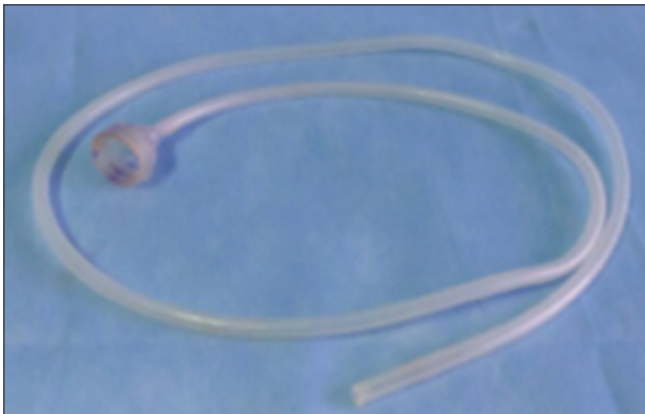


Figure 1: Indigenously created silicon cup

Based on the use of EVE, the study was done in five groups of six mice each:

- Group A: PRP-enriched fat graft alone with no EVE
- Group B: PRP-enriched fat graft and EVE for 2 days prior to the injection (EVE for 2 h each day)
- Group C: PRP-enriched fat graft and EVE for 7 days, which was applied after 7 days from fat grafting) (EVE for 2 h each day)
- Group D: PRP-enriched fat graft with concurrent EVE for 7 days (EVE for 2 h each day)
- Group E: PRP-enriched fat graft with prior EVE for 2 days and EVE for 7 days after fat graft (EVE for 2 h each day) (total of 9 days of EVE).

At the end of 4 weeks from the time of graft injection, each of the mice underwent an ultrasonography to estimate the volume of the residual graft. A Bruker 7-Tesla small animal magnetic resonance image (MRI) coiler MRI was used to procure T1-weighted fat suppressed contrast-enhanced sequences, which were used to analyse fat graft [Figure 4].

The mice were then euthanised at the end of 4 weeks by an overdose of xylazine-ketamine cocktail injected intramuscularly, followed by placement in a CO<sub>2</sub> chamber.




Figure 2: Mice with the external volume expansion set up in place

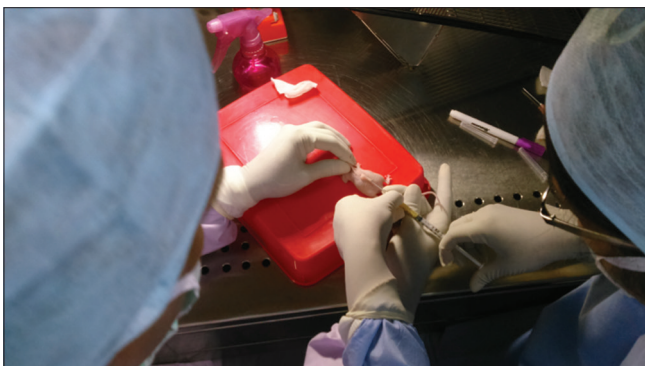


Figure 3: Graph injection along the dorsal midline



Figure 4: Magnetic resonance imaging in progress



Visual examination of dissected specimens was done to look for areas of necrosis in fat graft. Golden yellow colour of fat was considered as healthy, and chalky white was considered as necrotic/dead fat. The skin and sub-cutaneous tissue from the test site were harvested and fixed in 10% neutral-buffered formaldehyde for 24 h and were processed. Sections of the fat pad were stained with haematoxylin and eosin (H and E) and examined using light microscopy. The histological parameters evaluated included the presence of intact and nucleated fat cells, presence of cysts and vacuoles, features of inflammation (presence of infiltration of lymphocytes and macrophages), vascularity and presence of fibrosis. Each parameter was graded as 1 or 2. Grade 1 was assigned when the signs were absent or minimally present. Grade 2 was assigned when the signs were moderately or extensively present.

Poly-l-lysine-coated slides were used for immunohistochemical staining. First, second and third sections from each block of the tissue were considered. CD31 was used to stain all the first sections. Perilipin was used to stain all the second sections. Human vimentin was used to stain all the third sections from the representative samples of each group. Perilipin selectively stains the viable adipocytes, and human vimentin selectively stains only the adipocytes of human origin. Ideally, the staining should have been done on a particular section with a cocktail of perilipin and human vimentin so that the adipocytes are identified and these are looked at, for their origin. Since such a cocktail is not available, we adopted the method described by Stillaert *et al.*<sup>[17]</sup> of selecting a specific section of each block to stain the second section with perilipin and the third with vimentin. This presumably will have reasonably identical histological characteristics. The staining of the immunohistochemical slides was observed, and the areas of maximum staining were considered. The adipocytes and the vasculature in those areas were expressed as a measure of the stained tissue. All the histological and immunostaining interpretations were performed by two experienced pathologists.

## RESULTS

In the current study, visual examination of the fat revealed that all the grafts which were subjected to EVE had a brilliant golden yellow appearance and those without EVE had a pale and chalky white appearance [Figure 5]. At the end of the study period, an ultrasonographic

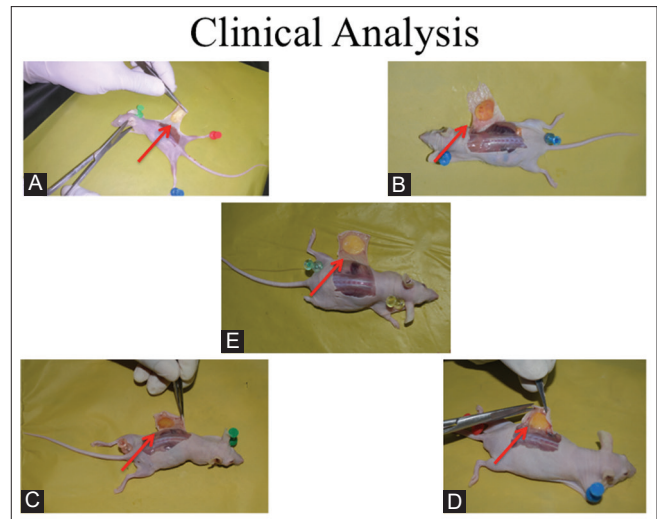
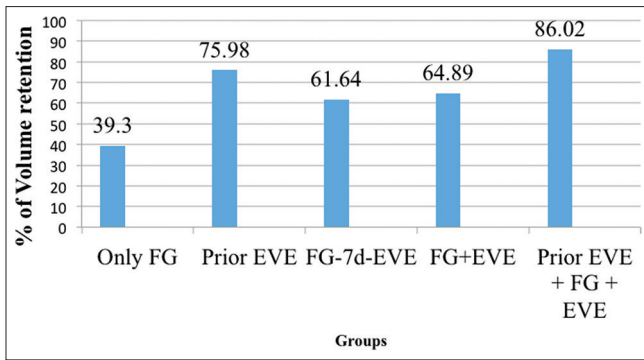


Figure 5: Visual examination of fat graft of each group A to E

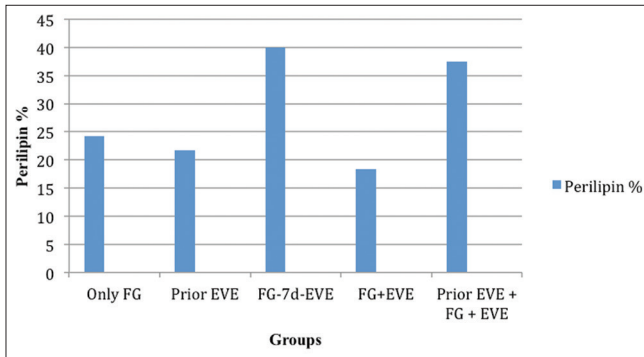
analysis was done to calculate the final volume of fat graft retained. The percentage of the volume of the graft retained at the end of the study period was significantly higher in the groups treated with volume expansion, with the most optimal survival being noted in the groups with prior expansion (75.98%) and with both, prior and concomitant EVE (86.02%) [Graph 1].

On H and E staining, all the grafts, but for one, in the group without EVE, showed moderate to extensive proliferation of the adipocytes. However, on staining with perilipin, grafts which were subjected to EVE after a period of 7 days from injection and those which had both prior and post-graft EVE showed a greater degree of viability, although the difference was not statistically significant [Figure 6 and Graph 2]. The grafts, which were not subjected to expansion and those, which underwent only prior expansion had a significantly lesser degree of cyst and vacuole formation. The inflammatory response, which manifested by the presence of cellular infiltration, was markedly observed only in the mice which underwent prior expansion. The rest of the specimen showed either no or very minimal features of inflammation. The extent of fibrosis was most severe in the group that underwent both prior and post-graft expansion although it was not statistically significant.

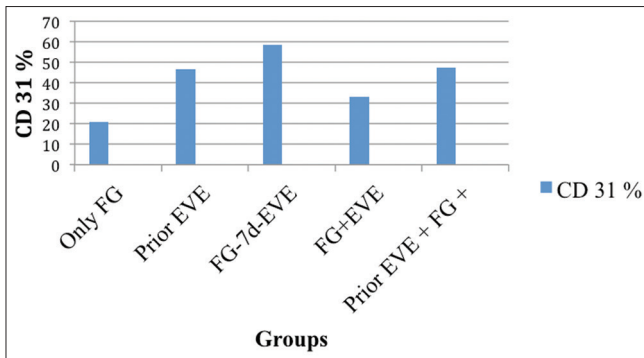
On H and E staining, the degree of vascularity was significantly higher in the grafts treated with EVE which was along the expected lines, on account of the ischaemia-induced neo-adipogenesis. However, on immunohistological staining with CD31, the groups,



Graph 1: Comparison of volume retention across each group



Graph 2: Comparison of adipocyte viability across each group



Graph 3: Comparison of vascularity across each group

which underwent volume expansion, showed a greater degree of vascularity, which was not statistically significant [Graph 3 and Figure 7]. The best vascularity was noted in the group that underwent EVE 7 days after fat grafting, followed by the group that underwent both prior and post-graft EVE. Representative MRI images also correlated with these laboratory findings by showing marginal enhancement. Representative sections of the groups were stained with human vimentin to identify the origin of the viable fat. A few of the samples showed the presence of viable adipocytes in the deeper layers of the skin, which stained negative for human vimentin and as such may be safely concurred to be of murine origin [Figure 8].




Figure 6: Representative perilipin staining of each group (A to E) arrows indicating the cells staining positive for perilipin

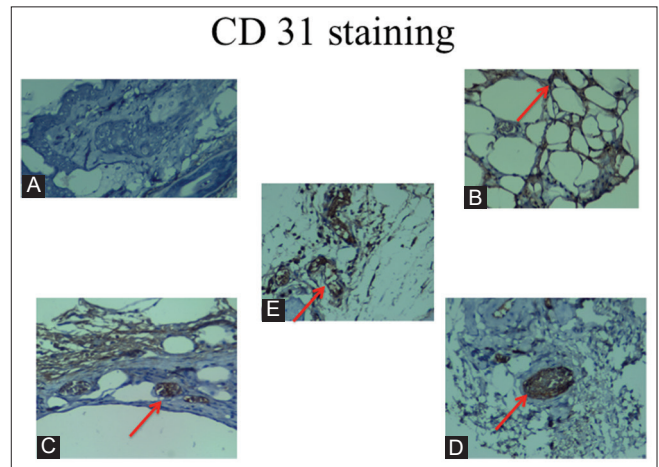


Figure 7: Representative CD31 staining of each group (A to E) arrows indicating cells staining positive with CD31

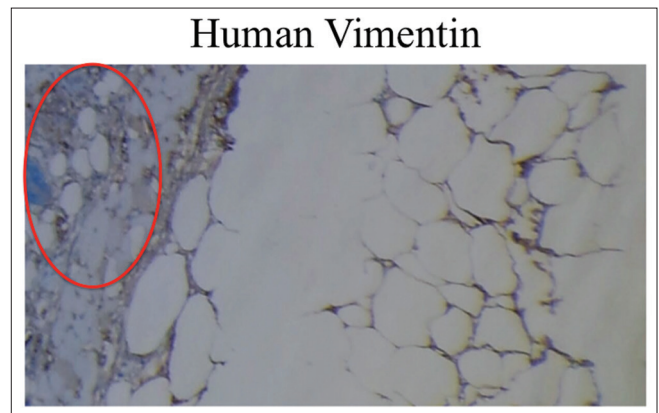


Figure 8: Neo-adipogenesis with negative staining for human vimentin area marked by the ellipse shows the adipocytes staining negative with human vimentin, suggesting them to be of murine origin

## DISCUSSION

Fat grafting has a tremendous regenerative potential through simple injections, but is associated with highly

unpredictable take and survivability. Retention of the fat graft depends on a multitude of factors such as technique of harvest, injection, and preparation of the recipient bed. There has been much work done on ways to improve the technique of harvest and delivery of the fat, but optimising the recipient site has not been paid much attention. EVE mechanically stretches and stimulates tissues by suction in a non-invasive manner by inducing ischaemia and inflammation, which in turn leads to cellular proliferation and vascular remodelling. However, the volume expansion also induces intense levels of oedema that may decrease the diffusion of metabolites critical to fat graft survival during the first few days after engraftment. The effect of EVE on murine and human tissue has been well studied<sup>[7]</sup> as has been the fate of fat grafts.<sup>[1-5]</sup> Studies have also been undertaken to enhance the outcomes by combining these two modalities.<sup>[16,20]</sup> However, literature on the ideal combination of these two techniques for optimisation of the outcome is scanty to say the least with these aforementioned studies being only isolated case reports and small volume animal studies which hint at the combination of prior and post-graft EVE being the most optimal. Various groups have demonstrated that adipose tissue coming in contact with hollow proteic matrices induce neo-adipogenesis in conjunction with the inflammatory milieu.<sup>[21-27]</sup> EVE facilitates the creation of such an environment by creating a pre-expanded cutaneous pocket. In the current study, visual examination of the fat revealed that all the grafts which were subjected to EVE had a brilliant golden yellow appearance and those without EVE had a pale and chalky white appearance. Since healthy fat looks golden yellow in colour clinically, it could be assumed that the fat in the EVE group was more normal on account of better vascularity.

The volume of fat which is retained after grafting is highly variable across various studies.<sup>[1-3]</sup> We injected an exactly equal volume of the graft mixture of 0.5 cc into the dorsum of the mice. At the end of the study period, an ultrasonographic analysis was done to calculate the final volume and compare it to the initial volume. The percentage of volume retention was compared across all the groups. The percentage of volume of the graft retained at the end of the study period was significantly higher in the groups treated with volume expansion with most optimal volume retention being noted in the groups with both, prior and concomitant EVE and with prior expansion. Hence, a combination of prior expansion followed by fat grafting and then concomitant EVE may optimise the volume retention. This may be explained

on account of creation of a proteic hollow matrix as described by Cronin and Dolderer<sup>[18-24]</sup> which improves the graft survival.

In our light microscopy studies with H and E, we compared the samples on the basis of five attributes of the graft, i.e. presence of intact and nucleated fat cells, presence of cysts or vacuoles, inflammation, fibrosis and vascularity. The grafts, which were not subjected to expansion and those, which underwent only prior expansion had a significantly lesser degree of cyst and vacuole formation. The inflammatory response, which manifested by the presence of cellular infiltration, was markedly observed only in the mice, which underwent prior expansion. The rest of the specimens showed either no or very minimal features of inflammation. The extent of fibrosis was most severe in the group that underwent both prior and post-graft expansion although it was not statistically significant. This may also be attributed to the prolonged ischaemic and inflammatory effects of the expansion.

The immunohistological studies involved staining with perilipin, CD31 and human vimentin. Perilipin selectively stains viable adipocytes; CD31 is a vascular endothelial marker and human vimentin very specifically stains the adipocytes of human origin. The presence of membranous staining is an indicator of effectiveness of the staining and this was achieved in all the samples.

On H and E staining, all the grafts, but for one, in the group without EVE, showed moderate to extensive proliferation of the adipocytes. However, on staining with perilipin, grafts which were subjected to EVE after a period of 7 days from injection and those which had both prior and post-graft EVE showed a greater degree of viability although the difference was not statistically significant.

Heit and Lancerotto extensively described the vascular, proliferative and adipogenic effects of EVE on tissues.<sup>[27]</sup> They hypothesised that the blood vessel deformation on account of the stretch and kink of the vessels leads to increased vascular resistance and in turn acts as a potent stimulus for neo-vasculogenesis. Along similar lines, in our study too, on H and E staining, the degree of vascularity was significantly higher in the grafts treated with EVE. On immunohistological staining with CD31, although the groups, which underwent volume expansion, showed a greater degree of vascularity, the difference was not statistically significant. The best



vascularity was noted in the group that underwent EVE 7 days after fat grafting, followed by the group that underwent both prior and post-graft EVE. Representative MRI images also correlated with these laboratory findings by showing marginal enhancement. However, it was not possible to quantify the enhancement in both the groups because we are operating at the extreme limits of the MRI machine. It is limited by the extremely small area of interest, on account of which it was not possible to depict the presence of small vessels or quantify them. We were able to draw a direct correlation between the vascularity and the degree of viability of adipocytes as denoted by the direct correlation coefficient of 1:0.480 between perilipin and CD31. This is to suggest that for every 0.480 fold increase in the vascularity, the viability of adipocytes increases by 1. This indirectly reaffirms the significance of neo-vasculogenesis for the survival of adipocytes and neo-adipogenesis.

Representative sections of the groups were stained with human vimentin to identify the origin of the viable fat. A few of the samples showed the presence of viable adipocytes in the deeper layers of the skin which stained negative for human vimentin and as such might be safely concurred to be of murine origin. This may be on account of the phenomenon of paracrine effect propounded by Stillaert *et al.*<sup>[17]</sup> or on account of the inflammatory effect of EVE.

### Limitations of the study

There are several limitations to this study. Being done in nude mice, the volume of fat that can be injected is highly limited. The study groups could not be more comprehensive, i.e. more combinations such as prior EVE for differing durations and post-injection EVE for differing durations could be added. The contribution from murine adipose tissue in the neo-adipogenesis could have been better understood from a larger sample size or a larger animal model. The study needs to be repeated in a larger animal model such as a pig, using the animal's own fat which may give more information regarding the duration of EVE and the optimum volume that should be injected. The team is executing such a follow-up study. Future prospects include designing custom made suction devices to cater to soft tissue defects of differing shapes which may be an answer to correct difficult deformities such as Romberg's atrophy.

### CONCLUSIONS

All the grafts treated with EVE had superior clinical appearance and significantly better volume retention.

The vascularity too was noted to be better although not statistically significant. Most optimal survival in terms of viable cells and vascularity was noted in the group which had volume expansion done after the first week of grafting. The group, which underwent pre-expansion followed by concomitant EVE, had significantly greater volume retention than all the other groups. Hence, a delayed EVE or prior expansion followed by concomitant graft injection and expansion may be the most ideal combinations to optimise graft take.

However, on account of the relatively smaller sample size, there was a limitation in drawing statistically significant conclusions for certain variables. Similar studies could be planned based on the sample size computed using the results observed in this study.

### Acknowledgements

We acknowledge the generous contribution for this research by the APSI in the form of the APSI 2012 Goa APSICON Fund Research Grant.

### Financial support and sponsorship

This research was granted by the APSI 2012 Goa APSICON Fund Research Grant

### Conflicts of interest

There are no conflicts of interest.

### REFERENCES

1. Carpaneda CA, Ribeiro MT. Percentage of graft viability versus injected volume in adipose autotransplants. *Aesthetic Plast Surg* 1994;18:17-9.
2. Niechajev I, Sevcuk O. Long-term results of fat transplantation: Clinical and histologic studies. *Plast Reconstr Surg* 1994;94:496-506.
3. Gir P, Brown SA, Oni G, Kashefi N, Mojallal A, Rohrich RJ. Fat grafting: Evidence-based review on autologous fat harvesting, processing, reinjection, and storage. *Plast Reconstr Surg* 2012;130:249-58.
4. Ersek RA. Transplantation of purified autologous fat: A 3-year follow-up is disappointing. *Plast Reconstr Surg* 1991;87:219-27.
5. Coleman SR, Saboeiro AP. Fat grafting to the breast revisited: Safety and efficacy. *Plast Reconstr Surg* 2007;119:775-85.
6. Paletta CE, Pokorny JJ, Rumbolo P. Skin grafts. In: Mathes SJ, editor. *Plastic Surgery*. Vol. 1. Philadelphia: Saunders Elsevier; 2006. p. 293-316.
7. Lancerotto L, Chin MS, Freniere B, Lujan-Hernandez JR, Li Q, Valderrama Vasquez A, *et al.* Mechanisms of action of external volume expansion devices. *Plast Reconstr Surg* 2013;132:569-78.
8. Wilhelmi BJ, Blackwell SJ, Mancoll JS, Phillips LG. Creep vs. stretch: A review of the viscoelastic properties of skin. *Ann Plast Surg* 1998;41:215-9.
9. Ingber D. How cells (might) sense microgravity. *FASEB J* 1999;13 Suppl: S3-15.

10. Saxena V, Hwang CW, Huang S, Eichbaum Q, Ingber D, Orgill DP. Vacuum-assisted closure: Microdeformations of wounds and cell proliferation. *Plast Reconstr Surg* 2004;114:1086-96.
11. Chin MS, Ogawa R, Lancerotto L, Pietramaggiore G, Schomacker KT, Mathews JC, *et al.* *In vivo* acceleration of skin growth using a servo-controlled stretching device. *Tissue Eng Part C Methods* 2010;16:397-405.
12. Saxena V, Orgill D, Kohane I. A set of genes previously implicated in the hypoxia response might be an important modulator in the rat ear tissue response to mechanical stretch. *BMC Genomics* 2007;8:430.
13. Chin MS, Lancerotto L, Helm DL, Dastouri P, Prsa MJ, Ottensmeyer M, *et al.* Analysis of neuropeptides in stretched skin. *Plast Reconstr Surg* 2009;124:102-13.
14. Lujan-Hernandez J, Lancerotto L, Nabzdyk C, Hassan KZ, Giatsidis G, Khouri RK Jr., *et al.* Induction of adipogenesis by external volume expansion. *Plast Reconstr Surg* 2016;137:122-31.
15. Zocchi ML, Zuliani F. Bicompartamental breast lipostructuring. *Aesthetic Plast Surg* 2008;32:313-28.
16. Del Vecchio D. Breast reconstruction for breast asymmetry using recipient site pre-expansion and autologous fat grafting: A case report. *Ann Plast Surg* 2009;62:523-7.
17. Stillaert F, Findlay M, Palmer J, Idrizi R, Cheang S, Messina A, *et al.* Host rather than graft origin of matrigel-induced adipose tissue in the murine tissue-engineering chamber. *Tissue Eng* 2007;13:2291-300.
18. Jin R, Zhang L, Zhang YG. Does platelet-rich plasma enhance the survival of grafted fat? An update review. *Int J Clin Exp Med* 2013;6:252-8.
19. Modarressi A. Platelet rich plasma (PRP) improves fat grafting outcomes. *World J Plast Surg* 2013;2:6-13.
20. Lee JW, Han YS, Kim SR, Kim HK, Kim H, Park JH. A rabbit model of fat graft recipient site preconditioning using external negative pressure. *Arch Plast Surg* 2015;42:150-8.
21. Cronin KJ, Messina A, Knight KR, Cooper-White JJ, Stevens GW, Penington AJ, *et al.* New murine model of spontaneous autologous tissue engineering, combining an arteriovenous pedicle with matrix materials. *Plast Reconstr Surg* 2004;113:260-9.
22. Dolderer JH, Abberton KM, Thompson EW, Slavin JL, Stevens GW, Penington AJ, *et al.* Spontaneous large volume adipose tissue generation from a vascularized pedicled fat flap inside a chamber space. *Tissue Eng* 2007;13:673-81.
23. Dolderer JH, Thompson EW, Slavin J, Trost N, Cooper-White JJ, Cao Y, *et al.* Long-term stability of adipose tissue generated from a vascularized pedicled fat flap inside a chamber. *Plast Reconstr Surg* 2011;127:2283-92.
24. Abberton KM, Bortolotto SK, Woods AA, Findlay M, Morrison WA, Thompson EW, *et al.* Myogel, a novel, basement membrane-rich, extracellular matrix derived from skeletal muscle, is highly adipogenic *in vivo* and *in vitro*. *Cells Tissues Organs* 2008;188:347-58.
25. Kelly JL, Findlay MW, Knight KR, Penington A, Thompson EW, Messina A, *et al.* Contact with existing adipose tissue is inductive for adipogenesis in matrigel. *Tissue Eng* 2006;12:2041-7.
26. Stillaert FB, Abberton KM, Keramidaris E, Thompson EW, Blondeel PN, Morrison WA. Intrinsic and dynamics of fat grafts: An *in vitro* study. *Plast Reconstr Surg* 2010;126:1155-62.
27. Heit YI, Lancerotto L, Mesteri I, *et al.* External volume expansion increases subcutaneous thickness, cell proliferation, and vascular remodeling in a murine model. *Plast Reconstr Surg*. 2012;130:541-547.