

Original Article

Silicone Foley's catheter as an effective alternative to Hunter's rod in staged flexor tendon reconstruction of the hand

Tawheed Ahmad, Sheikh Adil Bashir, Mohammad Inam Zaroo, Adil Hafeez Wani, Saima Rashid, Summaira Jan

Department of Plastic and Reconstructive Surgery, Sher-I-Kashmir Institute of Medical Sciences, Srinagar, Jammu and Kashmir, India

Address for correspondence: Dr. Tawheed Ahmad, Department of Plastic and Reconstructive Surgery, Sher-I-Kashmir Institute of Medical Sciences, Srinagar, Jammu and Kashmir, India. E-mail: drtawheedahmad@yahoo.com

ABSTRACT

Context: Staged flexor tendon reconstruction is most suitable treatment method for extensive zone II tendon injuries. The Hunter's rod used in this procedure is costly and not easily available, which adds to the miseries of both patients as well as treating surgeon. **Aims:** The aim of this study is to evaluate the results of staged zone II flexor tendon repair using silicone Foley's catheter as a cheaper and readily available alternative to Hunter's rod. **Settings and Design:** This was a prospective study. **Materials and Methods:** Seventy digits in 35 patients were treated by the staged flexor tendon reconstruction using silicone Foley's catheter in place of Hunter's rod, and the patients were followed for an average period of 18 months. Early controlled motion exercise protocol was instituted in all cases. **Results:** As per the Strickland scale, total active motion obtained was excellent in 70%, good in 20%, fair in 7.1% and poor in 2.9% of patients. **Conclusions:** Silicone Foley's catheter is cheaper, easily available and an effective alternative to Hunter's rod in staged flexor tendon reconstruction procedure, yielding high rates of excellent and good results with fewer complications.

KEY WORDS

Hand flexor tendon injury; Hunter's rod; silicone catheter; staged tendon reconstruction; tendon graft

INTRODUCTION

The reconstruction of the scarred flexor tendon system in zone II of the hand remains a challenge for the hand surgeon because the healing tendon tends to adhere to its fibro-osseous tunnel. It was termed

"No Man's Land" by Bunnell because of the poor outcome in range of motion following tendon repair in this zone. The outcome is worse in case of neglected old tendon injuries.^[1]

This is an open access article distributed under the terms of the Creative Commons Attribution-NonCommercial-ShareAlike 3.0 License, which allows others to remix, tweak, and build upon the work non-commercially, as long as the author is credited and the new creations are licensed under the identical terms.

For reprints contact: reprints@medknow.com

How to cite this article: Ahmad T, Bashir SA, Zaroo MI, Wani AH, Rashid S, Jan S. Silicone Foley's catheter as an effective alternative to Hunter's rod in staged flexor tendon reconstruction of the hand. *Indian J Plast Surg* 2016;49:322-8.

Access this article online	
Quick Response Code: 	Website: www.ijps.org
	DOI: 10.4103/0970-0358.197232

The staged flexor tendon reconstruction using a silicone rod in the first stage and a free tendon graft through the pseudosheath formed around the silicone rod in the second stage, as described in 1971 by Hunter and Salisbury,^[2] is the most widely accepted treatment for poor prognosis flexor tendon injuries (Boyes grade 2–5).^[3] However, the Hunter's rod used in staged tendon reconstruction is costly and mostly unavailable, especially in developing countries.^[4] Atik *et al.* replaced Hunter's rod with Foley's silicone catheter, which is readily available at every centre and 50 times less costly than the former.^[5] Our this study was designed to evaluate the results of staged zone II flexor tendon reconstruction using silicone Foley's catheter as a replacement of Hunter's rod.

SUBJECTS AND METHODS

This study was conducted from August 2011 to July 2016, and during this period, 35 patients with delayed presentation of zone II flexor tendon injuries underwent two-stage tendon reconstruction using silicone Foley's catheter.

These included 21 males and 14 females, with a mean age of 23 years (ranging from 14 to 50 years). In total 70 digits, 12 index fingers, 22 middle fingers, 22 ring fingers, 12 little fingers and 2 thumbs were operated. Pre-operatively, injury of patients was graded using Wehbe modification of Boyes and Stark classification system [Table 1]. The first stage of reconstruction was performed at a mean interval of 5½ months (range: 2–24 months) after injury, and the mean duration between two stages was 4 months (range: 3–8 months). Written informed consent was obtained from all patients, and the study was approved by our hospital-based ethics committee. All patients followed the same surgical and post-operative procedure.

Table 1: Wehbe *et al.* modification of Boyes and Stark classification

Grade of injury	Features
Grade 1	Tendon injury only, good soft tissue, supple joints and no significant scarring
Grade 2	Injury to tendon and soft tissue, deep cicatrix from injury or previous surgery
Grade 3	Injury to tendon and contracture of >10° at any joint
Grade 4	Injury to tendon and one or both neurovascular bundles
Grade 5	More than one of the aforementioned injuries and in addition involvement of the palm or more than one finger injured

Operative procedure

The surgical procedure included two stages. All surgeries were performed under general anaesthesia and tourniquet control. Patients underwent aggressive physiotherapy before the first stage to overcome stiffness and achieve maximum passive motion [Figures 1 and 2].

Stage I

Bruner's palmer zigzag incisions were made to provide wide exposure of the flexor tendon from the mid-palm to the centre of distal phalanx.^[6] The injured tendons and scar tissues were excised [Figures 3 and 4].

About 1 cm of the distal flexor digitorum profundus (FDP) stump was preserved. Silicone Foley's catheter (as a replacement for Hunter's rod) was inserted into the rudimental sheaths. The size of Foley's catheters used is given in Table 2. The injured pulleys (A2 and A4) were reconstructed over the implant using excised flexor digitorum superficialis (FDS) tendon. The distal end of the implant was sutured to the distal stump of FDP, and the proximal end of the implant was fixed to the proximal stump of respective FDP tendon in the palm [Figures 5 and 6]. As both ends of the silicone catheter were attached with proximal and distal stumps of flexor digitorum tendon, respectively, hence there was no scar tissue ingrowth within its lumen.

Passive motion exercises were started 1 week after the surgery. The goal was to achieve full passive flexion at metacarpophalangeal and interphalangeal joints.

Stage II

The distal portion of the previous incision at the distal phalanx was used to retrieve the distal stump of the FDP, and an incision at mid of the palm was made to retrieve the proximal junction of the implant and FDP [Figures 7 and 8].

Palmaris longus tendon or plantaris tendon of proper length was procured [Figure 9]. Distal end of the tendon graft was sutured to the distal stump of FDP using modified Kessler's tendon suturing technique by 4-0 prolene suture material. The proximal end of tendon graft was sutured temporarily to the distal end of the silicone catheter and pulled proximally through the pseudosheath formed around the implant [Figure 10]. The proximal end of the tendon graft was sutured with proximal stump of the respective FDP tendon using the Pulvertaft weave

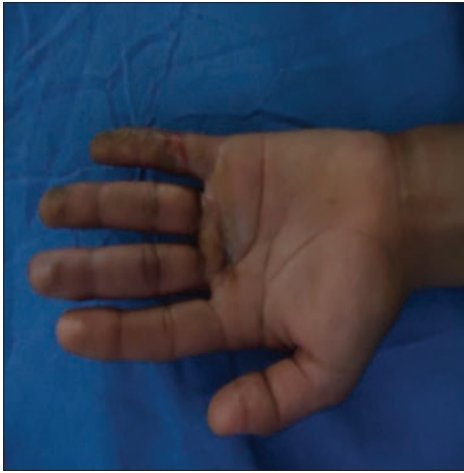

Figure 1: Patient with post-traumatic scar in zone II of the left hand

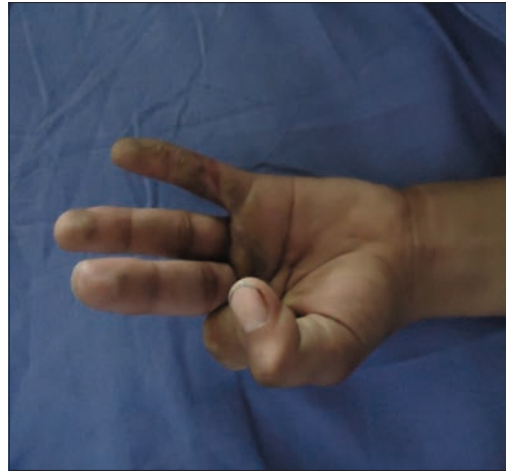

Figure 2: Patient with flexor digitorum superficialis and flexor digitorum profundus injury in zone II of middle, ring and little finger of the left hand

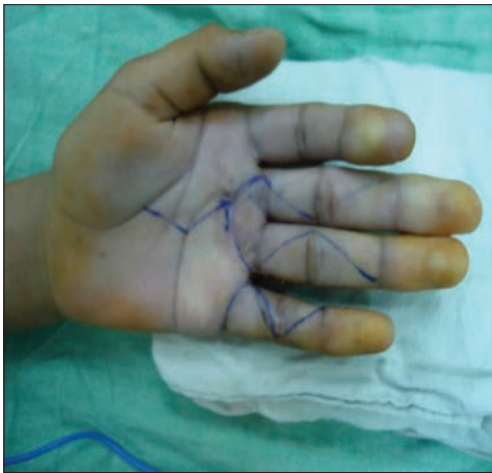

Figure 3: Brunner incision marked

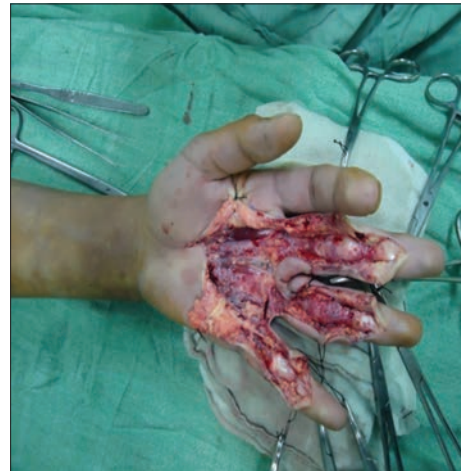

Figure 4: Exposure of scarred zone II through Brunner's incision

suturing method. The tension was adjusted so that the finger was rested in a position approximately the same as the adjacent ulnar digit, and in the fifth finger, a position of flexion was adjusted somewhat greater than that of the fifth finger in the opposite hand [Figure 11]. At the end of surgery, it was ensured that proximal tendon juncture should glide freely on extension of respective digit. Those patients in whom tendon reconstruction was done in all four fingers, tension in the tendon graft was adjusted using the wrist tenodesis effect (on extension of wrist joint, fingers attain flexion posture).

Post-operative care

In the immediate post-operative period, Kleinert's splint was applied with wrist in 30° flexion, metacarpophalangeal joint in 40° flexion and interphalangeal joints kept in extension. After 24 h Kleinert's early active motion, protocol was started, with patient doing active extension and passive flexion using rubber band traction, repeating exercise 10 times every hour [Figure 12]. During sleep

Table 2: Size of silicone catheters used

Size (French)	n (%)
8	5 (7.1)
12	30 (42.9)
14	35 (50)
Total	70

hours, interphalangeal joints were splinted in extension to the prevent development of flexion contractures. Four weeks postoperatively, active flexion was started without resistance, and dorsal blocking splint was discontinued during daytime but continued for night-time splintage. Six weeks postoperatively, the splint was discontinued during sleep hours as well, and active flexion with progressive resistance exercises was started.

RESULTS

Patients were followed for mean duration of 18 months (ranging from 6 to 24 months). The results

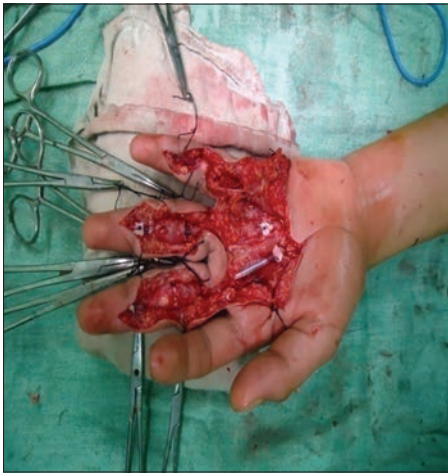


Figure 5: Silicone catheter kept in place as an active implant

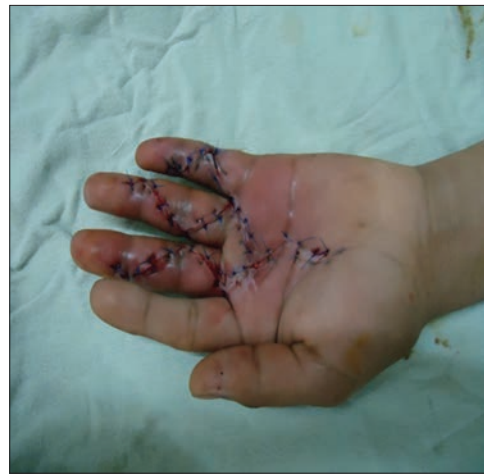

Figure 6: Incisions closed back

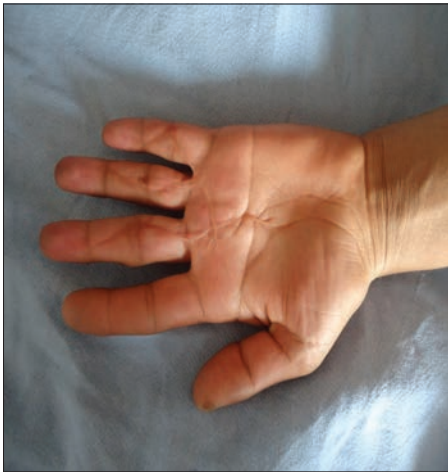

Figure 7: Patient taken for stage II surgery

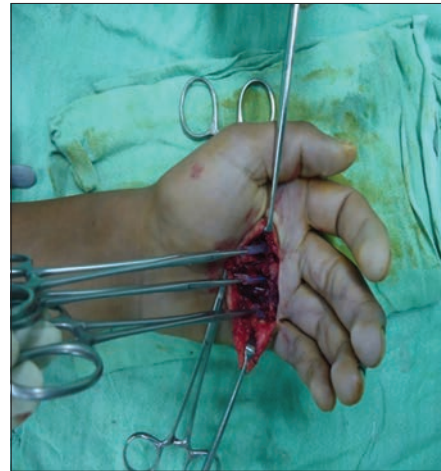

Figure 8: In stage II of surgery, proximal end of silicone catheter exposed through mid-palmar incision

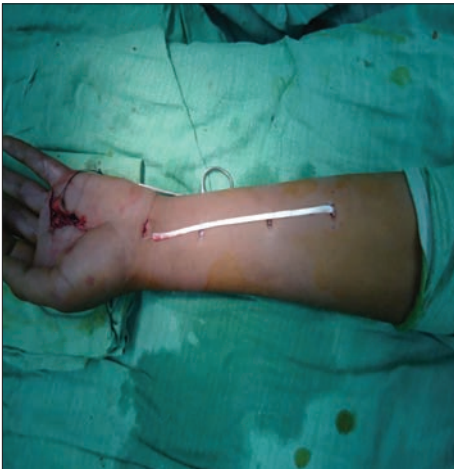

Figure 9: Palmaris longus tendon graft harvested

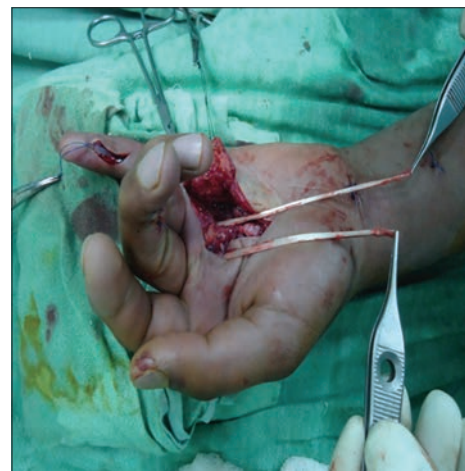

Figure 10: Silicone catheters replaced by tendon graft in stage II surgery

were measured 6 months after the stage II surgery. No patient with <6 months of follow-up was included in the

study. Assessment of our cases was made based on the total active motion system of evaluation.

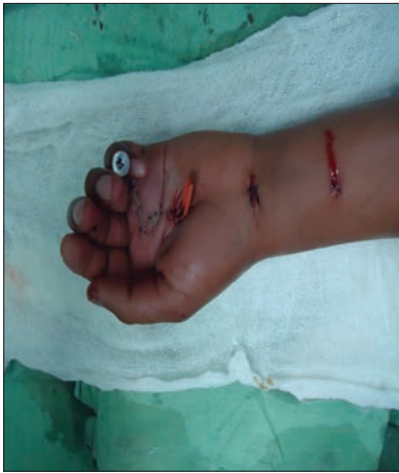

Figure 11: Tendon graft kept in place and incision closed back

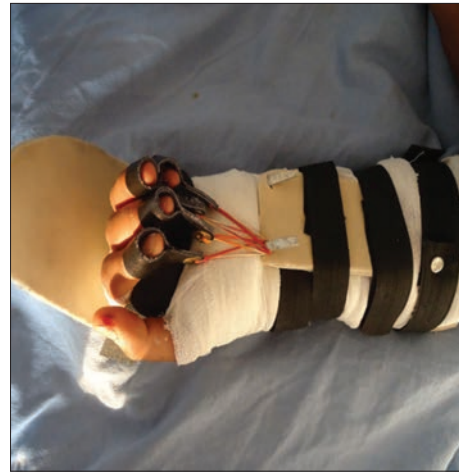

Figure 12: Post-operative Kleinert splint and exercise

$$\% \text{Age of normal total active motion} = \frac{(\text{PIP flexion} + \text{DIP flexion}) - (\text{Extension of deficit of PIP and DIP})}{175^\circ} \times 100$$

PIP = Proximal interphalangeal joint; DIP = Distal interphalangeal joint.

Four grades as per the Strickland scale:

- Excellent = 85%–100%
- Good = 70%–84%
- Fair = 50%–69%
- Poor = 0%–49%.

Of the 70 digits operated, excellent results were seen in 70% (49 digits), good in 20% (14 digits), fair in 7.1% (5 digits) and poor in 2.9% (2 digits) [Table 3 and Figures 13-17].

Infection was observed in two patients after stage I surgery. In one patient, *Staphylococcus aureus* was cultured, and in other patient, *pseudomonas* was cultured. In the first patient, the silicone rod was removed, and in the other patient, the infection responded well to conservative treatment [Figure 18].

Silicone rod got exposed in two patients, in one patient exposed rod was salvaged by a cross finger flap while in another patient exposed rod had to be removed. None of our patients had any skin necrosis, rod buckling, silicone synovitis and proximal or distal graft tenorrhaphy rupture [Figure 19].

DISCUSSION

Old flexor tendon injuries, especially in zone II, are usually associated with complications such as retraction
Indian Journal of Plastic Surgery September-December 2016 Vol 49 Issue 3

Table 3: Results obtained as per Strickland scale

Range of motion	n (%)
85°-100° (excellent)	49 (70)
70°-84° (good)	14 (20)
50°-69° (fair)	5 (7.1)
0°-49° (poor)	2 (2.9)
Total	70

of proximal and distal ends of tendon, adhesion formation and collapse of the fibro-osseous canal. Therefore, tendon grafting is usually needed to restore the flexion function of digits.

In 1936, Mayer and Ransohoff stated that adhesions to transplanted tendon can be prevented by avoiding trauma to the gliding mechanism of the tendon. They found that 90% good or excellent results were obtained in tendon transplantation for paralysed limbs where no damage to gliding mechanism of tendon was involved while as results of tendon transplantation in traumatic fingers were extremely disappointing due to pathological changes occurring after division of flexor tendon.^[7]

In the 1950s, Bassett and Carroll began using flexible silicone rubber rods to build a pseudosheath in badly scarred fingers.^[8] The method was later refined to a two-stage reconstruction of the digital flexor tendons by Hunter and Salisbury.^[2] This procedure was used for patients who had their FDP, FDS and tendon sheath all severely injured, especially in zone II, and it effectively decreased adhesion formation. Hunter's technique is worthwhile for delayed flexor tendon injury in zone II to prevent adhesion formation.^[2,3, 9-20]

In 1998, Kuran *et al.* did experimental study in rats and found pseudosheaths formed following subcutaneous

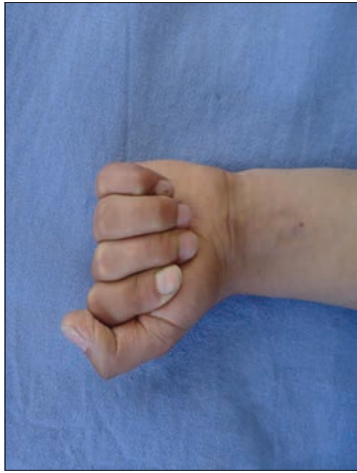

Figure 13: Result obtained after completion of staged tendon reconstruction

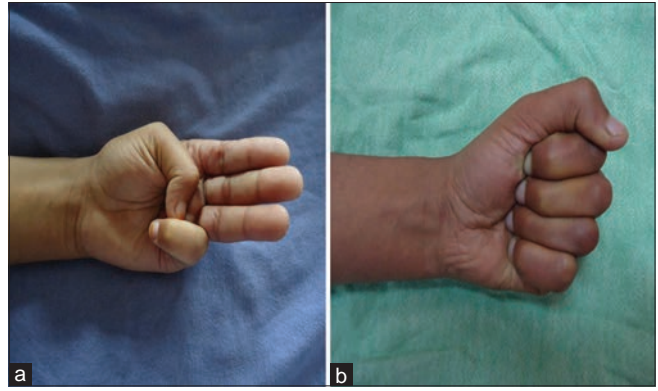


Figure 14: (a) Flexor digitorum superficialis and flexor digitorum profundus injury in index, middle and ring finger (before surgery). (b) After 6 months of completion of staged tendon reconstruction

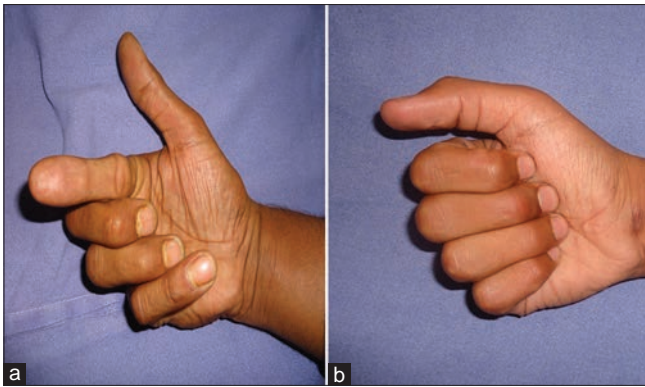


Figure 15: (a) Flexor digitorum superficialis and flexor digitorum profundus injury in right index finger (before surgery). (b) Flexion achieved after completion of staged tendon reconstruction

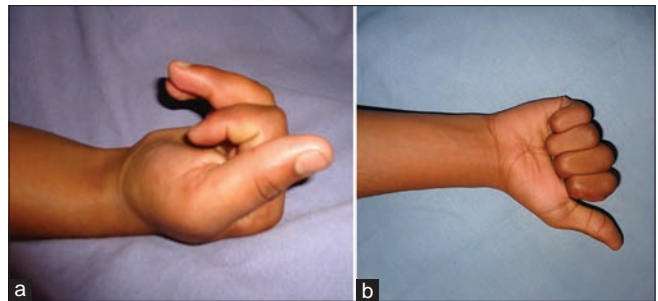


Figure 16: (a) Patient with flexor digitorum profundus injury in right middle and ring finger. (b) Final results after staged tendon reconstruction

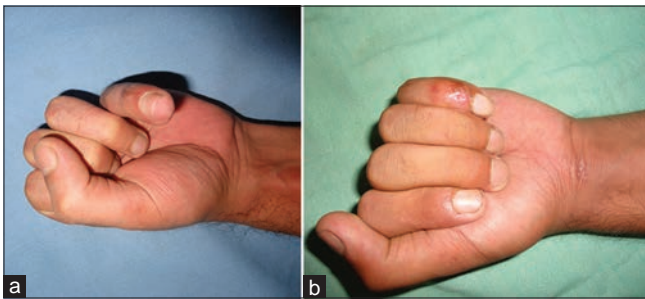


Figure 17: (a) Patient with tendon injury in left little finger. (b) Results obtained after staged tendon reconstruction of flexor digitorum profundus tendon

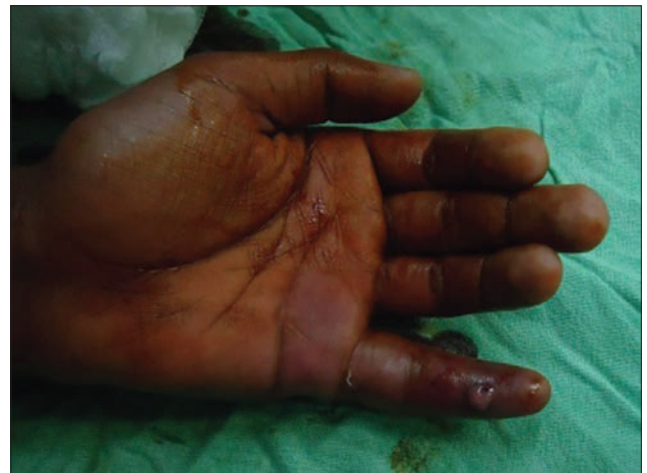

Figure 18: Patient with post-stage I infection in little finger

placement of Hunter's rod and silicone catheter were similar in their thickness, cellularity, tensile strength as well as in their microscopic features.^[4]

Atik *et al.*^[5] also used silicone catheter in place of Hunter's rod and obtained excellent results in 36.4%, good in 27.3%, moderate in 18.2% and poor in 18.2% of operated fingers, whereas results in staged reconstruction of the flexor pollicis longus were excellent in 16.7%, good in 33.33%,

fair in 33.33% and poor in 16.7% of cases. Complications observed in this study were infection in two (11.8%) patients, tendon graft adhesions in three (17.6%) patients and dehiscence of tenorrhaphy in one (5.9%) of the patients.

Considering above studies, we used silicone Foley's catheter in place of Hunter's rod and obtained excellent results in 70%, good in 20%, fair in 7.1% and poor in

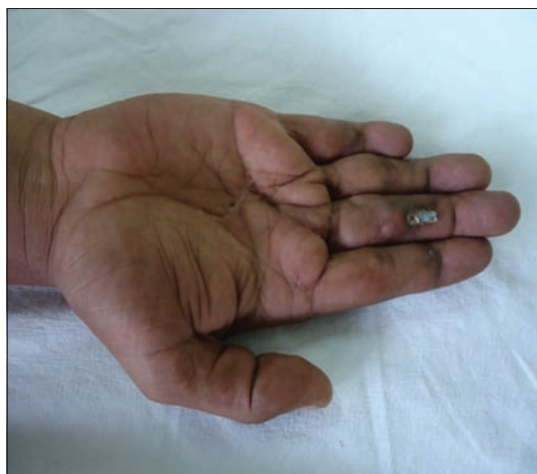

Figure 19: Patient with exposed catheter post-stage I surgery

2.9% patients; we had wound infection in two operated digits (3%) and catheter got exposed in two digits (3%). None of our patients had skin necrosis, silicone synovitis, distal or proximal graft tenorrhaphy rupture or any flexion contracture. Our results were similar and in some cases better than the results obtained in staged tendon reconstruction using Hunter's rod by Hunter and Salisbury,^[2] Frakking *et al.*,^[15] Coyle *et al.*,^[16] Abdul-Kader and Amin^[17] and Sun *et al.*^[18] in their respective studies.

In 2013, Elliot and Giesen presented their experience in dealing with ruptured repairs, tethered repairs and pulley incompetence. Patients taken for staged tendon reconstruction included those who presented after long time of the primary insult, having had no, or bad, previous treatment.^[21]

CONCLUSION

Silicone Foley's catheter is cheaper, easily available and an effective alternative to Hunter's rod in staged flexor tendon reconstruction procedure, yielding high rates of excellent and good results with fewer complications.

Financial support and sponsorship

Nil.

Conflicts of interest

There are no conflicts of interest.

REFERENCES

1. David G, Robert S. Flexor tendon injuries and reconstruction. In: Mathes SJ, Hentz VR, editors. Text Book of Plastic Surgery. 2nd ed. Philadelphia: Saunders Elsevier; 2006. p. 352.
2. Hunter JM, Salisbury RE. Flexor-tendon reconstruction in severely damaged hands. A two-stage procedure using a silicone-dacron reinforced gliding prosthesis prior to tendon grafting. *J Bone Joint Surg Am* 1971;53:829-58.
3. Wehbé MA, Mawr B, Hunter JM, Schneider LH, Goodwyn BL. Two-stage flexor-tendon reconstruction. Ten-year experience. *J Bone Joint Surg Am* 1986;68:752-63.
4. Kuran I, Ozcan H, Turan T, Sakyz D, Bas L. Searching for alternatives to silicone rods in staged tendon reconstruction. *Eur J Plast Surg* 1998;21:317-20.
5. Atik B, Sarici M, Kalender AM, Isik D, Aydin OE. Hunter's technique without Hunter's rod. *Acta Orthop Belg* 2012;78:479-83.
6. Bruner JM. The zig-zag volar-digital incision for flexor-tendon surgery. *Plast Reconstr Surg* 1967;40:571-4.
7. Mayer L, Ransohoff N. Reconstruction of the digital tendon sheath: A contribution to the physiological method of repair of damaged finger tendons. *J Bone Joint Surg* 1936;18:607-16.
8. Bassett CA, Carroll RE. Formation of tendon sheaths by silicone rod implants. Proceedings of American Society for Surgery of the Hand. *J Bone Joint Surg Am* 1963;45:884.
9. American Society for Surgery of the Hand (ASSH). Clinical Assessment Committee Report. Rosemont, IL: Churchill Livingstone; 1976.
10. Unglaub F, Bultmann C, Reiter A, Hahn P. Two-staged reconstruction of the flexor pollicis longus tendon. *J Hand Surg Br* 2006;31:432-5.
11. Smith P, Jones M, Grobbelaar A. Two-stage grafting of flexor tendons: Results after mobilisation by controlled early active movement. *Scand J Plast Reconstr Surg Hand Surg* 2004;38:220-7.
12. Beris AE, Darlis NA, Korompilias AV, Vekris MD, Mitsionis GI, Soucacos PN. Two-stage flexor tendon reconstruction in zone II using a silicone rod and a pedicled intrasynovial graft. *J Hand Surg Am* 2003;28:652-60.
13. Strickland JW. Development of flexor tendon surgery: Twenty-five years of progress. *J Hand Surg Am* 2000;25:214-35.
14. Viegas SF. A new modification of two-stage flexor tendon reconstruction. *Tech Hand Up Extrem Surg* 2006;10:177-80.
15. Frakking TG, Depuydt KP, Kon M, Werker PM. Retrospective outcome analysis of staged flexor tendon reconstruction. *J Hand Surg Br* 2000;25:168-74.
16. Coyle MP Jr., Leddy TP, Leddy JP. Staged flexor tendon reconstruction fingertip to palm. *J Hand Surg Am* 2002;27:581-5.
17. Abdul-Kader MH, Amin MA. Two-stage reconstruction for flexor tendon injuries in zone II using a silicone rod and pedicled sublimis tendon graft. *Indian J Plast Surg* 2010;43:14-20.
18. Sun S, Ding Y, Ma B, Zhou Y. Two-stage flexor tendon reconstruction in zone II using Hunter's technique. *Orthopedics* 2010;33:880.
19. Darlis NA, Beris AE, Korompilias AV, Vekris MD, Mitsionis GI, Soucacos PN. Two-stage flexor tendon reconstruction in zone 2 of the hand in children. *J Pediatr Orthop* 2005;25:382-6.
20. Valenti P, Gilbert A. Two-stage flexor tendon grafting in children. *Hand Clin* 2000;16:573-8, viii.
21. Elliot D, Giesen T. Treatment of unfavourable results of flexor tendon surgery: Ruptured repairs, tethered repairs and pulley incompetence. *Indian J Plast Surg* 2013;46:458-71.