

Prof. Mira Sen (Banerjee) CME Article

Healing ulcers and preventing their recurrences in the diabetic foot

S. Raja Sabapathy, Madhu Periasamy

Department of Plastic, Hand and Reconstructive Microsurgery and Burns, Ganga Hospital, Coimbatore, Tamil Nadu, India

Address for correspondence: Dr. S. Raja Sabapathy, Department of Plastic, Hand and Reconstructive Microsurgery and Burns, Ganga Hospital, 313, Mettupalayam Road, Coimbatore - 641 043, Tamil Nadu, India. E-mail: rajahand@gmail.com

ABSTRACT

Fifteen percent of people with diabetes develop an ulcer in the course of their lifetime. Eighty-five percent of the major amputations in diabetes mellitus are preceded by an ulcer. Management of ulcers and preventing their recurrence is important for the quality of life of the individual and reducing the cost of care of treatment. The main causative factors of ulceration are neuropathy, vasculopathy and limited joint mobility. Altered bio-mechanics due to the deformities secondary to neuropathy and limited joint mobility leads to focal points of increased pressure, which compromises circulation leading to ulcers. Ulcer management must not only address the healing of ulcers but also should correct the altered bio-mechanics to reduce the focal pressure points and prevent recurrence. An analysis of 700 patients presenting with foot problems to the Diabetic Clinic of Ganga Hospital led to the stratification of these patients into four classes of incremental severity. Class 1 – the foot at risk, Class 2 – superficial ulcers without infection, Class 3 – the crippled foot and Class 4 – the critical foot. Almost 77.5% presented in either Class 3 or 4 with complicated foot ulcers requiring major reconstruction or amputation. Class 1 foot can be managed conservatively with foot care and appropriate foot wear. Class 2 in addition to measures for ulcer healing would need surgery to correct the altered bio-mechanics to prevent the recurrence. The procedures called surgical offloading would depend on the site of the ulcer and would need an in-depth clinical study of the foot. Class 3 would need major reconstructive procedures and Class 4 would need amputation since it may be life-threatening. As clinicians, our main efforts must be focused towards identifying patients in Class 1 and offer advice on foot care and Class 2 where appropriate surgical offloading procedure would help preserve the foot.

KEY WORDS

Diabetic foot; limb salvage; offloading in diabetic foot

Access this article online	
Quick Response Code: 	Website: www.ijps.org
	DOI: 10.4103/0970-0358.197238

This is an open access article distributed under the terms of the Creative Commons Attribution-NonCommercial-ShareAlike 3.0 License, which allows others to remix, tweak, and build upon the work non-commercially, as long as the author is credited and the new creations are licensed under the identical terms.

For reprints contact: reprints@medknow.com

How to cite this article: Sabapathy SR, Madhu P. Healing ulcers and preventing their recurrences in the diabetic foot. *Indian J Plast Surg* 2016;49:302-13.

INTRODUCTION

The prevalence of diabetes mellitus is increasing throughout the world. Globally, about 415 million people have diabetes which accounts to 1 in 11 people. India has approximately 69 million people with diabetes amounting to the world's second largest diabetic population.^[1] Modern treatment modalities have increased the life span of people with diabetes and this has in turn led to a proportional increase in the prevalence of long-term complications associated with diabetes, particularly those involving the lower limbs.

Fifteen percent of people with diabetes are affected by a foot ulcer at some time during their lifetime,^[2] and a complicated foot ulcer is one of the common causes of hospital admissions in patients with diabetes.

A dreaded complication of a diabetic foot ulcer is a major lower limb amputation. The World Health Organization estimates that, every 30 s, a leg is lost somewhere in the world because of diabetes.^[3] The incidence of non-traumatic lower extremity amputation is up to 22 times higher in diabetics than in non-diabetics^[4] and about 85% of these lower limb amputations are preceded by a foot ulcer. Majority of these amputations are preventable if these ulcers are treated at an early stage.

For long, clinicians have been concentrating on healing of these ulcers by various medical and plastic surgical techniques and have very frequently been challenged by their stubborn refusal to heal or early recurrence in surgically healed wounds. Research on the pathophysiology of these ulcers has shown that derangement of the biomechanics of the foot plays an important causal relationship in the occurrence of these ulcers.^[5,6] Establishment of the cause of individual ulcers helps plan the appropriate surgical procedure to heal the ulcer and prevent its recurrence.

PATHOLOGY OF DIABETIC FOOT ULCERS

Three major factors play a dominant role in the causation of diabetic ulcers. They are neuropathy, limited joint mobility and ischaemia [Figure 1].

Majority of ulcers in India occur in a neuropathic foot,^[7,8] and infection in such ulcers was found to be responsible in 90% of the amputations in one series.^[7]

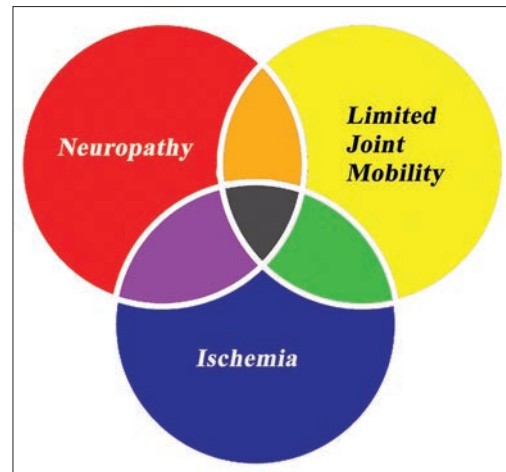


Figure 1: Triad of factors causing a diabetic foot ulcer

NEUROPATHY

Neuropathy of diabetes affects the motor, sensory and autonomic nerves. Motor neuropathy causes intrinsic muscle atrophy which results in deformities, bony prominences due to soft tissue atrophy and disrupts the normal position and orientation of the small joints of the foot and toes [Figure 2]. These abnormalities lead to focal areas of high pressure on the plantar aspect of the foot and abnormal strain patterns in bones due to loss of soft-tissue support. Sensory neuropathy results in loss of protective sensation causing the patient to ignore the warning signs of tissue damage till complications and systemic symptoms occur. Autonomic neuropathy causes imbalances in blood flow and reduction in the moisturization of the skin resulting in cracks and delay in wound healing.

LIMITED JOINT MOBILITY

Limited joint mobility is the stiffness of joints of the hands and feet seen with increased frequency in patients with diabetes mellitus. It results from alterations to the properties of elastin and collagen fibres of ligaments and tendons as a result of non-enzymatic glycosylation and excessive advanced glycation end product (AGE) deposition. Limited joint mobility plays a significant role in the development of plantar ulcers in people with diabetes. People with diabetic neuropathy and ulceration were found to have a higher incidence of reduction in joint mobility compared to non-diabetic people and diabetics without neuropathy. Limited joint mobility is associated with abnormally high plantar pressures^[9] and when combined with sensory

loss leads to an increase in the incidence of plantar ulcers.^[10]

Limited joint mobility combined with shear forces results in the formation of calluses on the sole. These calluses which develop to protect the skin from these high shear forces, eventually turn deleterious as they result in an increase in the focal pressure by about 26%.^[11] Persistent high pressures underneath these calluses lead to the breakdown of the underlying skin and soft tissues resulting in subcallus ulcers [Figure 3]. These ulcers which are initially superficial gradually deepen due to prolonged repetitive trauma and reach tendon, bone or joint causing localised deep tissue abscess or osteomyelitis. Infection can then rapidly spread proximally along the loose tissue and tendon planes and cause life or limb threatening complications.

Pressure redistribution by surgical restoration of joint pliability leads to lower focal plantar pressures and subsequently reduced recurrence of plantar ulcers.^[12]

ISCHAEMIA

A dysvascular foot is defined as a foot without any palpable pedal pulse or a documented ankle brachial pressure index (ABPI) of <0.9 or >1.3 .^[13] Macrovascular vascular disease of the lower limb in diabetes affects the major arteries. Its management depends on the location of the block and requires the involvement of a vascular specialist. In general, suprapopliteal disease responds well to endovascular therapy while infrapopliteal vasocclusive disease has improved long-term patency rates with open surgery. The bypass versus angioplasty in severe ischaemia of the leg (BASIL) study favoured primary open surgery if the patient had a life expectancy of >2 years and had a good vein for a bypass graft. Endovascular therapy was the first choice for patients with a limited life expectancy and those who required prosthetic grafts for a bypass.^[14]

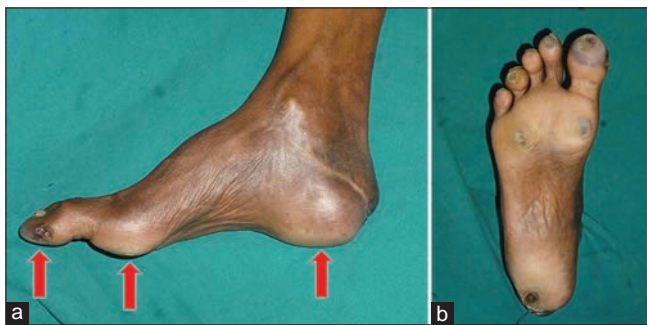

Figure 2: (a) Deformity due to neuropathy (b) prominences with corresponding calluses

Endovascular techniques have, however, evolved at a rapid pace since the BASIL study and drug-eluting stents and balloons have improved the success rates of endovascular therapy for tibial disease.^[15]

MANAGEMENT OF ULCERS

Offloading

Offloading of pressures in the foot is the gold standard for treatment of trophic ulcers of the foot. Offloading has been proven to heal ulcers by reducing the pressures at the high-pressure foci and re-distributing them across the entire weightbearing surface of the foot. Conventionally, offloading the deformed diabetic foot has been done with the help of external devices such as total contact casts, prescription footwear, orthoses, braces and other external offloading devices. These removable devices, however, require a very high degree of compliance for them to be effective and patients have been shown to wear them only 22%–28% of the prescribed time.^[16,17]

Surgical offloading, also known as internal offloading, aims to dissipate pressure throughout the plantar surface of the foot by helping to restore mobility of the stiff joints, restoring correct posture, correcting deformities and maximising preservation of the contact surface of the foot. Surgery is ideally done in patients with pre-ulcerative changes who have failed conservative measures or in those with early uncomplicated ulcers.

Clinical staging of the diabetic foot

Based on our observation in 700 cases of ulcers at the special Diabetic Foot Clinic at Ganga Hospital, we have evolved a staging of the diabetic foot into the 4 categories of incremental severity [Table 1]. Staging of the cases is useful in guiding the line of management amongst various involved specialties and explaining the prognosis to the patient [Figures 4-7].

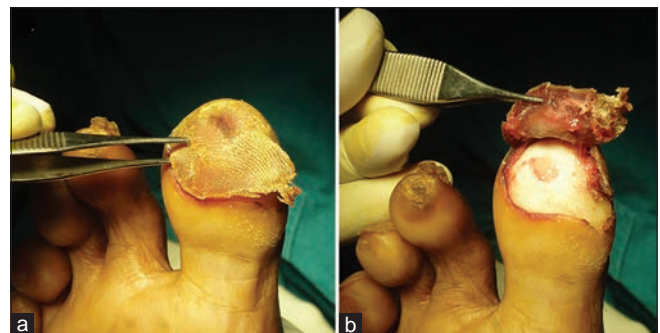


Figure 3: (a) Callosity (b) skin breakdown causing subcallus ulcers

The surgeon's approach to the treatment of a diabetic foot ulcer needs to be different while managing each of the following presentations. A patient with only pre-ulcerative changes and other risk factors such as sensory loss (Ganga Class 1) can be managed with appropriate footwear and other non-surgical supportive measures. A patient with a chronic uncomplicated non-healing ulcer unresponsive to conservative measures (Ganga Class 2) is managed with preventive surgery (surgical offloading). A patient with a complicated ulcer and extensive skin and soft tissue loss (Ganga Class 3) requires reconstructive surgery in the form of

split skin grafts or flaps followed by surgical offloading once the wounds have healed. Neglected ulcers which have progressed to limb- or life-threatening situations (Ganga Class 4) necessitate urgent major amputation. The above-described classification was evolved on the basis of our experience in 700 patients till December 2015. Applying the new classification to a continuous series of 188 patients admitted as inpatients for treatment of foot ulcers during the period of 9 months from January to September 2016, we found that 22.3% of patients fell into Ganga Class 2, 57.9% of patients into Ganga Class 3, and 19.6% into Ganga Class 4. Class 1 patients are treated as outpatients with advice on foot care and are not included in this group of 188 patients.

Table 1: Ganga Hospital staging of the diabetic foot

Staging	Foot type	Description
Ganga Class 1	Foot at risk	No ulcer or pre-ulcerative changes only
Ganga Class 2	Ulcerated foot	Superficial uncomplicated ulcer
Ganga Class 3	Crippled foot	Deep ulcer extending to tendon, joint or bone with Localized Infection with or without Soft tissue loss requiring reconstruction/Critical limb Ischemia with no ulcer or with minor gangrene
Ganga Class 4	Critical foot	Complicated ulcer with threat to limb or life/Unsalvageable foot/ Frank Ischemic Gangrene

The Ganga Class 2 patient, if identified and treated appropriately by surgical offloading, can be prevented from progressing to a Ganga Class 3 or Ganga Class 4 situation and potential limb loss. The surgical methods by which this goal can be achieved and recurrences prevented are the focus of this article.

SURGICAL MANAGEMENT OF GANGA CLASS 2 DIABETIC FOOT (SUPERFICIAL UNCOMPLICATED ULCERS)

To simplify the approach of treating the uncomplicated diabetic foot ulcers (Ganga Class 2) and preventing their

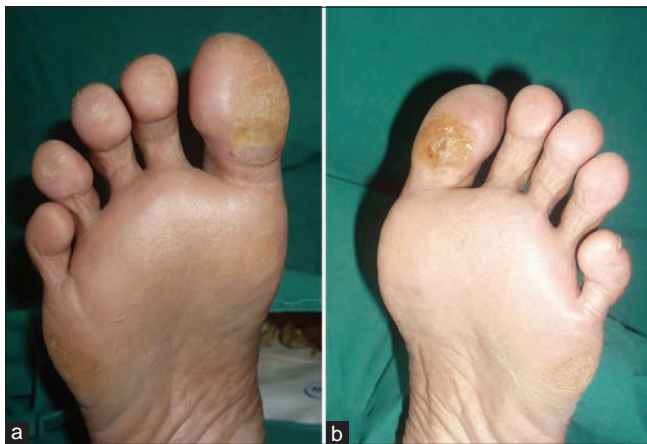

Figure 4: Class 1 - Foot at risk. (a and b) Foot with callus but no ulcer

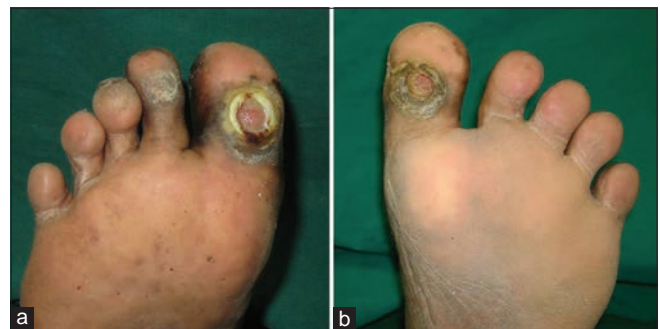

Figure 5: Class 2 - Ulcerated foot. (a and b) Foot with ulcers which do not involve deeper structures and there is no invasive infection

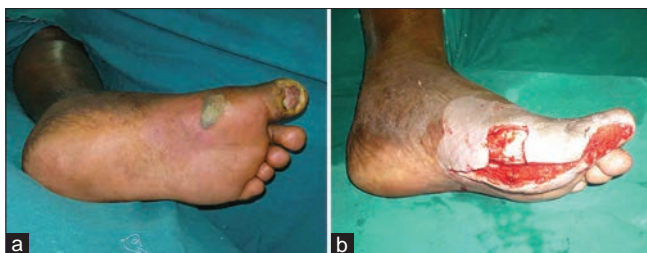

Figure 6: Class 3 - Crippled foot. (a) A complicated great toe ulcer with invasive infection evidenced by swelling, erythema and bleb formation proximal to the ulcer. (b) Same foot after debridement which shows the extent of soft-tissue loss due to infection

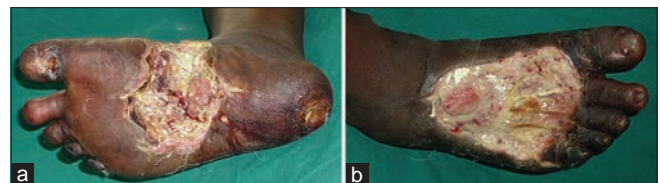

Figure 7: Class 4 - Critical foot. Extensive transmural infection complicating a great toe ulcer causing soft-tissue gangrene both on the (a) plantar and (b) dorsal aspect with systemic sepsis. Patient underwent a below knee amputation

recurrence, this article has divided ulcers according to the following locations:

- Great toe ulcers
- Minor toe ulcers
- Forefoot ulcers
- Mid foot ulcers
- Heel ulcers
- Dorsal ulcers.

Ulcers in each specific location have unique pathomechanics and require a specialised surgical approach for a lasting cure.

Great toe ulcers

Hallux ulcers account for about one-third of all ulcers in the diabetic foot.^[18,19] They are primarily of two types, the plantar hallux inter phalangeal joint (IPJ) ulcer and the plantar hallux subungual ulcer.

The pathogenesis of the hallux IPJ ulcer is closely linked to the stiffness of the first metatarsophalangeal (MTP) joint.^[20] This may manifest clinically as the structural hallux limitus where there is a difficulty in extending the first MTP joint in a non-weightbearing foot beyond 60°.^[20] It may also be present more subtly as a functional hallux limitus which is defined as the inability of the proximal phalanx (PPX) to extend on the first metatarsal head during gait.^[21] Functional hallux limitus is diagnosed clinically by the Hubscher's manoeuvre which involves demonstrating the inability to passively dorsiflex the first MTP joint while the patient is standing on his/her feet.

Both of the above conditions are related to the inelastic plantar common intrinsic tendons passing from the intrinsic muscles to the base of the PPX of the great toe through their respective sesamoids bones. These tendons include the fibres of the plantar fascia which extends from the calcaneal tuberosity to the base of the PPX and the intrinsic muscles of the great toe [Figure 8].

The windlass mechanism of the plantar fascia which passes around the first metatarsal head to be inserted into the base of the PPX and its associated structures help maintain the medial longitudinal arch of the foot during weightbearing by causing flexion of the first ray [Figure 9] during dorsiflexion of the great toe. Conversely, this anatomical arrangement causes flexion of the PPX of the great toe with dorsiflexion of the first ray during weightbearing which results in an increase in the pressure on its head at the level of the IPJ.

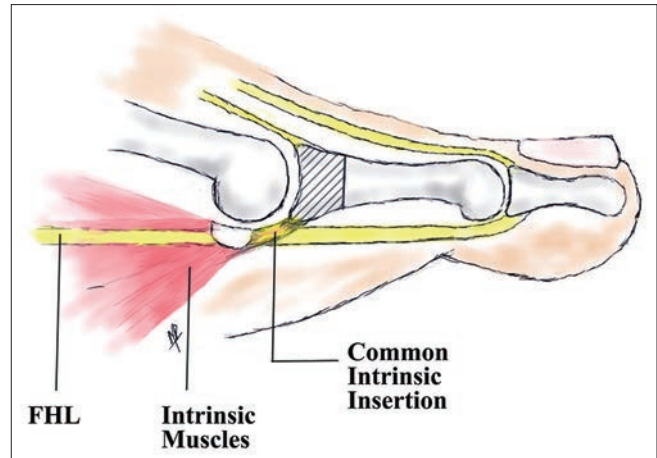


Figure 8: Intrinsic tendons inserting into the proximal phalanx base of the great toe. The shaded part of the bone along with the insertion of the common intrinsic tendons is excised in a Keller arthroplasty

This combined with the loss of elasticity of the plantar soft tissues,^[22-24] generates very high pressures and shear forces at the interphalangeal (IP) joint of the great toe. In a foot devoid of protective sensation, the above factors lead to the formation of a callus under the IP joint of the great toe which if left untreated results in a progressively deepening ulceration of the toe.

Plantar hallux IP joint ulcers are best treated by procedures that aim to restore the mobility of the first MTP joint during gait. In patients who present at an early stage of the disease with only a functional hallux limitus and with a relatively mobile MTP joint, a selective plantar fascia release is done.^[25] This procedure can be done through a longitudinal incision at the medial edge of the plantar facial bands at the level of the tarsometatarsal joints [Figure 10]. The plantar fascial bands to the great toe are divided and excised.

A Keller excision arthroplasty of the first MTP joint is done for patients with a hallux rigidus and recalcitrant IP ulcers unresponsive to conservative measures.^[26,27] The proximal third of the base of the PPX of the great toe along with the insertion of the intrinsic tendons is excised through a dorsal or dorsomedial approach [Figure 11]. The wound is closed primarily over a drain and the patients put on non-weightbearing mobilisation until suture removal. The ulcer is usually left to heal spontaneously after callus removal and scooping of its floor.

A subset of patients have an ulcer of the subungual tip of the great toe. The pathomechanics of these ulcers is different from the IP joint ulcers and is associated with

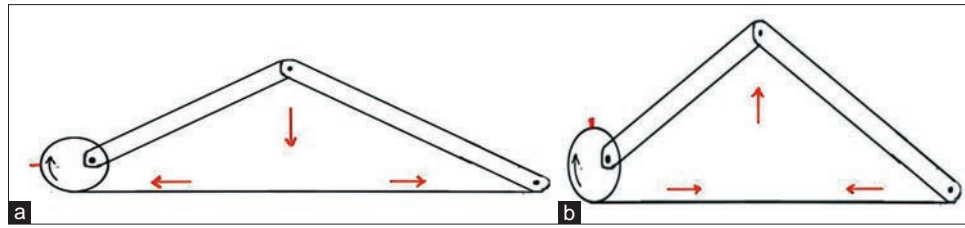


Figure 9: Schematic diagram representing the Windlass mechanism (a) reduction of arch height with relaxation of the plantar fascia (b) the increase in the arch height that happens with the tightening of the plantar fascia during toe dorsiflexion

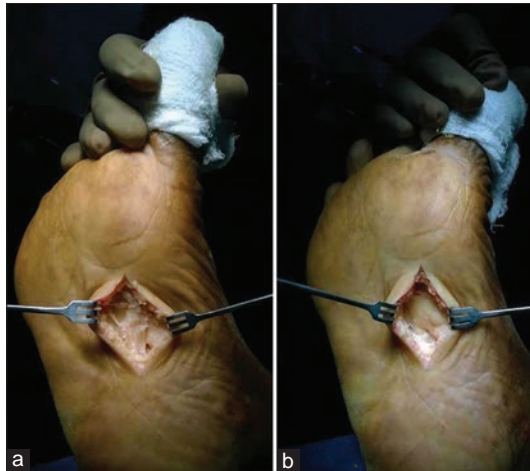


Figure 10: Selective plantar fascia release. (a) Demonstrating the plantar fascial band to the great toe. (b) After excision

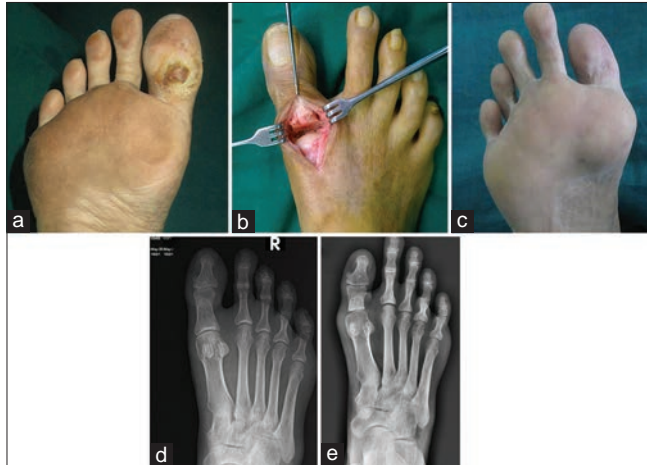


Figure 11: Keller arthroplasty for plantar hallux interphalangeal ulcers. (a) Plantar hallux interphalangeal joint ulcer. (b) The proximal third of the proximal phalanx of the great toe is removed through a dorsal incision. (c) It results in a slightly shortened but mobile and ulcer free digit. (d) Pre- and (e) Post-operative X-rays of the same patient showing the extent of bone resection of the base of the proximal phalanx of the great toe

a dynamic flexion deformity of the IP joint and flexor hallucis longus (FHL) contracture. These ulcers can be healed and can be treated by a tenotomy of the FHL tendon distal to its connection with the flexor digitorum longus (Henry's knot) at the midfoot, most commonly at the plantar base of the great toe [Figure 12].^[28]

Ulcers of the minor toes

Ulcers of the minor toes are usually associated with claw and mallet deformities of the toes which occur due to the intrinsic paralysis associated with motor neuropathy.

These deformities cause the tip of the toes to hit the floor and the dorsum to shear against footwear resulting in ulcers. These ulcers rapidly penetrate to the bone and result in osteomyelitis which is clinically associated with a rapid swelling of the whole toe and is termed as a 'sausage toe' [Figure 13].^[29]

If the infection reaches the long tendon of the toe at the base of the distal phalanx, there is a rapidly spreading tenosynovitis which may endanger the limb itself. It is hence very important to address ulcers of the toes as early as possible. Deformed toes that have passively correctable joint deformities can usually be managed with soft-tissue procedures while those toes with fixed deformities require bony alterations. A mallet deformity with only a DIP flexion contracture can be managed with a tenotomy of the long flexor tendon^[28] done through a longitudinal plantar incision at the level of the base of the toe [Figure 14].

A claw toe with a MTP hyperextension and a PIP and DIP flexion will require intrinsic functional restoration with tendon transfers^[30,31] such as a Girdlestone-Taylor transfer to correct the deformity. Here, the intrinsic function is reconstructed by transferring the long flexor of the toe dorsally to the extensor expansion and correcting the MTP hyper-extension by lengthening the extensors in a Z-fashion [Figure 15]. Fixed deformities may be corrected with arthrodesis of the respective joints in neutral position.

Ulcers of the forefoot

These ulcers located under the metatarsal heads are closely linked to multiple factors such as distal displacement of the fat pads beneath the metatarsal

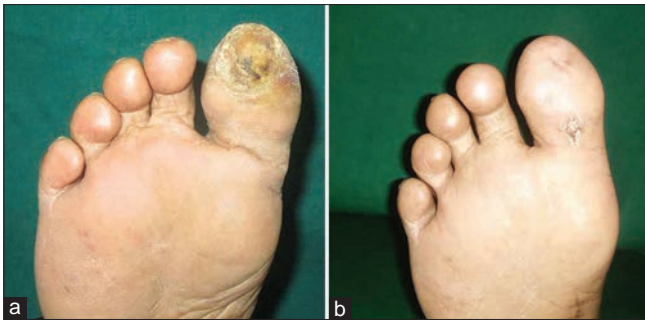

Figure 12: (a) Plantar hallux subungual ulcer (b) ulcer healing after tenotomy of the flexor hallucis longus tendon

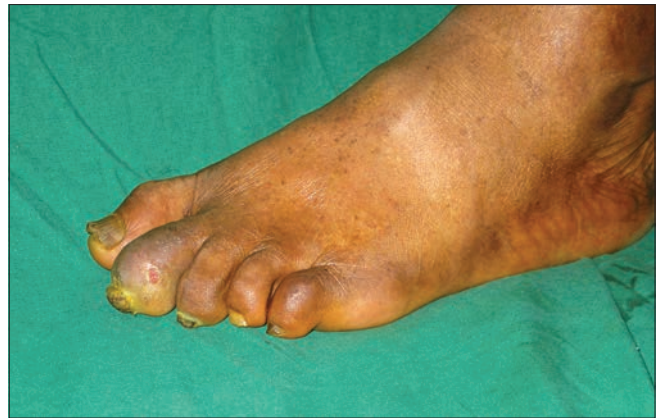

Figure 13: A swollen 'sausage' second toe indicating an underlying osteomyelitis with a sinus

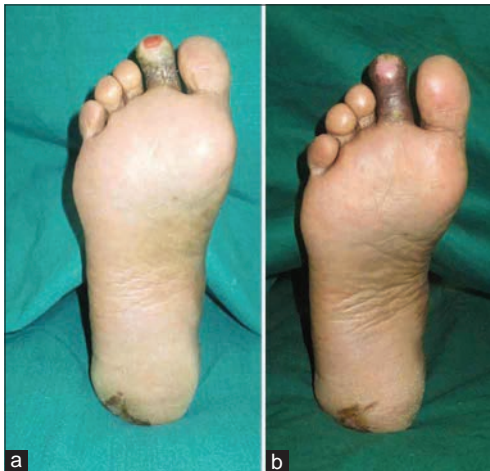

Figure 14: (a) A mallet toe deformity with a tip ulcer (b) well-healed ulcer after flexor tenotomy

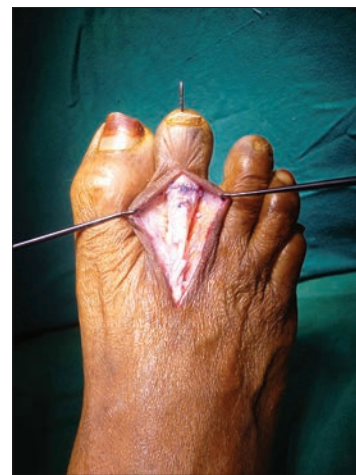

Figure 15: A Girdlestone-Taylor flexor to extensor hood transfer with Z-lengthening of the extensors for claw toe correction

heads, flexed metatarsals, an excessively pronated or supinated foot and most importantly an ankle in equinus due to contracture of the tendo achilles apparatus.^[32-35] A thorough clinical examination helps to decipher the contributory factors which are then addressed appropriately.

Ulcers under the first metatarsal head need to be viewed separately from the minor metatarsals considering its importance in load sharing. Hence most procedures for a first metatarsal head ulcer are aimed at preserving it. An isolated prominent mobile flexed first metatarsal with a clawing of the great toe can be treated by a Jones transfer which involves transferring the extensor hallucis longus to the first metatarsal shaft along with fusion of the IP joint of the great toe [Figure 16].

Pronation of the foot is a combination of three movements abduction of the hindfoot, eversion of the forefoot and dorsiflexion. In an excessively pronated foot, there is proportionally more load bearing along the medial arch and first MTP joint. Release of the tight peroneus longus

and its transfer to the peroneus brevis reduces the pronated posture and helps offload the first metatarsal head.

A soft tissue equinus can be addressed by either a gastrocnemius slide or a gastrosoleus slide [Figure 17] depending on the clinical finding of an isolated gastrocnemius contracture or a combined gastrocnemius-soleus contracture which can be differentiated by the Silfverskiold test.^[36-38] The test is done by testing the dorsiflexion of the ankle with the knee in extension and then in flexion. Limitation of passive dorsiflexion of the ankle to 10° from neutral signifies the presence of an equinus. The presence of an equinus contracture with the knee in extension but not in flexion signifies an isolated gastrocnemius contracture while restriction of dorsiflexion both with the knee extended and flexed signifies the presence of both the gastrocnemius and soleus contracture.

Ulcers over the minor metatarsal heads are addressed by the excision of the involved metatarsal head through a dorsal approach.^[39,40] Here too an associated equinus deformity, if present, is addressed by a gastrocsoleus recession. However, a possibility of subsequent development of new transfer ulcers over the adjacent metatarsal heads must be kept in mind when such an operation is done.

A split tibialis anterior tendon transfer (STATT) can be done to correct an overtly supinated foot (hindfoot adduction, inversion at the forefoot and plantar flexion) with ulcers along the lateral longitudinal arch and fifth metatarsal head. The tibialis anterior is split longitudinally and the lateral half transferred to a new insertion on the lateral aspect of the foot to correct the supination deformity.

Patients who have multiple ulcers or those with new ulcers over previously unaffected metatarsal heads (transfer ulcers) are candidates for a pan metatarsal head resection.^[41] This operation is however reserved for difficult cases as excision of all metatarsal heads results in the alteration of the propulsive phase of the gait cycle.

Midfoot ulcers

Ulcers of the midfoot are usually associated with a structural disorganisation of the midfoot secondary to Charcot neuropathic osteoarthropathy which is a progressive non-infectious destruction of bone and joints. In these patients, high midfoot stress caused by an equinus contracture of the tendoachilles results in multiple fracture dislocations of the midtarsal and tarsometatarsal joints due to altered mechanical strain patterns of the diseased bone. The calcaneus is plantarflexed along with the midfoot by the pull of the tendoachilles while the forefoot get dorsally displaced by the toe dorsiflexors and the stress of forefoot loading, resulting in a rocker bottom deformity with a plantar midfoot bony exostosis. This causes weightbearing

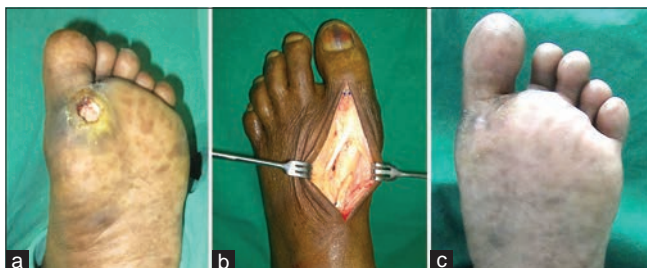


Figure 16: (a) Plantar ulcer beneath the first metatarsal head. (b) Extensor hallucis longus transferred to the first metatarsal. (c) Well-healed ulcer

to be concentrated onto the prominent midfoot and results in ulcers.

Treatment of these ulcers depends on the Eichenholtz stage [Table 2] of the Charcot’s osteoarthropathy. If the bony disease is in the acute stage (Eichenholtz 1), the ideal solution would be to treat the ulcer with traditional plastic surgical techniques and rest the foot. Once the ulcer has healed and the osteoarthropathy turns to the subacute, coalescence stage, the patient is taken up for an orthopaedic correction of the collapse and its stabilisation with implants extending from the metatarsals to the talus and calcaneum.^[42,43] In a foot with a chronic consolidated disease and fused bony elements, the ulcer recurrence can be prevented by excising the bony exostosis through a medial or lateral approach [Figure 18]^[44] and using customised footwear postoperatively.

Hind foot ulcers

Hind foot ulcers are related closely to insufficiency of the gastrocnemius soleus complex just as forefoot ulcers

Table 2: Eichenholtz staging of charcot osteoarthropathy

Stage	Presentation	Description
Stage 1	Acute, development-fragmentation	Marked redness, swelling, warmth; early radiographs show soft tissue swelling, and bony fragmentation and joint dislocation may be noted several weeks after onset
Stage 2	Subacute, coalescence	Decreased redness, swelling and warmth; radiographs show early bony healing
Stage 3	Chronic, reconstruction-consolidation	Redness, swelling, warmth resolved; bony healing or nonunion and residual deformity are frequently present

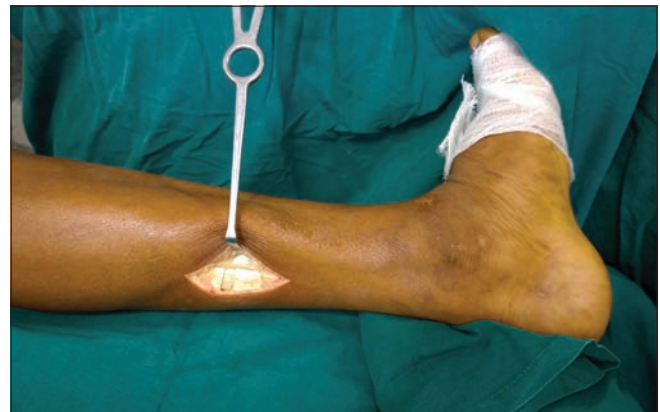

Figure 17: Gastrocsoleus recession done to correct a combined gastrocnemius and soleus contracture. In case of an isolated gastrocnemius contracture, the release is done at a just below the gastrocnemius insertion leaving the soleus tendon fibres intact

are related to its contracture. Inefficient function of the gastrosoleus causes a calcaneal gait with overloading of the hind foot.^[45] When this biomechanical abnormality occurs in the insensate foot, it causes the development of an intractable heel ulcer which is resistant to any form of wound cover. A pedobarogram classically shows little or no forefoot loading in such patients [Figure 19].

The cause of the tendo achilles deficiency must also be ascertained as its correction is imperative for the maintenance of a well-healed hind foot. Some of the most common causes include an unrecognised closed tendoachilles rupture and a Charcot's fracture of the calcaneum where the fractured posterior tuberosity along with the tendoachilles insertion is discontinuous from the rest of the calcaneum. Discontinuity of the tendoachilles insertion causes loss of forefoot load transmission and concentration of the entire load onto the hindfoot. This abnormal calcaneal gait causes a recalcitrant ulcer resistant to any form of wound healing therapy. These heel ulcers can only be stably healed by reconstruction of the tendoachilles-calcaneal-forefoot axis.

Options for tendoachilles reconstruction include a direct repair with or without lengthening and interposition fascia lata graft if a distal stump is available. Tendo achilles substitution by flexor hallucis or peroneal tendon transfers may be used if the distal stump is not available [Figure 20].^[46-50]

In patients who are unsuitable for soft-tissue transfers, ankle fusion in neutral position can be considered to stabilise the foot and allow heel offloading by load transfer to the stable forefoot.

Dorsal ulcers

Dorsal wounds of the toes are usually caused by friction against an ill-fitting footwear. This can be avoided by taking care to prescribe customised footwear with spacious toe boxes to accommodate deformities and making sure that the foot does not move within the footwear. Surgical procedures for deformity correction will reduce the chance of such ulcers. Wounds on the dorsum of the foot are invariably secondary to an infective aetiology. The cause of infection is usually a break in the skin integrity due to autonomic neuropathy which causes dry, itchy skin due to reduced sweating,^[51] intertrigo or a paronychia. The infection then spreads easily along the loose dorsal tissue planes. These ulcers can usually be managed by a good debridement and conventional

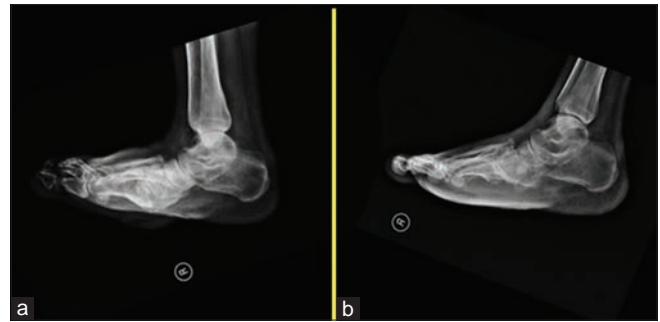

Figure 18: (a) Midfoot bony prominence in a foot with Stage 3 consolidated Charcot's arthropathy with a collapsed malunited Midfoot (b) after excision of the prominence

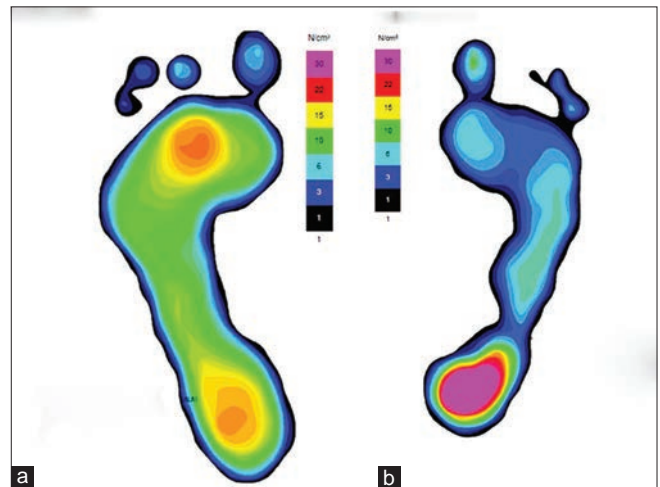


Figure 19: Pedobarograms of a patient with right-sided heel ulcer. (a) the pedobarogram of the normal left foot showing both forefoot and hindfoot loading. (b) the pedobarogram of the affected foot of the same patient showing abnormal hindfoot loading only with little or no forefoot loading

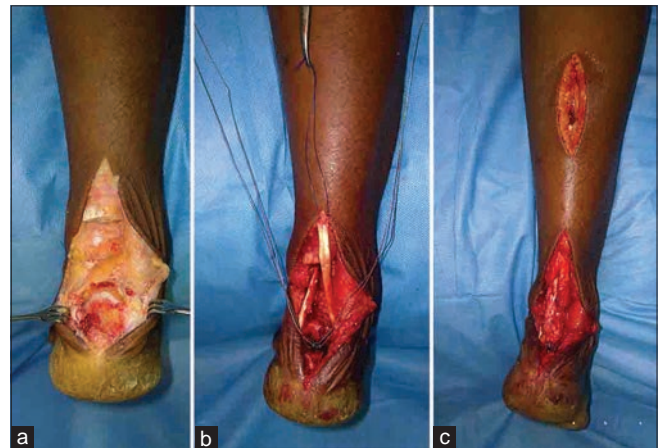


Figure 20: Tendoachilles repair by suture anchor with flexor hallucis longus augmentation. (a) Divided tendoachilles with a gap and no distal stump (b) flexor hallucis longus transferred through the calcaneum to provide a new insertion. (c) Repair completed with flexor hallucis longus weaved into the lengthened proximal tendoachilles stump

plastic surgical techniques. Recurrences can be avoided by taking good skin and nail care and correction of nail deformities.

RECONSTRUCTIVE SURGERY FOR GANGA CLASS 3 ULCERS (COMPLICATED DEEP ULCERS WITH SKIN AND SOFT-TISSUE LOSS)

This class of patients usually present with systemic signs of a complicated ulcer such as fever. They give a history of recent onset of foul-smelling discharge from the ulcer along with swelling, redness and warmth in the involved foot and an inability to walk on the affected foot.

The important initial step in the treatment of such patients is radical debridement of the affected area. Knowledge of the potential routes of spread of the infection along different planes is essential to ensure a good result. In our experience, a single exhaustive debridement is usually enough for infection control in 89% of patients, and multiple debridements are exceptions rather than the rule.

Once infection control and a clean bed have been achieved and blood sugar has been stabilised, the patient is taken up for wound cover as soon as possible.

The type of wound cover depends on the bed rather than their ability to provide a cushion for weightbearing. As long as the underlying biomechanical defect stands uncorrected, the type of wound cover would make little difference to the recurrence of the ulcer.

The reconstructive ladder is usually followed with regard to covering of the wound in the diabetic foot, and plenty of literature is available for the interested reader on the topic.^[52-54] We present a few situations in which we find the use of a free flap is greatly helpful in the salvage of complicated diabetic foot ulcers [Figures 21 and 22]. Once the wounds have healed, it is important that these patients are offered appropriate surgery for internal offloading to correct the pathomechanics which was responsible for the initial ulcer.

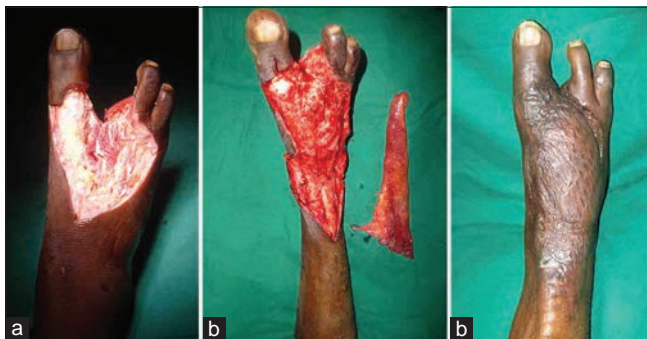


Figure 21: (a) Post-infective defect with loss of two central rays after debridement (b) with a gracilis free flap before inset (c) post-free flap cover

In the series of 188 consecutive patients with foot ulcers admitted for surgery during the period from January to September 2016, about 19.6% presented with a limb that has been affected beyond meaningful functional salvage or one that poses an imminent threat to life due to spreading sepsis (Ganga Class 4). A major limb amputation may be required in such patients either as a life-saving measure or to improve their quality of life. We try to preserve the knee joint as much as possible in these frail patients so as to reduce their energy expenditure during mobilisation. After recovery it is essential to provide these patients with access to good quality prostheses fitment and to encourage and provide them with supervised training on their use.

ROLE OF MULTIDISCIPLINARY APPROACH

Surgery forms only a part of the management of the patients with a diabetic foot ulcer. These patients need a holistic approach of a dedicated team which includes physicians, plastic surgeons, orthopaedic surgeons, anaesthesiologists, vascular surgeons and podiatrists. Patients with cardiac and renal problems will need specialised help to optimise their condition both before and after the surgery.

Anaesthesiologists skilled in regional blocks greatly contribute towards patient safety during surgery. Their versatility in various peripheral nerve blocks helps us undertake surgical procedures on moribund patients who pose a high risk for general or spinal anaesthesia.

Patients need to be offered supportive services such as customised footwear, skin and nail care for the prevention of recurrence of ulcers. Digital pedobarography plays an important role in both objective documentation of high-pressure areas and for designing of customised footwear for the post-surgical foot. An in-house footwear unit providing sleek and

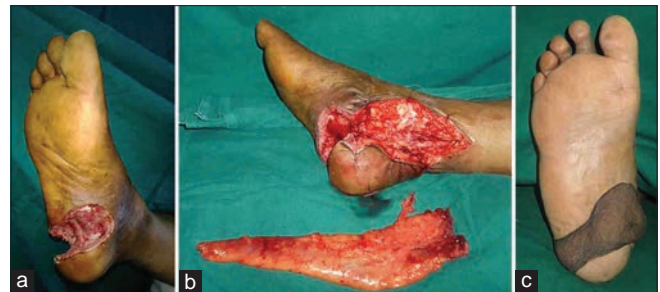


Figure 22: (a) Heel defect with extensive soft tissue loss after debridement (b) with a gracilis flap (c) well-settled free gracilis flap

well-designed footwear improves patient confidence in footwear, ensures compliance and maximises patient satisfaction, factors, which are very important in reducing the recurrence rate of ulcers.

CONCLUSION

Each time when we look at an ulcer we need to think as to what is the cause of the ulcer rather than just thinking of techniques to provide wound cover. Correcting the cause of the ulcer as early as possible will not only heal the ulcer and prevent its recurrence but will also go a long way in avoiding many needless amputations. Perhaps that objective would need the patient with diabetes to seek a surgeon's opinion the moment they form a callus.

Financial support and sponsorship

Nil.

Conflicts of interest

There are no conflicts of interest.

REFERENCES

- International Diabetes Federation. IDF Diabetes. 7ed. Brussels, Belgium: International Diabetes Federation; 2015. Available from: <http://www.diabetesatlas.org>. [Last cited on 2016 Apr 14].
- American Diabetes Association. Consensus Development Conference on Diabetic Foot Wound Care: 7-8 April 1999, Boston, Massachusetts. American Diabetes Association. *Diabetes Care* 1999;22:1354-60.
- Boulton AJ, Vileikyte L, Ragnarson-Tennvall G, Apelqvist J. The global burden of diabetic foot disease. *Lancet* 2005;366:1719-24.
- Trautner C, Haastert B, Giani G, Berger M. Incidence of lower limb amputations and diabetes. *Diabetes Care* 1996;19:1006-9.
- van Schie CH. A review of the biomechanics of the diabetic foot. *Int J Low Extrem Wounds* 2005;4:160-70.
- D'Ambrogio E, Giacomozzi C, Macellari V, Uccioli L. Abnormal foot function in diabetic patients: The altered onset of Windlass mechanism. *Diabet Med* 2005;22:1713-9.
- Viswanathan V, Kumpatla S. Pattern and causes of amputation in diabetic patients – A multicentric study from India. *J Assoc Physicians India* 2011;59:148-51.
- Pendsey SP. Understanding diabetic foot. *Int J Diabetes Dev Ctries* 2010;30:75-9.
- Viswanathan V, Snehalatha C, Sivagami M, Seena R, Ramachandran A. Association of limited joint mobility and high plantar pressure in diabetic foot ulceration in Asian Indians. *Diabetes Res Clin Pract* 2003;60:57-61.
- Fernando DJ, Masson EA, Veves A, Boulton AJ. Relationship of limited joint mobility to abnormal foot pressures and diabetic foot ulceration. *Diabetes Care* 1991;14:8-11.
- Young MJ, Cavanagh PR, Thomas G, Johnson MM, Murray H, Boulton AJ. The effect of callus removal on dynamic plantar foot pressures in diabetic patients. *Diabet Med* 1992;9:55-7.
- Rhim B, Harkless L. Prevention: Can we stop problems before they arise? *Semin Vasc Surg* 2012;25:122-8.
- Suresh K, Pradhan A. Approach to dysvascular diabetic foot. In: Pendsey S, editor. *Contemporary Management of the Diabetic Foot*. India: JP Medical Limited; 2013. p. 118-33.
- Adam DJ, Beard JD, Cleveland T, Bell J, Bradbury AW, Forbes JF, et al. Bypass versus angioplasty in severe ischaemia of the leg (BASIL): Multicentre, randomised controlled trial. *Lancet* 2005;366:1925-34.
- Moxey PW, Chong PF. Surgical revascularization of the diabetic foot. In: Shearman CP, editor. *Management of Diabetic Foot Complications*. London: Springer; 2015. p. 113-25.
- Armstrong DG, Lavery LA, Kimbriel HR, Nixon BP, Boulton AJ. Activity patterns of patients with diabetic foot ulceration: Patients with active ulceration may not adhere to a standard pressure off-loading regimen. *Diabetes Care* 2003;26:2595-7.
- Knowles EA, Boulton AJ. Do people with diabetes wear their prescribed footwear? *Diabet Med* 1996;13:1064-8.
- Ctercteko GC, Dhanendran M, Hutton WC, Le Quesne LP. Vertical forces acting on the feet of diabetic patients with neuropathic ulceration. *Br J Surg* 1981;68:608-14.
- Birke JA, Sims DS. Plantar sensory threshold in the ulcerative foot. *Lepr Rev* 1986;57:261-7.
- Boffeli TJ, Bean JK, Natwick JR. Biomechanical abnormalities and ulcers of the great toe in patients with diabetes. *J Foot Ankle Surg* 2002;41:359-64.
- Durrant B, Chockalingam N. Functional hallux limitus: A review. *J Am Podiatr Med Assoc* 2009;99:236-43.
- Gefen A, Megido-Ravid M, Azariah M, Itzhak Y, Arcan M. Integration of plantar soft tissue stiffness measurements in routine MRI of the diabetic foot. *Clin Biomech (Bristol, Avon)* 2001;16:921-5.
- Gefen A. Plantar soft tissue loading under the medial metatarsals in the standing diabetic foot. *Med Eng Phys* 2003;25:491-9.
- Pai S, Ledoux WR. The compressive mechanical properties of diabetic and non-diabetic plantar soft tissue. *J Biomech* 2010;43:1754-60.
- Kim JY, Hwang S, Lee Y. Selective plantar fascia release for non-healing diabetic plantar ulcerations. *J Bone Joint Surg Am* 2012;94:1297-302.
- Lin SS, Bono CM, Lee TH. Total contact casting and Keller arthroplasty for diabetic great toe ulceration under the interphalangeal joint. *Foot Ankle Int* 2000;21:588-93.
- Armstrong DG, Lavery LA, Vazquez JR, Short B, Kimbriel HR, Nixon BP, et al. Clinical efficacy of the first metatarsophalangeal joint arthroplasty as a curative procedure for hallux interphalangeal joint wounds in patients with diabetes. *Diabetes Care* 2003;26:3284-7.
- Tamir E, Vigler M, Avisar E, Finestone AS. Percutaneous tenotomy for the treatment of diabetic toe ulcers. *Foot Ankle Int* 2014;35:38-43.
- Rajbhandari SM, Sutton M, Davies C, Tesfaye S, Ward JD. 'Sausage toe': A reliable sign of underlying osteomyelitis. *Diabet Med* 2000;17:74-7.
- Taylor RG. The treatment of claw toes by multiple transfers of flexor into extensor tendons. *J Bone Joint Surg Br* 1951;33-B: 539-42.
- Barbari SG, Brevig K. Correction of clawtoes by the Girdlestone-Taylor flexor-extensor transfer procedure. *Foot Ankle* 1984;5:67-73.
- Albert S, Rinoie C. Effect of custom orthotics on plantar pressure distribution in the pronated diabetic foot. *J Foot Ankle Surg* 1994;33:598-604.
- Birke JA, Franks BD, Foto JG. First ray joint limitation, pressure, and ulceration of the first metatarsal head in diabetes mellitus. *Foot Ankle Int* 1995;16:277-84.
- Caselli A, Pham H, Giurini JM, Armstrong DG, Veves A. The forefoot-to-rearfoot plantar pressure ratio is increased in severe

- diabetic neuropathy and can predict foot ulceration. *Diabetes Care* 2002;25:1066-71.
35. Bus SA, Maas M, Cavanagh PR, Michels RP, Levi M. Plantar fat-pad displacement in neuropathic diabetic patients with toe deformity: A magnetic resonance imaging study. *Diabetes Care* 2004;27:2376-81.
 36. Mueller MJ, Sinacore DR, Hastings MK, Strube MJ, Johnson JE. Effect of achilles tendon lengthening on neuropathic plantar ulcers. A randomized clinical trial. *J Bone Joint Surg Am* 2003;85-A:1436-45.
 37. Laborde JM. Midfoot ulcers treated with gastrocnemius-soleus recession. *Foot Ankle Int* 2009;30:842-6.
 38. Dayer R, Assal M. Chronic diabetic ulcers under the first metatarsal head treated by staged tendon balancing: A prospective cohort study. *J Bone Joint Surg Br* 2009;91:487-93.
 39. Griffiths GD, Wieman TJ. Metatarsal head resection for diabetic foot ulcers. *Arch Surg* 1990;125:832-5.
 40. Patel VG, Wieman TJ. Effect of metatarsal head resection for diabetic foot ulcers on the dynamic plantar pressure distribution. *Am J Surg* 1994;167:297-301.
 41. Giurini JM, Habershaw GM, Chrzan JS. Panmetatarsal head resection in chronic neuropathic ulceration. *J Foot Surg* 1987;26:249-52.
 42. Lowery NJ, Woods JB, Armstrong DG, Wukich DK. Surgical management of Charcot neuroarthropathy of the foot and ankle: A systematic review. *Foot Ankle Int* 2012;33:113-21.
 43. Early JS, Hansen ST. Surgical reconstruction of the diabetic foot: A salvage approach for midfoot collapse. *Foot Ankle Int* 1996;17:325-30.
 44. Catanzariti AR, Mendicino R, Haverstock B. Osteotomy for diabetic neuroarthropathy involving the midfoot. *J Foot Ankle Surg* 2000;39:291-300.
 45. Chilvers M, Malicky ES, Anderson JG, Bohay DR, Manoli A 2nd. Heel overload associated with heel cord insufficiency. *Foot Ankle Int* 2007;28:687-9.
 46. Turco VJ, Spinella AJ. Achilles tendon ruptures – Peroneus brevis transfer. *Foot Ankle* 1987;7:253-9.
 47. Wapner KL, Pavlock GS, Hecht PJ, Naselli F, Walther R. Repair of chronic achilles tendon rupture with flexor hallucis longus tendon transfer. *Foot Ankle* 1993;14:443-9.
 48. Wilcox DK, Bohay DR, Anderson JG. Treatment of chronic achilles tendon disorders with flexor hallucis longus tendon transfer/augmentation. *Foot Ankle Int* 2000;21:1004-10.
 49. Pearce CJ, Sexton S, Gerrard D, Hatrick A, Solan M. Successful treatment of a chronically infected and necrotic tendo achilles in a diabetic with excision, flexor hallucis longus transfer and split-skin grafting. *J Bone Joint Surg Br* 2008;90:186-8.
 50. Wang CC, Lin LC, Hsu CK, Shen PH, Lien SB, Hwa SY, *et al*. Anatomic reconstruction of neglected achilles tendon rupture with autogenous peroneal longus tendon by endobutton fixation. *J Trauma* 2009;67:1109-12.
 51. Boyko EJ, Ahroni JH, Stensel V, Forsberg RC, Davignon DR, Smith DG. A prospective study of risk factors for diabetic foot ulcer. The seattle diabetic foot study. *Diabetes Care* 1999;22:1036-42.
 52. Hong JP. Reconstruction of the diabetic foot using the anterolateral thigh perforator flap. *Plast Reconstr Surg* 2006;117:1599-608.
 53. Kadam D. Microsurgical reconstruction of plantar ulcers of the insensate foot. *J Reconstr Microsurg* 2016;32:402-10.
 54. Attinger CE, Ducic I, Cooper P, Zelen CM. The role of intrinsic muscle flaps of the foot for bone coverage in foot and ankle defects in diabetic and nondiabetic patients. *Plast Reconstr Surg* 2002;110:1047-54.