

A novel technique for the management of microform cleft lip

Sir,

We are writing this letter to present you a novel technique for the management of microform cleft lip. As per the best of our knowledge, this technique has not been reported elsewhere in literature for the management of microform cleft lip.

As per Mulliken,^[1] the six features of the microform unilateral cleft lip are:

1. A notched mucosa
2. Thin medial vermilion
3. Elevated Cupid's bow peak
4. Furrowed philtral column
5. Hypoplastic orbicularis oris
6. Minor nasal deformity.

Since in majority of the cases, the tissue deficiency is not significant, the management appears deceptively simple. However, to completely correct the deformity, one needs to take down the lip completely followed by muscle advancement and resuturing.

In spite of this, the vermilion deficiency remains in some cases.

Our patient was a 30-year-old lady with a microform cleft and her main requirement was that she wanted bulk for her upper lip [Figure 1].

We present a simple technique to correct this problem by a primary vermilion V-Y advancement [Figure 2a and 2b] along with repairing the microform lip by Millard^[2] rotation advancement technique [Figure 3].

At 1-year and 9-month post-operative period, the patient had good bulk in her upper lip with an aesthetically pleasing result [Figure 4]. An advantage of this technique is that the deformity could be addressed in one sitting without the requirement of procedures such as derma-fat grafting which requires a separate incision.



Figure 1: Pre-operative image showing microform cleft

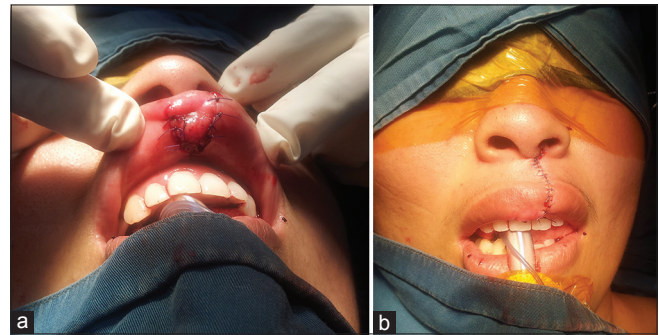


Figure 2: (a) Intra-operative image showing V-Y advancement. (b) Intra-operative image showing Millard's rotation advancement flap



Figure 3: Four-month post-operative period with good aesthetic result

To conclude, a primary vermilion V-Y advancement along with a Millard's rotation advancement can be used as a reliable technique in the management of microform clefts.




Figure 4: One year and nine-month follow-up with good aesthesis

This is an open access article distributed under the terms of the Creative Commons Attribution-NonCommercial-ShareAlike 3.0 License, which allows others to remix, tweak, and build upon the work non-commercially, as long as the author is credited and the new creations are licensed under the identical terms.

Access this article online	
Quick Response Code: 	Website: www.ijps.org
	DOI: 10.4103/0970-0358.197239

How to cite this article: Omkumar A, Sharma M. A novel technique for the management of microform cleft lip. *Indian J Plast Surg* 2016;49:426-7.

© 2016 Indian Journal of Plastic Surgery | Published by Wolters Kluwer - Medknow

Declaration of patient consent

The authors certify that they have obtained all appropriate patient consent forms. In the form the patient(s) has/ have given his/her/their consent for his/her/their images and other clinical information to be reported in the journal. The patients understand that their names and initials will not be published and due efforts will be made to conceal their identity, but anonymity cannot be guaranteed.

Financial support and sponsorship

Nil.

Conflicts of interest

There are no conflicts of interest.

Akshay Omkumar, Mohit Sharma

Department of Plastic and Reconstructive Surgery,
Amrita Institute of Medical Sciences,
Kochi,
Kerala, India

Address for correspondence:

Dr. Akshay Omkumar,
Department of Plastic and Reconstructive Surgery,
Amrita Institute of Medical Sciences,
Ponekkara, Kochi - 682 041,
Kerala, India.
E-mail: akshayomkumar@gmail.com

REFERENCES

1. Mulliken JB. Double unilimb Z-plastic repair of microform cleft lip. *Plast Reconstr Surg* 2005;116:1623-32.
2. Millard DR Jr. *Cleft Craft – The Evolution of Its Surgery the Unilateral Deformity*. Boston: Little Brown; 1976.