

Original Article

Gracilis muscle transposition as a workhorse flap for anal incontinence: Quality of life and functional outcome in adults

Guru Dayal Singh Kalra, Amit Kumar Sharma, Kaustubh Sharad Shende

Department of Burns and Plastic Surgery, SMS Hospital, Jaipur, Rajasthan, India

Address for correspondence: Dr. Amit Kumar Sharma, S/O Sitaram Sharma, Tiwari Sadan, Nehru Colony, Lalsot, Dausa, Rajasthan, India.
E-mail: dramits0708@gmail.com

ABSTRACT

Background/Purpose: Anal incontinence is one of the most psychologically and socially debilitating conditions in an otherwise healthy individual. It can lead to social isolation, loss of self-esteem, self-confidence and depression. This study is devoted to the problem of anal incontinence in the adult patients. The aim of our study is to analyse the results of gracilis muscle transposition for anal incontinence and improvement in quality of life (QOL) of patients. **Materials and Methods:** This was a retrospective study. A total of 18 patients with complaint of anal incontinence were enrolled in this study. All patients were treated with gracilis muscle transposition. **Results:** All patients are continent, and there is an improvement in their QOL. **Conclusion:** Gracilis muscle transposition is a good option for patients of anal incontinence who are not treated by non-surgical means.

KEY WORDS

Anal incontinence; gracilis sling; quality of life

INTRODUCTION

Anal incontinence is defined as the recurrent inability to voluntarily control the passage of bowel contents through the anal canal and to expel it at a socially acceptable location and time, occurring in individuals over the age of four years.^[1-6]

Anal incontinence is thought to be very common,^[1] but much underreported due to embarrassment. One study reported a prevalence of 2.2% in the general population.^[2]


It affects people of all ages but is more common in older adults (but it should not be considered a normal part of ageing). Females are more likely to develop it than males (63% of those with anal incontinence over thirty may be female).^[1]

Traditionally, anal incontinence was an insignificant complication of surgery, but it is now known that a variety of different procedures are associated with this possible complication, and sometimes at high levels. Examples are

This is an open access article distributed under the terms of the Creative Commons Attribution-NonCommercial-ShareAlike 3.0 License, which allows others to remix, tweak, and build upon the work non-commercially, as long as the author is credited and the new creations are licensed under the identical terms.

For reprints contact: reprints@medknow.com

How to cite this article: Kalra GD, Sharma AK, Shende KS. Gracilis muscle transposition as a workhorse flap for anal incontinence: Quality of life and functional outcome in adults. Indian J Plast Surg 2016;49:350-6.

| Access this article online | |
|---|----------------------------------|
| Quick Response Code:  | Website: www.ijps.org |
| | DOI: 10.4103/0970-0358.197245 |

midline internal sphincterotomy (8% risk), lateral internal sphincterotomy, fistulectomy, fistulotomy (18–52%), haemorrhoidectomy (33%), ileoanal reservoir operation, lower anterior resection, total abdominal colectomy, ureterosigmoidostomy^[7] and anal dilatation (Lord's procedure, 0–50%).^[8] Some authors consider obstetric trauma to be the most common cause.^[9]

With the widespread prevalence of anal incontinence and development of newer surgical techniques, the patient with severe anal incontinence is seldom obligated to a permanent stoma. Neosphincter procedures involving transposition of autologous muscle grafts play an important role for these patients.

MATERIALS AND METHODS

Demography

This was a retrospective study conducted in tertiary-level burns and plastic surgery centre over 2 years from 1st September 2013 to 31st August 2015. The study sample comprised 18 patients of anal incontinence: 15 patients were male and three were female. Of 15 male patients, eight had anal incontinence due to extensive perineal trauma by road traffic accident (RTA), four by blast injury and three by post-surgical (two patients had low anterior resection and one had fistulectomy). All three female patients had anal incontinence due to extensive perineal trauma following RTA. All trauma patients were treated in emergency department by diversion colostomy, and later on when stoma closure was done, these patients presented with anal incontinence. All post-surgical anal incontinence patients presented as late surgical complication of primary procedure. The age of patients was between 18 and 57 years.

We analysed the patients at three stages: Hospitalisation in the plastic surgery centre on admission, intraoperative, in post-operative period and in outdoor follow-up examination (in every 2 months).

The diagnosis was made with a thorough history including detailed questioning about symptoms, bowel habits, diet, medication and other medical problems. The physical examination was a standard part of any evaluation for faecal incontinence; digital rectal examination was performed to assess resting pressure and voluntary contraction (maximum squeeze) of the sphincter complex. As the provider was beginning the rectal examination, resistance was met at the anal

verge. If the examining finger met little resistance and the anus felt patulous, significant sphincter dysfunction was diagnosed. The patient was asked to tighten the sphincter around the examining finger to ascertain how much voluntary control was possible.

Limitations of study

We did not have anorectal manometry records of pressure exerted by the anal sphincters and puborectalis during rest and during contraction pre- and post-operatively.

We studied the adynamic myoplasty because the stimulator was not available.

Surgical technique

The operation was carried out in lithotomy position. After putting on the drapes, anus was cleaned out with povidone-iodine solution. [Figure 1] We chose single gracilis muscle used for the operation. It was used as an encircling anal sphincter. Through separate, short longitudinal incision in lower thigh, a suitable length of gracilis muscle is freed to allow for it to be withdrawn by its severed tendon into the perianal tunnel at the sides and back of the anorectum. [Figures 2 and 3] The dominant vascular pedicle, usually the terminal branch of medial circumflex femoral artery, enters the muscle belly approximately 8–10 cm inferior to pubic tubercle. The motor nerve to gracilis is anterior branch of obturator nerve which usually enters the muscle 2–3 cm superior to the point of entrance of vascular pedicle. After the muscle was threaded forward through the tunnel around the lateral and posterior aspect of anal canal, the muscle was wrapped around the anal canal, and then it was forcibly drawn forwards again to be reattached by nylon 1/0 stitches to periosteum of lower surface of ischial tuberosity or the inferior pubic ramus. [Figure 4 and 5] The thigh was adducted, and the muscle was drawn tight

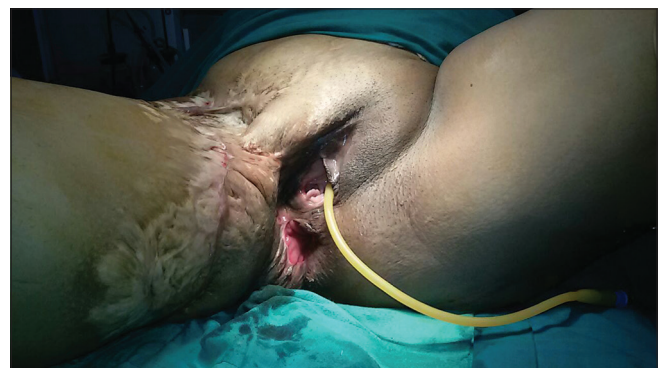

Figure 1: Pre-operative photograph showing incontinent anus

before it is attached. Because the muscle was pulled through under some tension, the anal canal was kept closed passively by a mechanical squeezing effect, as well as the usual voluntary contractile efforts. The muscle was found to be almost always long enough to wrap around the anus and be attached to the ischial tuberosity. During all the manoeuvres to bring the mobilised length of muscle through the wound and around the anal verge, care was taken to ensure that the muscle did not get twisted. Digital examination on the operation table after the sling had been completed confirmed that a finger could be inserted easily and had the sensation of being firmly gripped. Meticulous haemostasis was confirmed before wound closure. No drains were required. Skin closure was done with nylon 3/0 or with skin staplers [Figure 6 and 7].

Data collection and analysis

Modified faecal incontinence quality of life scale (FIQL) by Rockwood *et al.*^[10] was used to rate the patient's quality of life (QOL) and functional outcome in each patient. Four scales were based on the state and trait

characteristic or aspect of life that they were presumed to be measured. Original 29 questions were developed in the four scales. The exact question wording for each of the items in the four FIQL scales is presented in the following sections.

Basic four scales

1. Lifestyle - Question 10
2. Coping/behaviour - Question 9
3. Depression/self-perception - Question 7
4. Embarrassment - Question 3.

Faecal incontinence quality of life scale composition

Scale 1: Lifestyle

- Question 1: I cannot do many of things I want to do
- Question 2: I am afraid to go out
- Question 3: It is important to plan my schedule (daily activities) around my bowel pattern
- Question 4: I cut down on how much I eat before I go out

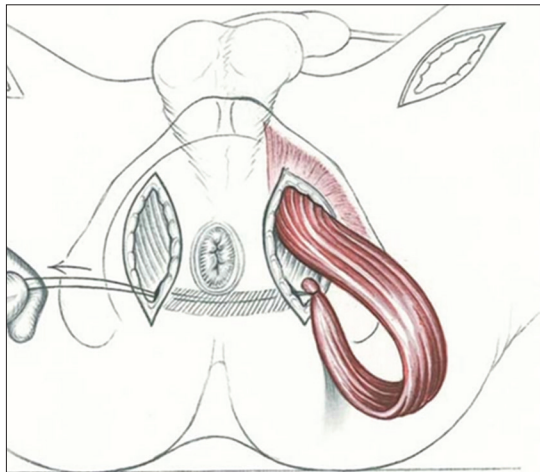


Figure 2: Line diagram showing gracilis harvest and transposition

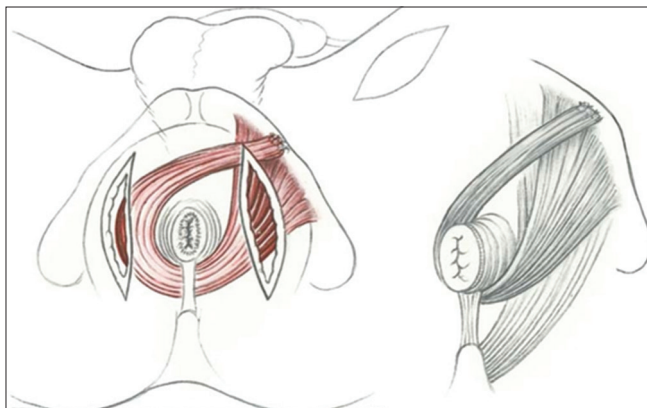


Figure 4: Line diagram showing gracilis muscle wrap around anal canal

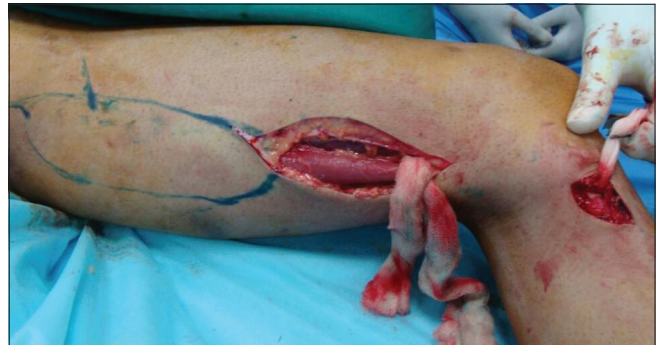

Figure 3: Intraoperative photograph showing gracilis muscle harvest

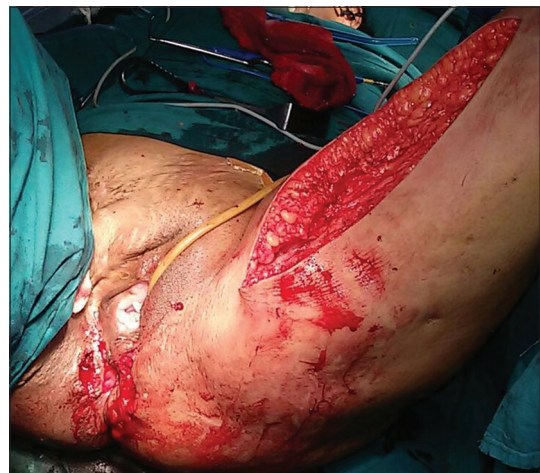

Figure 5: Intraoperative photograph showing gracilis muscle transposition and wrap around anal canal

- Question 5: It is difficult for me to get out and do things such as going to a movie or to a church
- Question 6: I avoid travelling by plane or train
- Question 7: I avoid travelling
- Question 8: I avoid visiting friends
- Question 9: I avoid going out to eat
- Question 10: I avoid staying overnight away from home.

Scale 2: Coping/behaviour

- Question 1: I had sex less often than I would like to
- Question 2: The possibility of bowel accidents is always on my mind
- Question 3: I feel I had no control over my bowels
- Question 4: Whenever I go someplace new, I specifically locate where the bathrooms are
- Question 5: I worry about not being able to get to the toilet in time
- Question 6: I worry about bowel accidents
- Question 7: I try to prevent bowel accidents by staying very near a bathroom
- Question 8: I cannot hold my bowel movement long enough to get to the bathroom
- Question 9: Whenever I am away from home, I try to stay near a restroom as much as possible.

Scale 3: Depression/self-perception

- Question 1: In general, would you say your health is not good
- Question 2: I am afraid to have sex
- Question 3: I feel different from other people
- Question 4: I enjoy life less
- Question 5: I feel like I am not a healthy person
- Question 6: I feel depressed
- Question 7: During the past month, had you felt so sad, discouraged, hopeless or had so many problems that you wondered if anything was worthwhile.

Scale 4: Embarrassment

- Question 1: I leak stool without even knowing it

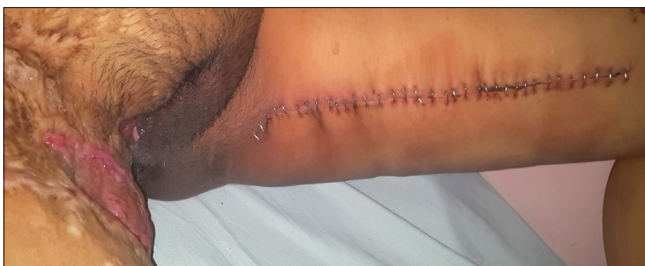

Figure 6: Well-healed donor site

- Question 2: I worry about others smelling stool on me
- Question 3: I feel ashamed.

Statistical analysis

Data were presented using descriptive statistics such as mean, standard deviation and percentage. The mean scores of pre-operative, post-operative – 6 months results were compared against each other using paired *t*-test. Differences between the genders and the various aetiologies of incontinence, with respect to pre- and post-operative scores, were analysed using Student’s *t*-test. Software used in the analysis was SPSS version 20 IBM, Chicago, IL, USA.

RESULTS

The mean pre-operative score and post-operative score with *P* < 0.0001 means improvement in score was highly significant [Table 1]. The mean pre-operative score and post-operative score in females with *P* = 0.008 means improvement in score was significant [Table 2]. The mean pre-operative score and post-operative score in males

Table 1: Overall changes in score

| All cases | Mean±SD | P |
|--|------------|--------|
| Lifestyle pre-operative FIQL | 7.50±0.86 | <0.001 |
| Lifestyle post-operative FIQL | 2.89±0.83 | |
| Coping/behaviour pre-operative FIQL | 7.33±0.77 | <0.001 |
| Coping/behaviour post-operative FIQL | 2.50±0.71 | |
| Depression/self-perception pre-operative FIQL | 5.94±0.80 | <0.001 |
| Depression/self-perception post-operative FIQL | 2.06±0.64 | |
| Embarrassment pre-operative FIQL | 1.89±0.68 | <0.001 |
| Embarrassment post-operative FIQL | 0.72±0.57 | |
| Total pre-operative FIQL | 22.67±1.81 | <0.001 |
| Total post-operative FIQL | 8.17±2.07 | |

SD: Standard deviation, FIQL: Faecal incontinence quality of life scale

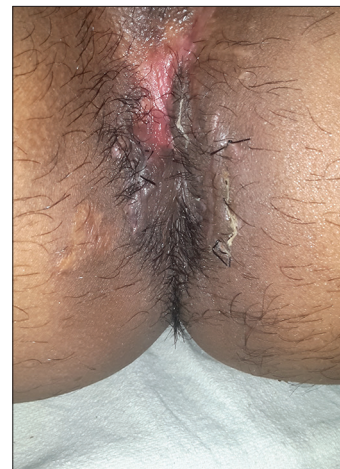

Figure 7: Post-operative photograph showing continent anal canal

with $P < 0.001$ means improvement in score was highly significant [Table 2].

The mean pre-operative score in RTA patients and post-operative score with $P < 0.0001$ means improvement in score was highly significant [Table 3]. The mean pre-operative score and post-operative score in blast injury patients with $P < 0.0001$ means improvement in score was highly significant [Table 3]. The mean pre-operative score and post-operative score post-surgery patients with $P = 0.001$ means improvement in score was significant [Table 3].

Comparing improvement in score between male and female patients, there was slightly more improvement in score male patients, but difference was statistically not significant [Table 4].

Comparing improvement in score according to aetiologies of incontinence, best improvement occurs in post-surgery patients then RTA patients and then blast injury patients, but this difference was statistically not significant [Table 5]. The most common complication in our study was hypertrophied scar at donor site in six patients followed

by perineal pain in three patients [Table 6]. Hypertrophied scars were not annoying to the patients and were managed conservatively. Perineal pain subsided gradually. Donor site thigh infection and gluteal wound infection were treated with proper antibiotics and daily dressings.

DISCUSSION

In the first half of the century, the gluteus maximus muscle was the most commonly used muscle in transpositions. Chetwood^[12] first described the operation in 1902 involving the gluteus maximus muscle and fascial slings to reinforce the sphincter muscles in children.

Gracilis muscle transposition was initiated by Pickrell et al.^[13] in 1952 to treat children with faecal incontinence due to neurologic and congenital anomalies. The technique involved wrapping the gracilis around the anus and attaching the free end to the contralateral ischial tuberosity. The basic concept was to create an anal encirclement repair similar to the Thiersch procedure using autologous tissue. Patients went through a period of training with exercises to learn to voluntarily contract and relax the muscle. The muscle contracted with abduction

Table 2: Changes in score in females and males

| Scales | Female | | Male | |
|--|------------|-------|------------|--------|
| | Mean±SD | P | Mean±SD | P |
| Lifestyle pre-operative FIQL | 7.00±1.00 | 0.063 | 7.60±0.83 | <0.001 |
| Lifestyle post-operative FIQL | 3.67±0.58 | | 2.73±0.80 | |
| Coping/behaviour pre-operative FIQL | 7.67±0.58 | 0.013 | 7.27±0.80 | <0.001 |
| Coping/behaviour post-operative FIQL | 2.67±0.58 | | 2.47±0.74 | |
| Depression/self-perception pre-operative FIQL | 6.33±0.58 | 0.020 | 5.87±0.83 | <0.001 |
| Depression/self-perception post-operative FIQL | 1.67±0.58 | | 2.13±0.64 | |
| Embarrassment pre-operative FIQL | 1.67±0.58 | 0.184 | 1.93±0.70 | <0.001 |
| Embarrassment post-operative FIQL | 1.00±0.00 | | 0.67±0.62 | |
| Total pre-operative FIQL | 22.67±1.53 | 0.008 | 22.67±1.91 | <0.001 |
| Total post-operative FIQL | 9.00±1.00 | | 8.00±2.20 | |

SD: Standard deviation, FIQL: Faecal incontinence quality of life scale

Table 3: Changes in score according to aetiology of incontinence

| Scales | RTA (n=11) | | Blast injury (n=4) | | Post-surgery (n=3) | |
|--|-------------|--------|--------------------|-------------------------|--------------------|---------------------|
| | Mean±SD | P | Mean±SD | P | Mean±SD | P |
| Lifestyle pre-operative FIQL | 7.45±1.036 | <0.001 | 7.75±0.500 | <0.001 | 7.33±0.577 | 0.004 |
| Lifestyle post-operative FIQL | 2.91±0.831 | | 3.50±0.577 | | 2.00±0.000 | |
| Coping/behaviour pre-operative FIQL | 7.36±0.674 | <0.001 | 7.75±0.957 | 0.001 | 6.67±0.577 | <0.001 |
| Coping/behaviour post-operative FIQL | 2.64±0.674 | | 2.75±0.500 | | 1.67±0.577 | |
| Depression/self-perception pre-operative FIQL | 6.18±0.603 | <0.001 | 6.00±0.816 | 0.001 | 5.00±1.000 | 0.035 |
| Depression/self-perception post-operative FIQL | 1.91±0.701 | | 2.50±0.577 | | 2.00±0.000 | |
| Embarrassment pre-operative FIQL | 2.00±0.632 | <0.001 | 2.25±0.500 | 0.092 (not significant) | 1.00±0.000 | Can't be calculated |
| Embarrassment post-operative FIQL | 0.73±0.467 | | 1.25±0.500 | | 0.00±0.000 | |
| Total pre-operative FIQL | 23.00±1.342 | <0.001 | 23.75±1.708 | <0.001 | 20.00±1.000 | 0.001 |
| Total post-operative FIQL | 8.18±1.834 | | 10.00±1.414 | | 5.67±0.577 | |

SD: Standard deviation, FIQL: Faecal incontinence quality of life scale, RTA: Road traffic accident

Table 4: Comparison in the improvement of score according to sex

| Sex | FIQL total | Number of cases | Mean total FIQL±SD | P |
|--------|----------------|-----------------|--------------------|--------|
| Male | Pre-operative | 15 | 22.67±1.91 | <0.001 |
| | Post-operative | 15 | 8.00±2.20 | |
| Female | Pre-operative | 3 | 22.67±1.53 | 0.008 |
| | Post-operative | 3 | 9.00±1.00 | |

SD: Standard deviation, FIQL: Faecal incontinence quality of life scale

Table 5: Comparison in the improvement of score according to aetiology of incontinence

| Mode of incontinence | FIQL total | Number of cases | Mean±SD | P |
|----------------------|----------------|-----------------|------------|--------|
| RTA | Pre-operative | 11 | 23.00±1.34 | <0.001 |
| | Post-operative | 11 | 8.18±1.83 | |
| Blast injury | Pre-operative | 4 | 23.75±1.71 | <0.001 |
| | Post-operative | 4 | 10.00±1.41 | |
| Post-surgery | Pre-operative | 3 | 20.00±1.00 | 0.001 |
| | Post-operative | 3 | 5.67±0.58 | |

SD: Standard deviation, FIQL: Faecal incontinence quality of life scale, RTA: Road traffic accident

Table 6: Complications

| Complications | Number of patients | Percentage |
|----------------------------------|--------------------|------------|
| Hypertrophied scar at donor site | 6 | 33.33 |
| Perineal pain | 3 | 16.66 |
| Gluteal wound infection | 2 | 11.11 |
| Donor site infection at thigh | 2 | 11.11 |
| Incontinence to liquid foods | 1 | 5.55 |

of the thigh and was made to relax by assuming the squatting position to avoid abduction of the leg.

Graciloplasty continues to be performed in the United States to replace sphincter muscle loss and as an adjunct to the artificial bowel sphincter.^[14-17] Vascularity of the tendinous part was doubtful because gracilis is a Type II muscle. This coupled with wrapping and stretch will leave a devascularised tendinous end. This problem was solved by the first five post-operative days. Patient is advised to take soft diet and to avoid thigh abduction so as to prevent excessive stretching of transposed gracilis tendon. Progressively tendon will also take vascularity from surrounding soft tissue. In some studies, it was suggested that the muscle does not seem to act as a dynamic sphincter but does offer passive resistance to outflow and the muscle acts as no more than an inert sling.^[11,18]

According to Mowatt *et al.*,^[19] on sacral nerve stimulation, there is modulation of nerves and muscles of pelvic floor and hindgut but there is limited evidence that there is an improvement in continence. In recent studies, artificial sphincters were placed around the anal canal and lower rectum but they have their own complications.^[20] SECCA

device delivers temperature control radiofrequency energy to the anorectal junction to treat faecal incontinence, and its early results were satisfactory but mucosal ulceration was a complication.^[21]

The goal of our study was to analyse the results of gracilis muscle transposition for anal incontinence and improvement in QOL of patients.

Judging the QOL of anal incontinent patients is difficult; hence, it has prompted various researchers to formulate various scoring systems. However, these grading systems are quite complicated. In this study, we used a modified FIQL by Rockwood *et al.*^[10]

Corman^[22] reported on 14 patients followed for at least 5 years, 11 of whom had excellent or fair results. He attributed his success to appropriate patient selection including only relatively young, motivated patients without functional colonic dysmotility and with disabling incontinence secondary to trauma or congenital anomaly. Sielezneff *et al.*^[23] were successful with 8 patients, all of whom improved using the original procedure described by Pickrell combined with post-operative biofeedback. Eccersley *et al.*^[24] reported that two-thirds of patients had improvement in continence with half of the patients experiencing good function. They concluded that these results were comparable to the results of their stimulated counterparts. In our study, all patients are continent and there is an improvement in QOL of patients; hence, results are comparable with these studies, and better results occur in healthy young male patients with post-surgery aetiology. All the patients went through a period of training with exercises to learn to voluntarily contract and relax the muscle by forced adduction of thigh with neo anal sphincter tightness.

Currently, stimulated graciloplasty is the most studied and employed transposition procedure for faecal incontinence with most recent reports of success between 57% and 93%.^[14,15] In 1981, Salmon and Henriksson^[25] reported on the transformation of skeletal muscle from fast-twitch fatigue-prone (Type II) muscle fibres to slow-twitch fatigue-resistant (Type I) muscle fibres by application of low-frequency electrical stimulation. However, the main concern arises about the high rates of complications, need for reoperation and higher cost. In the original study by the Dynamic Graciloplasty Therapy Study Group,^[14] the complication and re-operative rates were 74% and 40%, respectively. Other studies also revealed high rates of infection, hardware failure and post-operative evacuatory dysfunction.

Hence, focus shifted back to its static counterpart with modifications of the original technique to improve outcome.

The adynamic myoplasty remains an effective option in healthcare settings where the stimulator is not available. With improved techniques and increasing experience, the graciloplasty is playing an increasing role in the initial approach to anal incontinence. Still important, fundamental research must be performed to improve the outcome for myoplasties and their application for faecal incontinence. Future efforts should be directed towards optimising patient selection, surgeon training and surgical techniques to minimise morbidity and maximise satisfactory outcome.

CONCLUSION

Although the gracilis muscle transposition for anal incontinence is not a new technique, we can make the patients continent with better results and improvement in their QOL with this technique. On evaluation of results, all patients are continent and significant improvement in mean QOL score of the study population was noted. No individual centre has gleaned enough experience with the various techniques; therefore, significant shortcomings exist because of this non-randomised approach. Consensus and standardisation are needed with respect to data collection, scoring systems and QOL assessment. Centres of expertise need to develop additional novel surgical techniques.

Acknowledgement

This study was supported by all academic persons of various departments of SMS Hospital Jaipur, Rajasthan, India. We would like to thank our colleagues who provided insight and expertise that greatly assisted the study. We would also like to show our gratitude to the patients for showing faith in us.

Financial support and sponsorship

Nil.

Conflicts of interest

There are no conflicts of interest.

REFERENCES

1. Kaiser AM. ASCRS core subjects: Fecal incontinence. Annual Meeting: ASCRS; 2012.
2. Wolff BG. The ASCRS Textbook of Colon and Rectal Surgery. New York: Springer; 2007. p. 653-64.
3. Yamada T, Alpers DH. Textbook of Gastroenterology. Vol. 5. Chichester, West Sussex: Blackwell Publishing; 2009. p. 1717-44.
4. Norton C, Thomas L, Hill J, Guideline Development G. Management of faecal incontinence in adults: Summary of NICE guidance. *BMJ* 2007;334:1370-1.
5. Abrams P. Pathophysiology of urinary incontinence, faecal incontinence and pelvic organ prolapse. *Incontinence: 4th International Consultation on Incontinence. Vol. 4.* Paris: Paris Health Publications; 2009. p. 255.
6. Zbar AP, Wexner SD, editors. *Coloproctology.* New York: Springer; 2010. p. 109-19.
7. Abrams P. Epidemiology of urinary (UI) and faecal (FI) incontinence and pelvic organ prolapse (POP). *Incontinence: 4th International Consultation on Incontinence. Vol. 4.* Paris: Paris Health Publications; 2009. p. 35.
8. Ommer A, Wenger FA, Rolfs T, Walz MK. Continence disorders after anal surgery – a relevant problem? *Int J Colorectal Dis* 2008;23:1023-31.
9. Rieger N, Wattochow D. The effect of vaginal delivery on anal function. *Aust N Z J Surg* 1999;69:172-7.
10. Rockwood TH, Church JM, Fleshman JW, Kane RL, Mavrantonis C, Thorson AG, *et al.* Fecal incontinence quality of life scale: Quality of life instrument for patients with fecal incontinence. *Dis Colon Rectum* 2000;43:9-16.
11. Sangwan YP, Collier JA. Fecal incontinence. *Surg Clin North Am* 1994;74:1377-98.
12. Chetwood CH. Plastic operation of the sphincter ani with report of a case. *Med Rec* 1902;61:529.
13. Pickrell KL, Broadbent TR, Masters FW, Metzger JT. Construction of a rectal sphincter and restoration of anal continence by transplanting the gracilis muscle; a report of four cases in children. *Ann Surg* 1952;135:853-62.
14. Mander BJ, Wexner SD, Williams NS, Bartolo DC, Lubowski DZ, Oresland T, *et al.* Preliminary results of a multicentre trial of the electrically stimulated gracilis neoanal sphincter. *Br J Surg* 1999;86:1543-8.
15. Wexner SD, Baeten C, Bailey R, Bakka A, Belin B, Belliveau P, *et al.* Long-term efficacy of dynamic graciloplasty for fecal incontinence. *Dis Colon Rectum* 2002;45:809-18.
16. Wexner SD, Gonzalez-Padron A, Rius J, Teoh TA, Cheong DM, Nogueras JJ, *et al.* Stimulated gracilis neosphincter operation. Initial experience, pitfalls, and complications. *Dis Colon Rectum* 1996;39:957-64.
17. Matzel KE, Madoff RD, LaFontaine LJ, Baeten CG, Buie WD, Christiansen J, *et al.* Complications of dynamic graciloplasty: Incidence, management, and impact on outcome. *Dis Colon Rectum* 2001;44:1427-35.
18. Yoshioka K, Keighley MR. Clinical and manometric assessment of gracilis muscle transplant for fecal incontinence. *Dis Colon Rectum* 1988;31:767-9.
19. Mowatt G, Glazener C, Jarrett M. Sacral nerve stimulation for fecal incontinence and constipation in adults: A short version Cochrane review. *Neurourological Urodyn* 2008;27:155-61.
20. Schrag HJ, Ruthmann O, Doll A, Goldschmidtboeing F, Woias P, Hopt UT. Development of a novel, remote-controlled artificial bowel sphincter through microsystems technology. *Artif Organs* 2006;30:855-62.
21. Parisien CJ, Corman ML. The Secca procedure for the treatment of fecal incontinence: Definitive therapy or short-term solution. *Clin Colon Rectal Surg* 2005;18:42-5.
22. Corman M. Gracilis muscle transposition for anal incontinence: Late results. *Br J Surg* 1985;72(Suppl):S21-S22
23. Sieleznoff I, Bauer S, Bulgare JC, Sarles JC. Gracilis muscle transposition in the treatment of faecal incontinence. *Int J Colorectal Dis* 1996;11:15-8.
24. Eccersley AJ, Lunniss PJ, Williams NS. Unstimulated graciloplasty in traumatic faecal incontinence. *Br J Surg* 1999;86:1071-2.
25. Salmons S, Henriksson J. The adaptive response of skeletal muscle to increased use. *Muscle Nerve* 1981;4:94-105.