

Case Report

Complex dorsal dislocation of the distal interphalangeal joint: Perspectives on management

Ajeesh Sankaran, R. Ravindra Bharathi, S. Raja Sabapathy

Department of Plastic, Hand, Microsurgery and Burns, Ganga Hospital, Coimbatore, Tamil Nadu, India

Address for correspondence: Dr. Ajeesh Sankaran, Ganga Hospital, 313, Mettupalayam Road, Coimbatore - 641043, Tamil Nadu, India.
E-mail: ajaxsankaran@gmail.com

ABSTRACT

Distal interphalangeal joint dislocations are only rarely complex and irreducible. We present a case and illustrate our approach to management of this problem. Open reduction is necessary, and preferred approach is volar. It is imperative to identify the injured soft tissue and repair them as is feasible.

KEY WORDS

Complex dislocation; distal interphalangeal joint; volar plate repair

INTRODUCTION

Dislocations of the distal interphalangeal (DIP) joint are usually associated with fractures of its base. Dorsal irreducible dislocation of this joint is an especially rare injury, with less than twenty cases reported in English literature since 1940. The injury is the distal counterpart of the complex metacarpophalangeal (MCP) dislocation, with many parallels. However, this is liable to be missed and mismanaged unless a high index of suspicion is maintained, especially in a multiply injured patient.

We present a case report with a brief review of the literature and pointers towards managing this problem.

CASE REPORT

A 46-year-old right-handed farmer sustained a motor vehicle accident, resulting in bilateral distal radius fractures

and a closed dorsal dislocation of the DIP joint of the left middle finger. X-rays showed an increased joint space, along with a dorsoulnar dislocation [Figure 1a and b]. This suggested soft-tissue interposition, possibly the volar plate of the DIP joint. A similar sign is well recognised for the MCP joint dorsal dislocation.^[1] Closed pinning of the ipsilateral distal radius fracture was performed under a brachial plexus block, before proceeding to reduction of the finger joint. Closed reduction was attempted by exaggerating the hyperextension and ulnar deviation deformity, followed by gentle pressure over the dorsally palpable base of the distal phalanx. Excess traction was avoided to not worsen any possible interposition.

Open reduction was planned after a couple of trials of closed reduction failed. Under an arm tourniquet control, a volar zig-zag incision was made centred on the flexion crease of the DIP joint. On exposure of the joint, the ulnar condyle of

Access this article online	
Quick Response Code: 	Website: www.ijps.org
	DOI: 10.4103/0970-0358.197251

This is an open access article distributed under the terms of the Creative Commons Attribution-NonCommercial-ShareAlike 3.0 License, which allows others to remix, tweak, and build upon the work non-commercially, as long as the author is credited and the new creations are licensed under the identical terms.

For reprints contact: reprints@medknow.com

How to cite this article: Sankaran A, Bharathi RR, Sabapathy SR. Complex dorsal dislocation of the distal interphalangeal joint: Perspectives on management. *Indian J Plast Surg* 2016;49:403-5.

the head of the middle phalanx was found prominent volarly with the flexor digitorum profundus tendon entrapped behind it, with rupture of the A5 pulley. The volar plate was found interposed between the articular surfaces [Figure 2]. The volar plate was pulled out and reduction completed by manoeuvring the flexor tendon around the middle phalanx head [Figure 3]. Concentric reduction was confirmed under image intensifier [Figure 4]. As the volar plate was avulsed proximally, it was then repaired to the periosteum over the middle phalanx with nonabsorbable sutures (5-0 Prolene). The joint was found to be stable through a full passive range of motion. A bulky dressing was applied after skin closure. No separate fixation or immobilisation was applied. A follow-up X-ray at 2 months showed maintenance of reduction [Figure 5]. Clinically, he had no extension lag with terminal restriction of DIP flexion.

DISCUSSION

The first report of an irreducible DIP dislocation was by Selig and Schein in 1940,^[2] who ascribed the irreducibility to buttonholing of the middle phalanx head through the

volar plate. Over the years, various reports have identified more causes, which are: profundus tendon entrapment behind middle phalanx head, volar plate interposition and buttonholing of the middle phalanx head through a rent in the volar plate or flexor tendon.^[3] In the thumb, interphalangeal joint dislocation irreducibility has also been attributed to sesamoid bone interposition.^[4] These injuries have a high incidence of being missed initially as well as late presentation.^[5] Moreover, excessive traction may actually convert a simple dislocation into a complex one, by pulling the avulsed volar plate into the joint space. Once increased joint space is noted on X-rays, closed reduction is to be attempted only by pressure on the distal phalanx base. Repeated attempts are unlikely to be successful.

In a report and review of literature, Abouzahr and Poblete^[6] found only 12 such cases reported till 1997 having included both open and closed dislocations. They

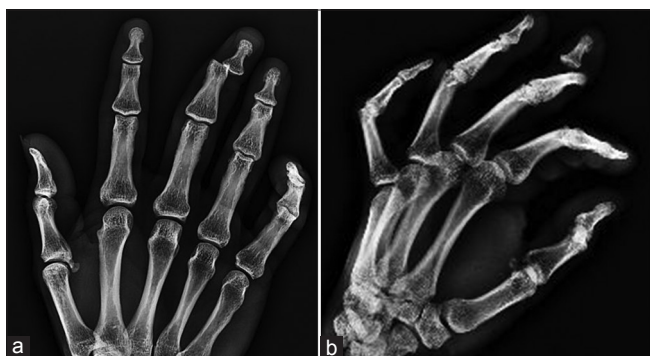

Figure 1: (a and b) X-ray views showing dorsoulnar distal interphalangeal joint dislocation with increased joint space

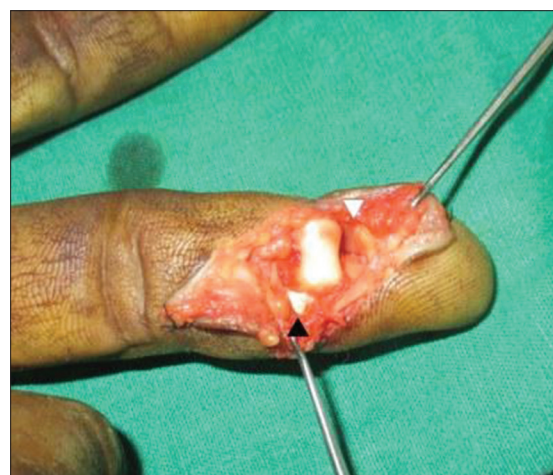


Figure 2: Intraoperative picture showing prominent middle phalanx head. Note volar plate interposition (white arrow) and displaced profundus tendon (black arrow)

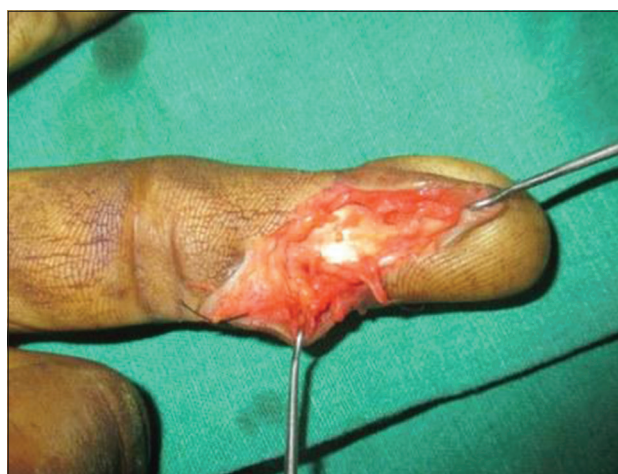

Figure 3: Intraoperative picture post-reduction with centralised profundus tendon

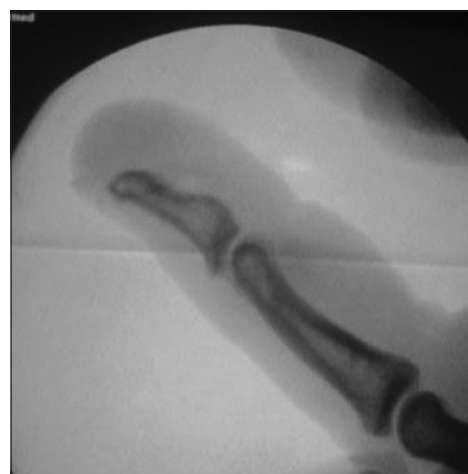

Figure 4: Concentric reduction of the joint on lateral view with image intensifier

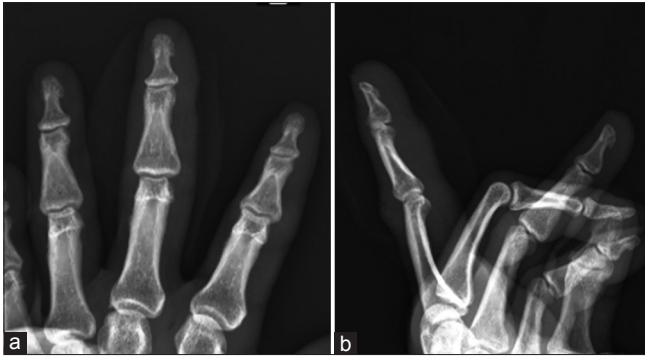

Figure 5: (a and b) Follow-up X-ray showing concentric reduction

concluded that volar plate interposition was the culprit in closed injuries while the buttonholed profundus tendon caused irreducibility in open injuries. This has been later contested by Banerji *et al.* in their report.^[7] We also feel that, in our case, the displacement of the tendon was the primary impediment to reduction rather than the volar plate interposition. However, this interposition has to be identified and corrected before any attempt at joint reduction is made. Otherwise, it may become impossible to repair this structure post-reduction.

Similar to the controversy over the MCP dislocation, controversy exists in the approach for open reduction. The dorsal transverse approach, with midlateral extensions, is oft cited. The approach allows easy handling of the interposed tissues but is fraught with wound healing issues.^[4] The volar approach, on the other hand, heals well, but with some involved dissection needed to safely extricate the trapped tissues. It also allows repair of the volar plate or tendon, which ensures stability. On the basis of our experience with MCP and proximal interphalangeal joint dislocations, we chose the volar approach.

K-wire fixation is not necessary if the joint is stable after open reduction. If reduction is unstable, it is worthwhile searching for the soft-tissue components involved and repairing the injured structures. These could be the volar plate, flexor tendon, capsule and/or collateral ligaments. For proper delineation of the injury and subsequent repair, loupe magnification is highly recommended.

In a stable reduction, no further immobilisation is preferred. Active movements can immediately be started. We instructed the patient to use the finger within limits of pain while avoiding strong gripping activities for 3 weeks. However, it is better to safeguard the reduction with a splint if any doubt on the stability of the reduction or patient's compliance exists.

CONCLUSION

The dorsal DIP dislocation is an easily missed injury and even more easily mismanaged. Diagnosis requires a high index of suspicion, and X-rays should definitely be obtained. If an increase in joint space is noted, open reduction will usually be necessary. A volar approach allows proper repair of the injured tissues.

Financial support and sponsorship

Nil.

Conflicts of interest

There are no conflicts of interest.

REFERENCES

1. Merrell G, Slade JF. Dislocations and ligament injuries in the digits. In: Wolfe SW, Hotchkiss RN, Pederson WC, Kozin SH, editors. Green's Operative Hand Surgery. 6th ed. Philadelphia: Churchill Livingstone; 2011.
2. Selig S, Schein A. Irreducible buttonhole dislocations of the fingers. *J Bone Joint Surg Am* 1940;22:436-41.
3. Ghobadi F, Anapolle DM. Irreducible distal interphalangeal joint dislocation of the finger: A new cause. *J Hand Surg Am* 1994;19:196-8.
4. Sabapathy SR, Bose VC, Rex C. Irreducible dislocation of the interphalangeal joint of the thumb due to sesamoid bone interposition: A case report. *J Hand Surg Am* 1995;20:487-9.
5. Henry MH. Hand fractures and dislocations. In: Court-Brown CM, Heckman JD, McQueen MM, Ricci WM, Tornetta P, editors. Rockwood and Green's Fractures in Adults. 8th ed. Philadelphia: Wolters Kluwer; 2015.
6. Abouzahr MK, Poblete JV. Irreducible dorsal dislocation of the distal interphalangeal joint: Case report and literature review. *J Trauma* 1997;42:743-5.
7. Banerji S, Bullocks J, Cole P, Hollier L. Irreducible distal interphalangeal joint dislocation: A case report and literature review. *Ann Plast Surg* 2007;58:683-5.