

Transrectal ultrasound-guided aspiration in the management of prostatic abscess: A single-center experience

Jigish B Vyas, Sanika A Ganpule¹, Arvind P Ganpule, Ravindra B Sabnis, Mahesh R Desai

Departments of Urology, and ¹Radiology, Muljibhai Patel Urological Hospital, Nadiad, Gujarat, India

Correspondence: Dr. Ravindra B Sabnis, Department of Urology Muljibhai Patel Urological Hospital. Dr. Virendra Desai Road, Nadiad, Gujarat - 387 001, India. E-mail: rbsabnis@gmail.com

Abstract

Objectives: The safety and efficacy of transrectal ultrasound (TRUS) guided aspiration of prostatic abscess (PA) is known. The objective of this study is to describe a treatment algorithm for management of PA with TRUS-guided aspiration, emphasizing on indications and factors predicting the treatment outcome. **Materials and Methods:** After the institutional review board approval was obtained, a retrospective study was done of all patients suspected with PA on digital rectal examination (DRE) and confirmed on TRUS. An 18-gauge two-part needle was used for aspiration. The real-time TRUS-guided aspiration of PA was done in the longitudinal axis. The aspiration of pus and the sequential collapse of cavity was seen “real time.” A suprapubic catheter was placed, if the patient had urinary retention, persistent dysuria, and/or severe lower urinary tract symptoms (LUTS). Success was defined as complete resolution of the abscess and/or symptoms. **Results:** Forty-eight patients were studied with PA, with a mean age of 54.6 ± 14.6 (range 26-79) years. The DRE diagnosed PA in 22 (45.83%) patients, while abdominal sonography diagnosed PA in 13 (27.08%) patients. TRUS revealed a hypoechoic area with internal echoes in all 48 (100%) patients. The diagnosis was confirmed in all 48 cases with aspiration. The mean size of the lesion was 3.2 ± 1.2 (range 1.5-8) cm. Mean volume aspirated was 10.2 ml (range 2.5-30 ml). Complete resolution after first aspiration was observed in 20 (41.66%) patients. An average of 4.1 (range 1-7) aspirations was required for complete resolution which was seen in 41 patients (85.42%). Seven (14.58%) patients required transurethral resection (deroofting) of the abscess cavity. We formulated a treatment algorithm based on the above findings. **Conclusion:** The proposed algorithm based on our experience suggests that patients with PA larger than 2 cm with severe LUTS and/or leukocytosis benefit from TRUS-guided aspiration. In addition, these patients are benefitted from urinary drainage (either perurethral or suprapubic). The algorithm also suggests that if two attempts of TRUS aspiration fail, these patients benefit from transurethral drainage.

Key words: LUTS; prostatic abscess; prostate imaging; TRUS

Introduction

Prostatic abscess (PA) is a rare clinical entity. The sequelae of PA are spontaneous rupture of abscess into the urethra,

perineum, bladder, or rectum, chronic prostatitis, etc. A variety of organisms are responsible for its causation, which include gram-negative bacilli such as *Escherichia coli* and staphylococci.^[1] There are also reports of PA resulting from anerobic and fungal infection,^[2] particularly in immunocompromised patients. Clinically, PA presents with non-specific symptoms, and the diagnosis is based on digital rectal examination (DRE) and subsequent imaging.^[3] Transrectal ultrasound (TRUS) is considered to be a sensitive tool from a diagnostic and therapeutic standpoint. The variety of therapeutic options available for managing PA include drainage either using the transrectal, transurethral, or transperineal route under TRUS guidance.

Access this article online

Quick Response Code:



Website:
www.ijri.org

DOI:
10.4103/0971-3026.120262

We report our experience in managing PA with TRUS-guided aspiration as a tool for diagnosis, treatment, and follow-up. We propose an algorithm for diagnostic and therapeutic management of these patients. We focus on the indications and treatment outcomes with TRUS-guided aspiration of PA.

Materials and Methods

A retrospective analysis of data of all PA patients seen at our center between January 2000 and January 2008 was done after obtaining approval from the institutional review board (IRB). The inclusion criteria for analysis were patients with PA on DRE confirmed on TRUS and subsequently treated with TRUS-guided aspiration. The patients who did not consent or did not follow-up were excluded from the analysis. All patients underwent a thorough physical examination, DRE, and an abdominal USG prior to TRUS. In all patients, PA was suspected clinically (suggested by tenderness and bogginess on DRE) and/or on transabdominal USG, which was further confirmed by TRUS-guided aspiration. Baseline investigations prior to aspiration included a hemogram and prothrombin time (PT) to rule out any bleeding disorder. The clinical findings were correlated with TRUS findings to decide the accuracy.

An informed consent was taken, in which was mentioned the possible complications that may be encountered including bleeding and sepsis. All TRUS aspirations done during the specified period were included for analysis. All patients had consented for using the data for publication. The procedure was performed by a urologist under the guidance of a radiologist years of experience. Preoperatively, all the patients received cephalosporin (cefotaxime 100 mg/kg/dose/day) and an aminoglycoside (Inj. Amikacin 15 mg/kg/dose/single dose) just prior to the procedure. Post-procedure, antibiotics were continued for 3 days. We did not use any periprostatic block for analgesia. The patient received an enema prior to the procedure.

The TRUS (BK Medical, Herley, Denmark 7.5 MHz probe)-guided aspiration was done in the left lateral decubitus position after obtaining an informed consent. A multi-frequency biplanar 7.5 MHz probe was used [Figure 1]. The scan was done in longitudinal and transverse sections; the prostate size was measured using the ellipsoid formula. Adequate lubrication was obtained with an anesthetic jelly. The size, shape, and location of the PA (hypoechoic) were noted [Figure 2]. PA was differentiated from malignancy depending on the location of the lesion, the presence/absence of beak sign, and the absence of invasion of the "white line." The findings were also correlated with the clinical findings.

The volume of the abscess was measured by calculating

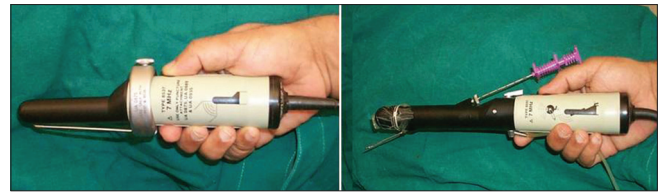

Figure 1: TRUS (BK Medical, Denmark 7.5 MHz probe) guided aspiration was done in the left lateral decubitus position

the longest transverse, longitudinal, and anteroposterior diameter. An 18-gauge two-part needle was used for aspiration. A real-time TRUS-guided aspiration of PA was done in the longitudinal axis. The trajectory of the needle was ascertained using the electronic dotted line inbuilt in the probe. The needle was seen traversing the trajectory and entering the abscess cavity. The aspiration of pus was done manually [Figure 2] and the sequential collapse of the abscess cavity was seen "real time." The aspirated fluid was analyzed for culture, fungus, and acid-fast bacilli (AFB) staining. A suprapubic catheter was placed, if the patient had urinary retention, persistent dysuria, and/or severe lower urinary tract symptoms (LUTS). The post-procedure analgesia regime was tramadol based. The patients were reassessed after 72 h with TRUS. Repeat aspiration was done if a residual collection was seen on follow-up TRUS [Figures 2 and 3]. If the patient had recurrent collection, he was considered for transurethral (TUR) derroofing. Success was defined as resolution of the symptoms and/no residual abscess. Statistical analysis was done by a biomedical statistician.

Results

Forty-eight patients were studied with PA, with a mean age of 54.6 ± 14.6 (range 26-79 years). The body mass index (BMI) was $25.6 \pm \text{Kg/M}^2$ (21.4-28.4). Twenty patients were diabetic (41.66%), three had chronic renal failure (6.25%), and two were on immunosuppressants (4.1%). DRE diagnosed PA in 22 (45.83%) patients, while abdominal USG diagnosed PA in 13 (27.08%) patients. The presentation was as follows: fever [20 (41.6%)], obstructive LUTS [17 (35.4%)], irritative LUTS [28 (58.3%)], acute urinary retention [12 (25%)], and testicular pain [3 (6.5%)]. TRUS revealed a hypoechoic area with or without internal echoes in all 48 (100%) patients. The distribution of the lesions was as follows: right lobe [18 (37.5%)], left lobe [15 (31.2%)], and bilateral [15 (31.2%)]. The mean size of the lesion in maximum dimension was 3.2 ± 1.2 (range 1.5-8) cm. Mean volume aspirated was 10.2 ml (range 2.5-30 ml). The aspirated pus showed a positive culture in 18 patients as follows: *E. coli* ($n = 9$), *Klebsiella* ($n = 6$), *Pseudomonas* ($n = 2$), and *Proteus* ($n = 1$). Complete resolution after first aspiration was observed in 20 (41.66%) patients. An average of 4.1 (range 1-7) aspirations was required, with complete resolution seen in 41 patients (85.42%). The complications observed were fever ($n = 6$; 12.5%) and hematuria ($n = 7$;

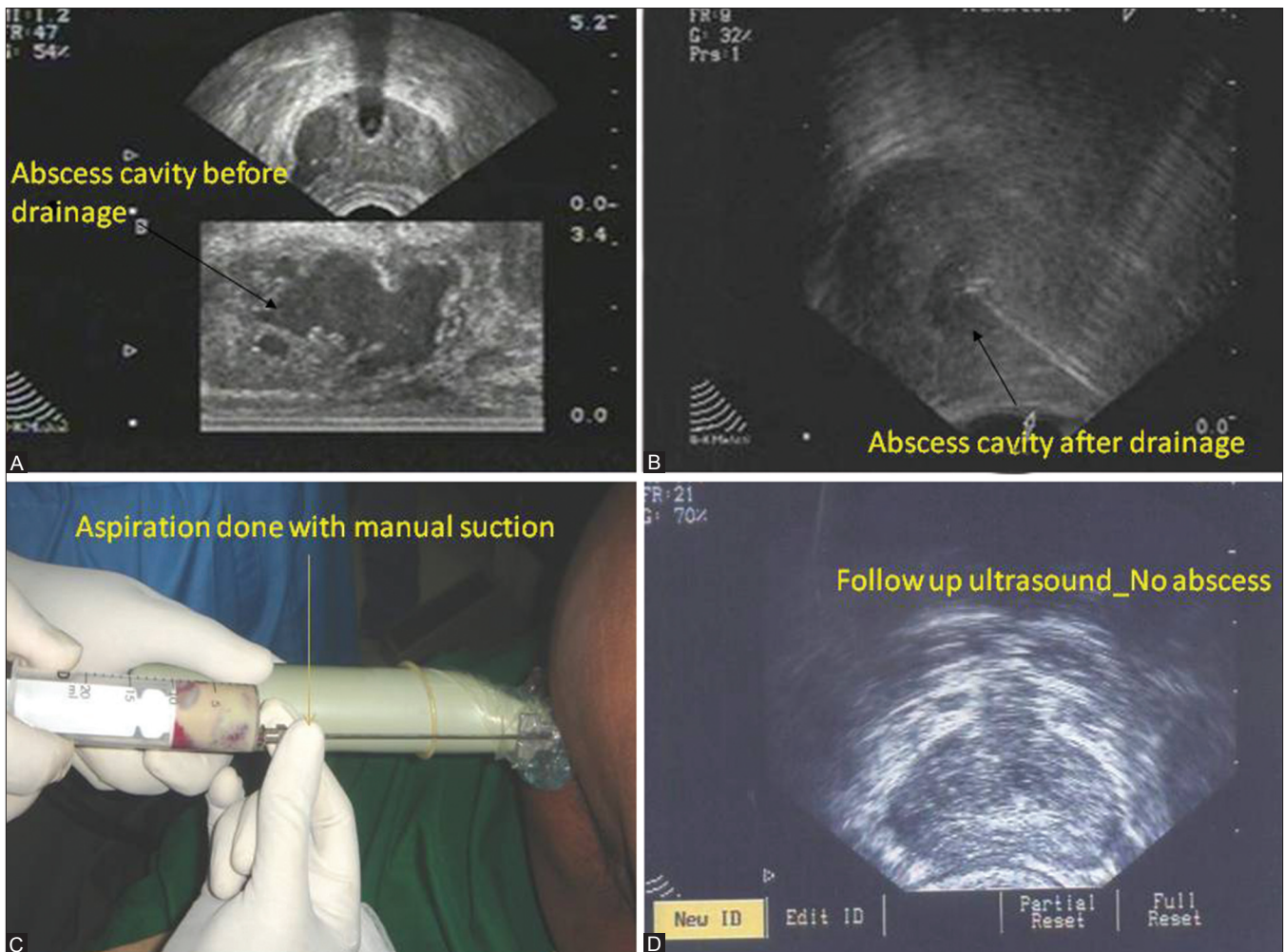


Figure 2 (A-D): The TRUS image of needle aspirating PA (A) The size, shape, location of the PA (hypoechoic lesion) was noted (B) An 18-gauge two-part needle was used for aspiration. The assembly involves a stylet with an 18-gauge needle. The needle is attached to a 20-cc syringe. The real-time TRUS-guided aspiration of PA was done in the longitudinal axis. The trajectory of the needle was ascertained using the electronic dotted line inbuilt in the probe (C) The aspirated fluid was analyzed for culture, fungus, acid-fast bacilli (AFB) staining (D) A follow-up TRUS shows resolution of abscess

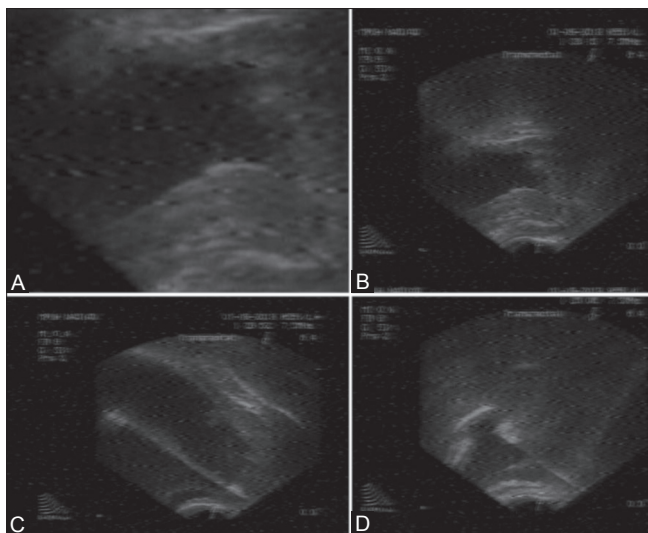


Figure 3 (A-D): (A) Prostatic abscess in longitudinal section (B) Prostatic abscess in transverse section (C) TRUS-guided aspiration in longitudinal section (D) TRUS-guided aspiration in transverse section

14.58%). Seven (14.58%) patients required transurethral resection (TURP; deroofing) of the abscess cavity. In all these patients, “deroofing” was not associated with sepsis. Based on these findings, we propose a treatment algorithm.

Follow-up

Once confirmed (on TRUS) that the patient is cured, the patients were followed up at 1 month, 3 months and 6 months. On two follow-ups, TRUS was done. None had recurrence or residual disease, and the patients were asymptomatic. We prescribed them antibiotics in chemoprophylactic dose. Urine culture was done in the first two follow-ups and antibiotic was stopped after 3 months.

Discussion

The majority of PA the patients present during the fifth or sixth decade of life and constitute approximately 0.5% of those hospitalized for prostatic disorders.^[4] Diabetes

mellitus, immune-compromised status, renal failure on prolonged dialysis, bladder outlet obstruction, recent prostatic biopsy, or prolonged catheterization are the common predisposing factors in these cases.^[4] The two mechanisms involved in the pathogenesis of PA are the first and the most common reflux of infected urine and the second mechanism is hematogenous dissemination from a primary focus. A certain level of clinical suspicion is required to diagnose this condition. It should be suspected when there are recurrent or persistent symptoms of fever, dysuria, urethral discharge or frequency associated with urinary tract infection, despite adequate antibiotic treatment.^[5]

Bhagat *et al.*, compared the clinical presentation of PA and treatment outcomes in two groups of patients in different time frames. They compared the etiologies, and the impact of multidrug-resistant organisms. They concluded that this entity is seen in younger population recently, even in individuals having no comorbidities. They note a growing trend of HIV infection, with tuberculous PA emerging as an important causative factor.^[6]

Interestingly, the aspirated pus in our series was sterile in majority of the cases. One patient had *Mycobacterium tuberculosis* in the aspirate and was administered antituberculous therapy. This finding is relevant to the Indian scenario. Hashimura *et al.*, have reported a case of PA following intravesical BCG instillation.^[7] There have been reports of PA due to other endemic infections such as *Burkholderia pseudomallei* treated with TRUS-guided aspiration.

In the past, the cornerstone for diagnosis was DRE. In recent years, TRUS has been an added tool in the armamentarium to diagnose PA. The most common finding of PA on TRUS is detection of a hypoechoic or anechoic area that is usually well defined with thick walls. Besides TRUS, computerized tomography (CT) and magnetic resonance imaging (MRI) have also been used to diagnose PA. The appearance of low-attenuating, round, well-demarcated fluid collections within the prostate gland by CT is suggestive of PA.^[8] Diffusion-weighted MRI was used in neurological disorders; recently, it has been used in prostatic disorders. In a recent study, the authors present diffusion-weighted imaging (DWI) findings in two patients of PA.^[9] CT and MR, however, do not offer a real-time assessment of treating the abscess. In addition, follow-up after treatment with CT and MRI is cumbersome and expensive. TRUS and TRUS-guided aspiration negate all the drawbacks of CT and MRI in the diagnostic and therapeutic algorithm for management of PA [Figure 4].

Historically, the treatment of PA included surgical intervention such as transurethral prostate incision (TUIP), TURP, or transperineal tube placement. TUR deroofting

is a far more invasive approach, and is associated with several risks such as hemorrhage, retrograde ejaculation, and sepsis. Sepsis is one of the dreaded complications, because of the theoretical risk of irrigation fluid-induced bacteremia in the scenario of PA. Our study shows that none of the seven patients who required subsequent transurethral intervention developed sepsis, thus proving the fact that TRUS-guided aspiration of PA makes TURP/TUIP, if required, a safe procedure.

Continuous drainage with a tube placed under TRUS guidance is an attractive alternative to simple aspiration. This has been described by the transperineal and transrectal route under TRUS guidance, due to the excellent safety profile of the method and, mainly, the longer time of drainage (24-36 h), thus allowing a low-pressure complete emptying of the lesion through a wide tube. However, this approach is fraught with a serious risk of developing a prostate-rectal fistula formation and prolonged hospitalization.^[10] In a study by Arrabal-Polo *et al.*, the authors describe transrectal ultrasound-guided transperineal placement of malecot catheter. Although quite efficient, the patients were hospitalized for 48 h.^[11]

Our series represents one of the largest series in managing PA with TRUS-guided aspiration. It has been shown in the past that TRUS-guided aspiration is the method of choice for management of PA.^[12] We suggest that TRUS followed by TRUS-guided aspiration has a pivotal role in the management of PA. The perceived advantages of TRUS are: it is a real-time examination with no radiation hazards, its easy repeatability, and ability to be used as a diagnostic as well as a therapeutic tool. As shown in our study, TRUS was 100% accurate in diagnosing PA, typically seen as hypoechoic lesion. TRUS-guided aspiration avoids the risk of per urethral catheterization, urethral stricture, retrograde ejaculation, bleeding, and incontinence (potential disadvantages of TUR). We achieved 85.42% success rate. The procedure was completed on out-patient basis. Among the 48 patients analyzed, 7 required TU deroofting. The TRUS procedure was uneventful in the majority of the cases. Hence, we feel TRUS-guided aspiration should be the first modality of treatment of PA and transurethral deroofting should be left for refractory cases.

We acknowledge that the drawback of our study includes its retrospective design. Further prospective randomized multicenter studies are required to validate our findings.

Conclusion

The proposed algorithm based on our experience suggests that patients with PA larger than 2 cm with severe LUTS and/or leukocytosis benefit from TRUS-guided aspiration; in addition, these patients are benefitted from urinary drainage (either perurethral or suprapubic). The algorithm

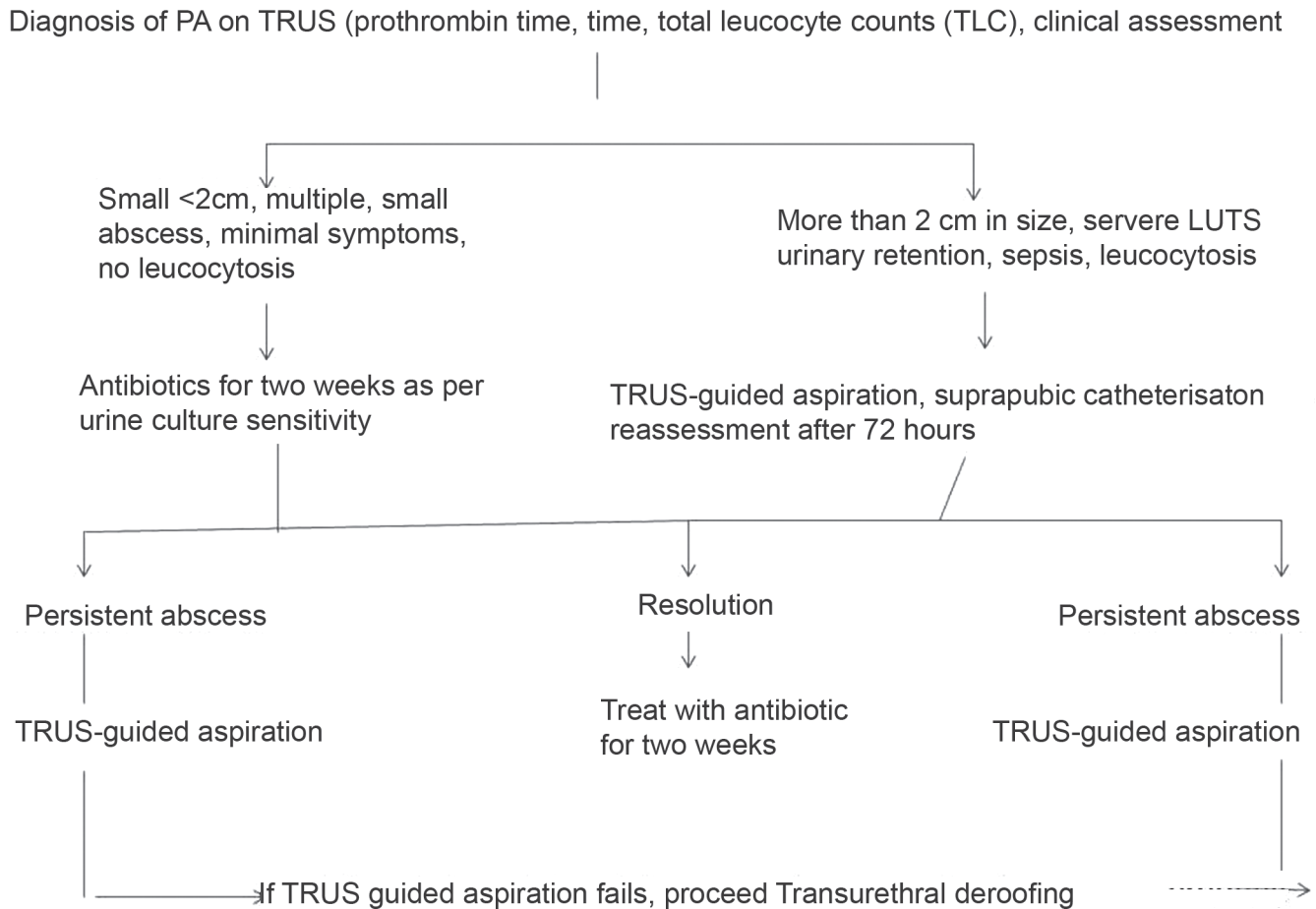


Figure 4: A proposed algorithm for management of prostatic abscess using TRUS as a tool

also suggests that if two attempts of TRUS aspiration fail, these patients benefit from transurethral drainage.

References

1. Kodman D, Ling D, Lee JKT, Percutaneous drainage of prostatic abscesses J Urol 1986;135:1259-60.
2. Zigelboim J, Goldfarb RA, Mody D; Prostatic abscess due to Histoplasma capsulatum in patient with the acquired immunodeficiency syndrome. J Urol 1992;147:166-8.
3. Ludwig M, Schroeder-Printzen I, Schiefer HC, Weidner W. Diagnosis and therapeutic management of 18 patients with prostatic abscess. Urology 1999;53:340-5.
4. Mariani AJ, Jacobs LD, Hariharan A, Emphesemoatous Prostatic abscess, Diagnosis and Treatment. J Urol 1983;129:385-6.
5. Pai, M G and Bhat, H S: Prostatic abscess. J Urol 1972;108:599-600.
6. Bhagat SK, Kekre NS, Gopalkrishna G, Balaji V, Mathews MS, Changing profile of prostatic abscess. Int Braz J Urol 2008;34:164-70.
7. Hashimura M, Momose H, Takenaga M, Hoshiyama H, Fujimoto K, Ono T, et al. Tubercular prostatic abscess following intravesical Bacillus Calmette – Guerin therapy. Hinyokika Kyo 2012;58:169-72.
8. Dennis MA, Donohou RE. Computed tomography of prostatic abscess. J Comput Assist Tomogr 1985;9:201-2.
9. Singh P, Yadav MK, Singh SK, Lal A, Khandelwal N, Case series: Diffusion weighted MRI appearance in prostatic abscess. Indian J radiol Imaging 2011;21:1751-4.
10. Aravantinos E, Kalogeras N, Zygoulakis N, Kakkas G, Anagnostou T, Melekos M, Ultrasound – guided transrectal placement of drainage tube as therapeutic management of patients with prostatic abscess. Journal of endourology 2008;22:1751-4.
11. Arrabal – Polo MA, Jimenez – Pacheco A, Arrabal – Martin M, Percutaneous drainage of prostatic abscess: Case report and literature review. Urol Int 2012;88:118-20.
12. Lim JW, Ko YT, Lee DH, Park SJ, Yoon Y, et al. Treatment of prostatic abscess: Value of transrectal ultrasonographically guided needle aspiration. J Ultrasound Med 2000;19:609-17.

Cite this article as: Vyas JB, Ganpule SA, Ganpule AP, Sabnis RB, Desai MR. Transrectal ultrasound-guided aspiration in the management of prostatic abscess: A single-center experience. Indian J Radiol Imaging 2013;23:253-7.

Source of Support: Nil, **Conflict of Interest:** None declared.