

# Variations of celiac axis, common hepatic artery and its branches in 600 patients

Binit Sureka, Mahesh Kumar Mittal, Aliza Mittal<sup>1</sup>, Mukul Sinha, Narendra Kumar Bhambri, Brij Bhushan Thukral

Department of Radiodiagnosis and <sup>1</sup>Pediatrics, Vardhman Mahavir Medical College and Safdarjung Hospital, New Delhi, India

**Correspondence:** Dr. Binit Sureka and Dr. MK Mittal, Department of Radiodiagnosis, VMMC and Safdarjung Hospital, Resident Doctors Hostel, Room - 57, New Delhi - 110 029, India. E-mail: binitSUREKA@hotmail.com

## Abstract

**Purpose:** To evaluate the spectrum of celiac axis, common hepatic artery (CHA), right, left, middle hepatic artery and gastroduodenal artery variations by using spiral computed tomography (CT). **Materials and Methods:** A retrospective review of Multidetector CT (MDCT) abdominal angiography scans was performed in patients sent for various liver and other abdominal pathologies between January 2012 and February 2013. A total of 600 patients were evaluated. Definitions of CHA, ambiguous celiac axis, course and division patterns of CHA, replaced hepatic artery, accessory hepatic artery and middle hepatic artery were used as proposed by Song *et al.*, Covey *et al.*, and Wang *et al.* The pattern of the aortic origin of branches of celiac axis, common hepatic artery and its branches was analyzed. **Results:** Six types of celiac axis anatomic variations were identified in our study. A total of 546 of the 600 patients had a normal celiac axis anatomy. Anatomic variations were seen in 5.5% of patients. Ambiguous anatomy was seen in 3.5% of the patients. CHA originated from celiac axis in 95.83% of the patients. Variations in anatomic origin of CHA were seen in 8 patients. Ambiguous dual pathway was seen in 4 patients. Normal Sp-preportal course of CHA was identified in 97.78% of cases, Sp-retroportal course in 7 patients, Tp-preportal course in 2, Tp-retroportal in 1, lp-preportal in 1 and through Ligamentum venosum in 2 patients. Normal origin of RHA from HAP was seen in 79.6% patients. Replaced origin of RHA was seen in 15.16% cases and Accessory origin of RHA was seen in 5.16% cases. LHA originated from HAP in 81.5% patients. Replaced LHA origin was seen in 10.8% cases and Accessory LHA origin seen in 7.6% cases. MHA originated from RHA in 41.3% patients, LHA in 27.83% and from CHA in 4.5% cases. Origin of MHA could not be defined in 26.3% of patients. GDA originated from CHA in 97.6% of patients, from celiac axis in 1.6%, from RHA in 0.33% in patients. Trifurcation of CHA was seen in 7.16% and quadrifurcation of CHA in 2.16%. **Conclusion:** CT Angiography is a safe and highly sensitive and accurate modality for evaluation of arterial anatomy and its variants.

**Key words:** Abdominal angiography; accessory; ambiguous celiac axis; celiac axis; common hepatic artery; replaced hepatic artery

## Introduction

The importance of celiac axis, common hepatic artery variations, and origin of middle hepatic artery has been an area of great interest and research since 1756 when

Haller first described celiac axis variations. In 1955, Michel described the classification scheme for describing anatomic variation in the hepatic arterial blood supply based on the results of dissecting 200 cadavers [Table 1].<sup>[1]</sup> In 1969, Vandamme *et al.*, did extensive research on hepatic artery anomalies on 156 cadavers.<sup>[2]</sup> Then, in 1971, Suzuki *et al.*, published their series on 200 patients based on angiography study and also highlighted the importance of hepatic artery variations.<sup>[3]</sup> In 2010, Song *et al.*, published the largest series of their work in celiac axis and hepatic artery variations in 5002 patients.<sup>[4]</sup>

Recently, with the advent of newer interventional and surgical options for patients with primary and metastatic

### Access this article online

#### Quick Response Code:



**Website:**  
www.ijri.org

**DOI:**  
10.4103/0971-3026.120273

hepatic malignancies, partial hepatectomy for liver transplantation and laparoscopic cholecystectomy, surgeons and interventional radiologists are now relying on accurate imaging and assessment of the hepatic arterial supply. A road map of the arterial vascularity of the donor and recipient is a prerequisite for transplant surgery [Table 2].<sup>[5]</sup> Detailed hepatic arterial anatomy and its variations has its significance in liver surgeries and interventional hepatic procedures, relative to the hepatic lobe involved [Table 3].<sup>[5]</sup>

The purpose of this study was to study the anatomic variations in the origin and course of celiac axis, common hepatic artery and its branches – right, left, middle hepatic, and gastroduodenal arteries.

## Materials and Methods

### Patients

Approval for the study was obtained from the ethical board of the Institution. Multidetector CT (MDCT) abdominal angiography scans were obtained in patients sent for various liver and other abdominal pathologies in which biphasic contrast-enhanced CT was indicated. The time period of the study was from January 2012 to February 2013. A total of 600 patients were evaluated. The study population comprised 413 men and 187 women (mean age 39.8 years). We excluded patients with a history of major upper abdominal surgery.

### CT examination protocol

MDCT angiography was performed on Philips Brilliance 40-slice after injecting maximum of 120 mL of nonionic iodinated contrast material (iodine concentration, 370 mg/mL) through an 18-20-gauge antecubital intravenous cannula at a rate of 5-7 mL/sec. The detailed multidetector CT angiography technique is summarized in Table 4.

### Image interpretation

The raw imaging data obtained from MDCT were processed on a commercially available workstation for multiplanar reformation as well as 3D reconstruction with maximum intensity projection (MIP) and volume rendering. The images were analyzed independently by three radiologists Radiologist 1 (B.S.) with 5 years, Radiologist 2 (M.S.) with 20 years and Radiologist 3 (M.K.M) with 24 years of experience in interpreting CT scans. The abbreviations used in this study are listed in Table 5. We analyzed the celiac axis anatomy and origin of the four major arteries – the common hepatic, splenic, left gastric, and superior mesenteric arteries. We also studied the origin of right hepatic artery (RHA), left hepatic artery (LHA), middle hepatic artery (MHA), and gastroduodenal artery (GDA). The course and relationship of common hepatic artery (CHA) to the surrounding structures (portal vein, pancreas head, or uncinate process) was also analyzed. We used some key definitions described by various authors for evaluating these arteries.

**Table 1: Hepatic arterial variants according to the Michel's classification<sup>[1]</sup>**

Type	Frequency (%)	Description
I	55	RHA, MHA, and LHA arise from the CHA
II	10	RHA, MHA, and LHA arise from the CHA; replaced LHA from the LGA
III	11	RHA and MHA arise from the CHA; replaced RHA from the SMA
IV	1	Replaced RHA and LHA
V	8	RHA, MHA, and LHA arise from the CHA; accessory LHA from the LGA
VI	7	RHA, MHA, and LHA arise from the CHA; accessory RHA
VII	1	Accessory RHA and LHA
VIII	4	Replaced RHA and accessory LHA or replaced LHA and accessory RHA
IX	4.5	Entire hepatic trunk arises from the SMA
X	0.5	Entire hepatic trunk arises from the LGA

CHA: Common hepatic artery, LGA: Left gastric artery, LHA: Left hepatic artery, MHA: Middle hepatic artery, RHA: Right hepatic artery, SMA: Superior mesenteric artery

**Table 2: Hepatic arterial variants and liver transplantation<sup>[5]</sup>**

Arterial variants	Implications for surgery
Variants relevant in donors	
MHA from the RHA	The hepatic plane would cut this artery, compromising arterial supply to the left lobe of the liver
CHA trifurcation into the RHA, LHA, and GDA	Clamping or ligation of the CHA can cause gastric or duodenal hypoperfusion
RHA or LHA from the CHA before origin of the GDA	Clamping or ligation of the CHA can cause gastric or duodenal hypoperfusion
Variants relevant in recipients	
Short RHA	Increases surgical complexity and can lead to difficult anastomosis
Celiac artery stenosis	Increases the risks of graft failure and biliary complications
Replaced or accessory LHA (Michel types II and V)	Increases complexity of surgery
Replaced hepatic trunk arising from the SMA (Michel type IX)	Increases complexity of surgery

CHA: Common hepatic artery, GDA: Gastroduodenal artery, LHA: Left hepatic artery, MHA: Middle hepatic artery, RHA: Right hepatic artery, SMA: Superior mesenteric artery

**Table 3: Hepatic arterial variants and relevance for tumor resection<sup>[5]</sup>**

Arterial variants	Michel type	Left lobe resection	Right lobe resection
Replaced LHA from the LGA	II	Yes	No
Replaced RHA from the SMA	III	No	Yes
Replaced RHA and LHA	IV	Yes	No
Accessory LHA from the LGA	V	Yes	No
Accessory RHA	VI	No	Yes
Accessory RHA and LHA	VII	Yes	Yes
Replaced RHA and accessory LHA or replaced LHA and accessory RHA	VIII	Yes	Yes
Entire hepatic trunk from the SMA	IX	Yes	Yes
Entire hepatic trunk from the LGA	X	Yes	Yes

LGA: Left gastric artery, LHA: Left hepatic artery, RHA: Right hepatic artery, SMA: Superior mesenteric artery

**Key definitions**

- CHA<sup>[4]</sup>: Artery giving rise to RHA or LHA and the GDA, irrespective of its origin and course.
- Ambiguous celiac axis<sup>[4]</sup>: Congenital absence of CHA or congenital presence of an anastomotic channel connecting the celiac axis and superior mesenteric artery (SMA) or anastomotic channel connecting the CHA to the celiac axis and the SMA.
- Typical celiac axis<sup>[4]</sup>: Arterial trunk that gives rise to the common hepatic, left gastric, and splenic arteries.
- Replaced<sup>[6]</sup>: Replaced origin of hepatic arteries refers to the arterial blood supply from an ectopic location.
- Accessory<sup>[6]</sup>: Accessory origin of hepatic arteries refers to the arterial blood supply from typical as well as ectopic branch.
- Double hepatic arteries<sup>[6]</sup>: Defined when there is early branching of the RHA and/or LHA off the celiac axis or when one or both hepatic arteries arise directly from the aorta or when no CHA with GDA originates from either hepatic artery.
- Late origin of GDA<sup>[6]</sup>: GDA originates from one hepatic artery after the division of the CHA into the RHA and LHA.
- Early branching of RHA/LHA<sup>[6]</sup>: RHA/LHA originating before GDA.
- Trifurcation<sup>[6]</sup>: CHA divides into GDA, RHA, and LHA.
- Quadrifurcation<sup>[6]</sup>: CHA divides into GDA, RHA, LHA, and MHA.
- Suprapancreatic<sup>[4]</sup>: CHA running along the upper border of pancreas.
- Transpancreatic<sup>[4]</sup>: CHA passing through pancreatic parenchyma.
- Infrapancreatic<sup>[4]</sup>: CHA coursing inferior to the pancreatic head and uncinate process.
- Preportal<sup>[4]</sup>: Hepatic artery anterior to the main portal vein.
- Retroportal<sup>[4]</sup>: Hepatic artery posterior to the main portal vein.
- MHA<sup>[7]</sup>: Hilar artery that primarily supplies hepatic segment 4.

**Results**

**Celiac axis variations**

A total of 546 (91%) of the 600 patients had a normal celiac axis anatomy, i.e. hepatogastrosplenic trunk and SMA originating separately from the aorta. Six types of celiac axis anatomic variations were identified in our study [Table 6]. These were seen in 33 (5.5%) of the patients. Ambiguous anatomy was seen in 21 (3.5%) patients.

**CHA variations**

CHA originated from the celiac axis in 575 (95.83%) of the patients. Variations in anatomic origin of CHA were seen in eight patients (origin from SMA in six and from aorta in two patients). Ambiguous dual pathway (hepatomesenteric

trunk) was seen in 4 (0.66%) patients. The origin of CHA could not be determined in 13 (2.16%) of the patients.

Normal suprapancreatic (Sp)-preportal course of CHA was identified in 576 (98.12%) of the cases. Sp-retroportal course was seen in seven patients, transpancreatic (Tp)-retroportal

**Table 4: Protocol for multidetector CT angiography**

Parameter	Hepatic arterial phase	Venous phase
Range	Entire liver	Entire abdomen
Scan delay		
Empirical (sec)*	20-25	60-65
Bolus tracking (HU)**	125	-
Pitch	1.0-1.5	1.0-1.5
Section thickness (mm)	1-2	2-5
Tube potential (kVp)	120-140	120-140
Tube current (mA)	200-280	200-280
Image reconstruction thickness (mm)	1-2 with 50% overlap	2-5 with 50% overlap

\*Time after the start of the bolus injection, \*\*Scanning is automatically triggered at 125 HU in the aorta at the celiac artery level, CT: Computed tomography

**Table 5: Abbreviations used in this study**

Abbreviation	Description
CHA	Common hepatic artery
HAP	Hepatic artery proper
SMA	Superior mesenteric artery
LGA	Left gastric artery
RHA	Right hepatic artery
LHA	Left hepatic artery
MHA	Middle hepatic artery
GDA	Gastroduodenal artery
SpA	Splenic artery
HM trunk	Hepatomesenteric trunk
HSp trunk	Hepatosplenic trunk
GSp trunk	Gastrosplenic trunk
CM trunk	Celiacomesenteric trunk
HSpM trunk	Hepatosplenomesenteric trunk
Sp	Suprapancreatic
Tp	Transpancreatic
Ip	Infrapancreatic

**Table 6: Celiac axis variations in 600 patients**

Celiac axis anatomy type	No. of patients (N=600)
Normal anatomy*	546 (91)
Anatomic variation	33 (5.5)
HSp+LG+SMA	17 (2.83)
GSp+CH+SMA	5 (0.83)
GSp+HM trunk	4 (0.66)
CM trunk	4 (0.66)
HM trunk+LG+SpA	2 (0.33)
HSpM trunk+LG	1 (0.16)
Ambiguous anatomy	21 (3.5)

Numbers in brackets are percentages, \*Normal Anatomy refers to hepatogastrosplenic trunk plus SMA. All other abbreviations are expanded in Table 5, SMA: Superior mesenteric artery

in one, infrapancreatic (Ip)-preportal in one, and through ligamentum venosum in two patients. Detailed findings of CHA variations are summarized in Table 7.

#### RHA, LHA, MHA, and GDA variations

Normal origin of RHA from hepatic artery proper (HAP) was seen in 478 (79.6%) patients. Replaced origin of RHA was seen in 91 (15.16%) cases and accessory origin of RHA was seen in 31 (5.16%) cases. LHA originated from HAP in 489 (81.5%) patients. Replaced LHA origin was seen in 65 (10.8%) cases and accessory LHA origin seen in 46 (7.6%) cases. MHA originated from RHA in 248 (41.33%) patients, from LHA in 167 (27.83%), and from CHA in 27 (4.5%) cases. Origin of MHA could not be defined in 158 (26.3%) of the patients. GDA originated from CHA in 586 (97.6%) of the patients, from celiac axis in 10 (1.6%), and from RHA in 2 (0.33%) patients. Origin of GDA could not be determined in two cases. Detailed anatomic variations of RHA, LHA, MHA, and GDA are summarized in Table 8.

#### Other variations

Trifurcation of CHA was seen in 43 (7.16%) and quadrifurcation of CHA in 13 (2.16%) of the patients. Early branching of RHA was seen in 5 (0.83%) and early branching of LHA in 3 (0.5%) of the patients. Double hepatic arteries were seen in 14 (2.33%) patients. Late origin of GDA was seen in two patients.

## Discussion

By using clear definitions pertaining to the origin and course of these vessels as already mentioned, we performed systematic analysis of CT angiography images and were able to identify and classify the comprehensive spectrum of celiac axis, CHA, RHA, LHA, MHA, and GDA variations, including their variant origins and 3D anatomic courses. According to Tandler *et al.*,<sup>[8]</sup> four primitive ventral branches arise from the abdominal aorta that are interconnected by an anastomotic channel during embryogenesis. It is the persistent overgrowth or regression of these primitive vascular channels which leads to the development of variations of the celiac axis and the SMA. On the basis of this hypothesis, 15 types of celiac axis variation are possible.<sup>[9]</sup> Six of these 15 types were found in this study. According to Michels, the prevalence of a normal celiac axis anatomy is 89%. In our study, normal celiac axis anatomy was seen in 91% [Figure 1]. The most common anatomic variation was of hepatosplenic trunk with separately originating left gastric artery (LGA) and SMA (2.83%) [Figure 2]. This result was consistent with the results obtained by Song *et al.*<sup>[4]</sup> The next common anatomic variation in our study was that of gastrosplenic trunk with separate origins of CHA and SMA (0.83%) [Figure 3], followed by that of gastrosplenic trunk and a common hepatomesenteric trunk. This variation was seen more frequently in our study as compared to that observed by Song *et al.*<sup>[4]</sup> Ambiguous celiac axis anatomy was identified in 21 (3.5%) of the patients. Ambiguous

**Table 7: CHA anatomy and course in 600 patients**

CHA origin	No. of patients (n=600)	Course of CHA	No. of patients (n=587)
Celiac axis	575 (95.83)	Normal Sp-preportal	576 (98.12)
SMA	6 (1)	Sp-retroportal	7 (1.19)
Aorta	2 (0.33)	Ligamentum venosum	2 (0.34)
Ambiguous dual pathway: HM trunk	4 (0.66)	Tp-retroportal	1 (0.17)
Not determined	13 (2.16)	Ip-preportal	1 (0.17)

Numbers in brackets are percentages. All other abbreviations are expanded in Table 5, CHA: Common hepatic artery, SMA: Superior mesenteric artery

**Table 8: RHA, LHA, GDA, and MHA origins**

RHA, LHA, GDA and MHA origins	No. of patients (N=600)
RHA origin	
HAP	478 (79.6)
Replaced	91 (15.16)
SMA	81
Celiac axis	8
Aorta	2
Accessory	31 (5.16)
SMA	21
Celiac axis	6
Aorta	4
LHA origin	
HAP	489 (81.5)
Replaced	65 (10.8)
LGA	63
Aorta	2
Accessory	46 (7.6)
GDA origin	
CHA	586 (97.6)
Celiac axis	10 (1.6)
RHA	2 (0.33)
Not defined	2 (0.33)
MHA origin	
RHA	248 (41.33)
LHA	167 (27.83)
CHA	27 (4.5)
Not defined	158 (26.3)

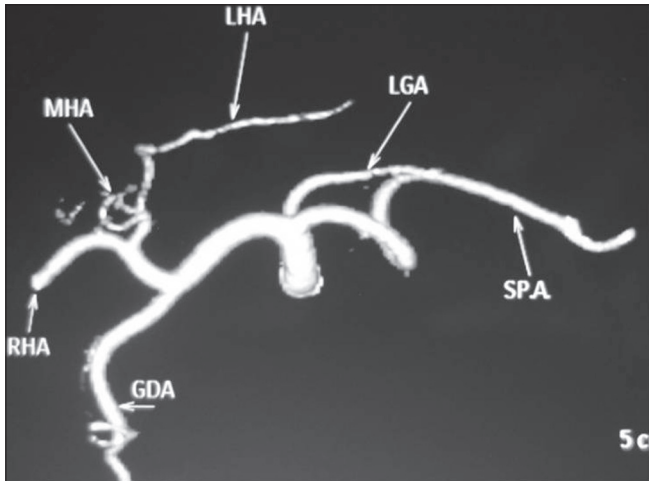
Numbers in brackets are percentages. All other abbreviations are expanded in Table 5, RHA: Right hepatic artery, LHA: Left hepatic artery, GDA: Gastroduodenal artery, CHA: Common hepatic artery, HAP: Hepatic artery proper, SMA: Superior mesenteric artery, MHA: Middle hepatic artery

anatomy due to persistent anastomotic channel was seen in 8 patients [Figure 4] and due to absent CHA was seen in 13 patients [Figure 5]. This persistent anastomotic channel is also known as the Arc of Buehler. The Arc of Buehler is a remnant of a ventral anastomosis that interconnects embryonic ventral segmental arteries.<sup>[8,10,11]</sup>

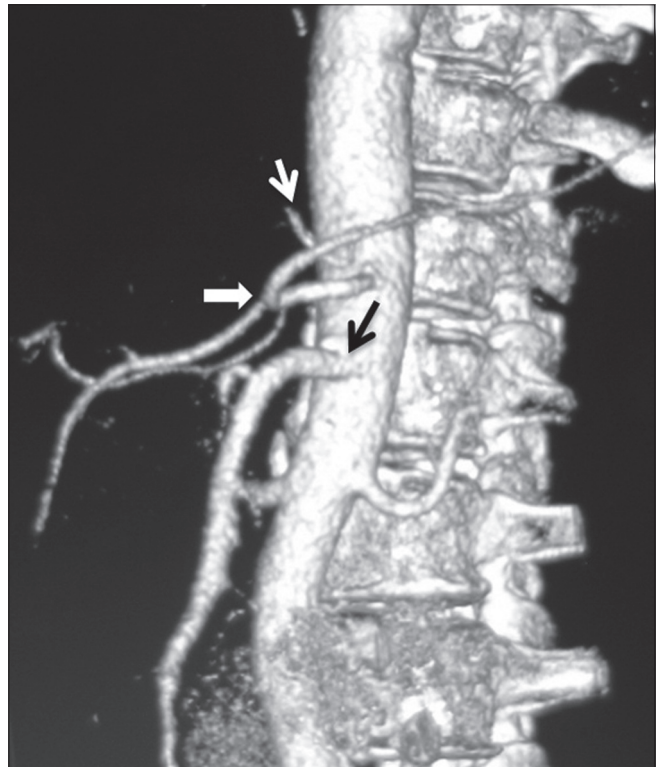
Normal CHA origin was seen in 575 (95.83%) of the cases. Normal Sp-preportal course of CHA was seen in 576 (98.12%) patients. The SMA has been known as the most common origin site of a variant CHA. In our study

also, we found similar findings with six cases of CHA arising from the SMA. CHA, after arising from the SMA, has three levels of pathways relative to the pancreatic

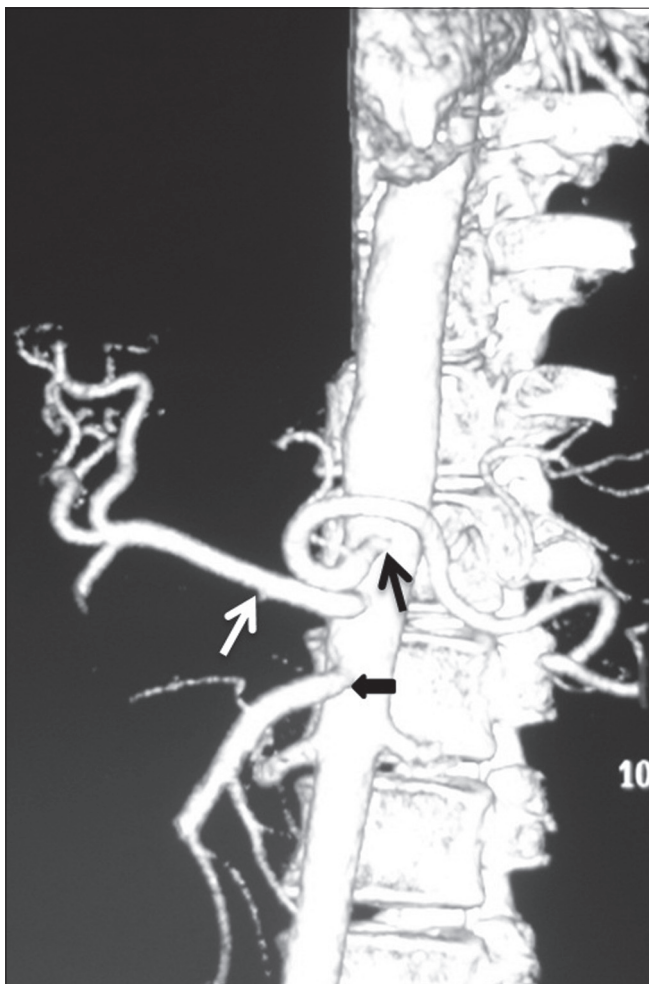
head and the uncinate process – supra-, trans-, and infrapancreatic courses – as described by Song *et al.* The Sp-retroportal course was the most common type of variant



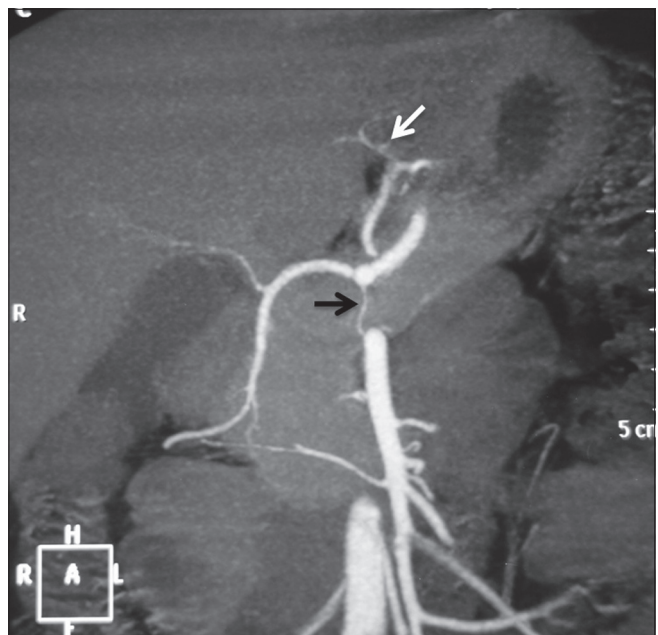
**Figure 1:** Volume-rendered images showing normal anatomy of the celiac axis and its branches



**Figure 2:** Volume-rendered image showing anatomic variation of the celiac axis (LG + HSp + SMA) with LGA (white arrow) arising from aorta, hepatosplenic trunk (arrowhead), and separate origin of SMA (black arrow)



**Figure 3:** Volume-rendered image showing anatomic variation of celiac axis (GSp + CH + SMA) in the form of gastrosplenic trunk (black arrow), common hepatic (white arrow), and SMA (arrowhead) origin separately from aorta



**Figure 4:** Coronal maximum-intensity projection images showing ambiguous celiac axis due to vertical anastomotic channel (black arrow) between celiac axis and SMA. Replaced LHA from LGA (white arrow) is also noted

CHA that arose from the SMA. In our study, four cases of CHA arising from the SMA had Sp-retroportal course, one case had Tp-retroportal course [Figure 6], and one had Ip-preportal course. A separate origin of the CHA from the aorta is a rare variation, and the prevalence of this variation in our study was only 0.33%. The reported prevalences of this anomaly in two previous dissection studies were 0.2% and 0.7%, respectively.<sup>[12,13]</sup>

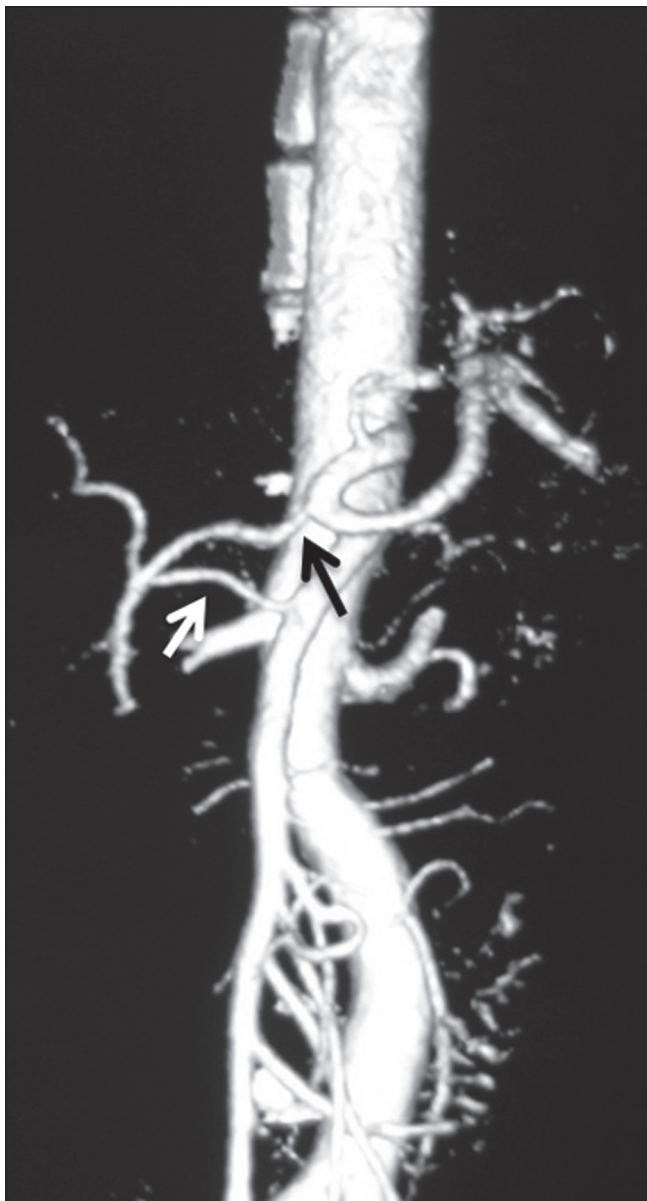RHA origin from HAP was seen in 478 (79.6%) patients. Replaced origin of RHA was seen in 91 (15.16%) of the cases. The most common site of origin of replaced RHA was from SMA (13.49%) [Figure 7] followed by celiac axis (1.33%) and aorta (0.33%) [Figure 8]. Accessory origin of RHA was seen in 31 (5.16%) of the cases. The most common site of origin

of accessory RHA was from the SMA followed by celiac axis and aorta [Figure 9]. LHA origin from HAP was seen in 489 (81.5%) patients. Replaced origin of LHA was seen in 10.8% cases, with the most common site being from the LGA (10.46%) followed by aorta (0.33%). Accessory origin of LHA was seen in 7.6% cases, with all of them arising from the LGA in our study. In our study, all replaced and accessory RHA had retroportal course and replaced/accessory LHA had course through the ligamentum venosum.

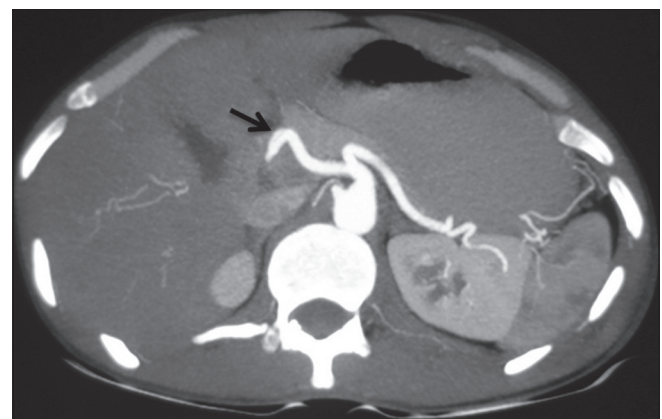
Origin and course of MHA has not been given much importance in many textbooks of anatomy or surgery. However, MHA origin has relevance in liver transplant surgery while evaluating liver donors. Michels<sup>[14]</sup> characterized the MHA as an artery in the umbilical fossa that supplies hepatic segment 4. In our study, MHA originated from RHA in 248 (41.33%) patients [Figure 10], from LHA in 167 (27.83%) [Figure 11], and from CHA in 27 (4.5%) cases. MHA could not be defined in 158 (26.3%) cases. There was no instance of MHA originating from an accessory hepatic artery in our study. Interestingly, in almost all the cases in which replaced LHA origin from LGA was seen, MHA originated from the RHA, and in cases in which replaced RHA origin from SMA or celiac axis was identified, MHA originated from the LHA. Five types of MHA have been defined according to Wang *et al.*, which are as follows:<sup>[7]</sup>

- Type I MHA: Origin from RHA in patients with a normal hepatic arterial configuration
- Type II MHA: Origin from LHA in patients with a normal hepatic arterial configuration
- Type III MHA: Origin from RHA in the presence of a replaced LHA
- Type IV MHA: Origin from LHA in the presence of a replaced RHA
- Type V MHA: Origin from CHA, HAP, and the right anterior hepatic artery (RAHA)

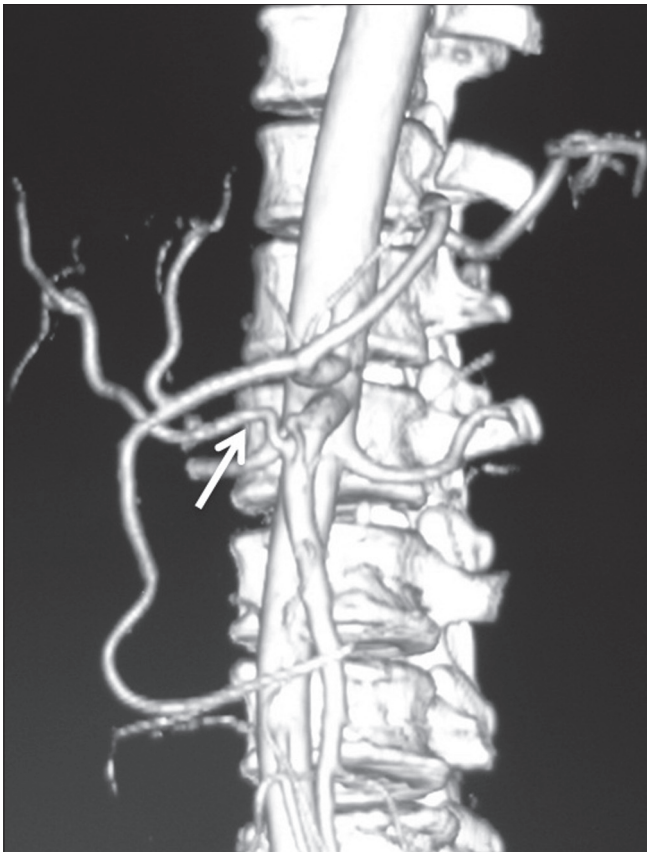
Normal origin of GDA was seen in 586 (97.6%) of the cases. In 10 cases, GDA origin was directly from the celiac axis and in 2 cases, the origin was from RHA [Figure 12]. GDA was



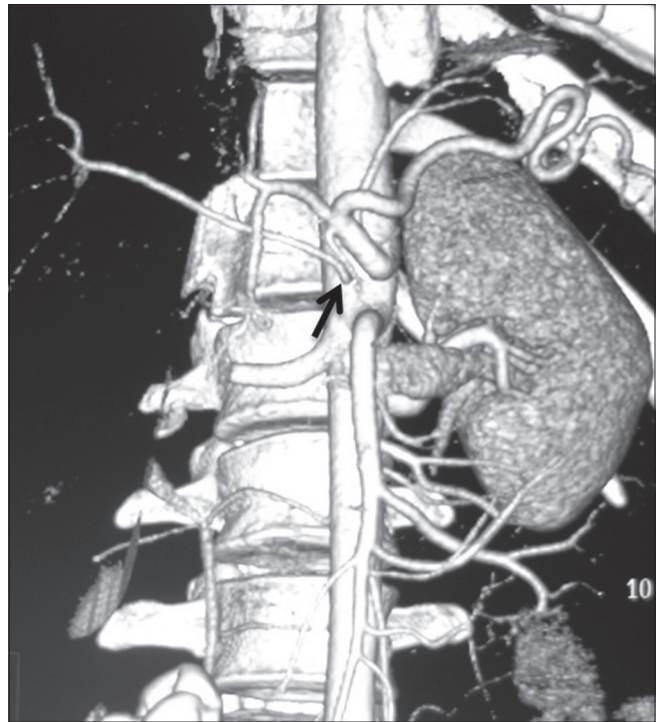
**Figure 5:** Volume-rendered image showing replaced origin of RHA (white arrow) from SMA and ambiguous celiac axis due to absent CHA and origin of GDA (black arrow) from celiac axis



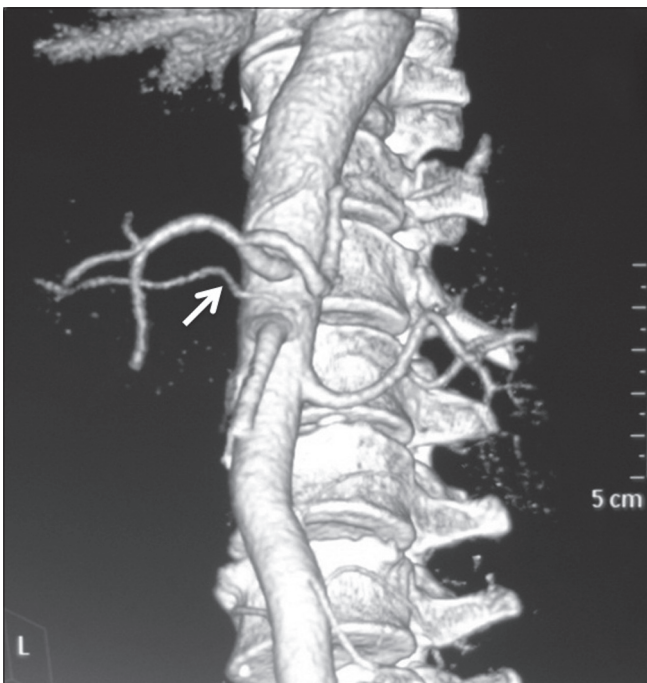
**Figure 6:** Axial maximum-intensity projection image showing transpancreatic course of CHA (arrow)



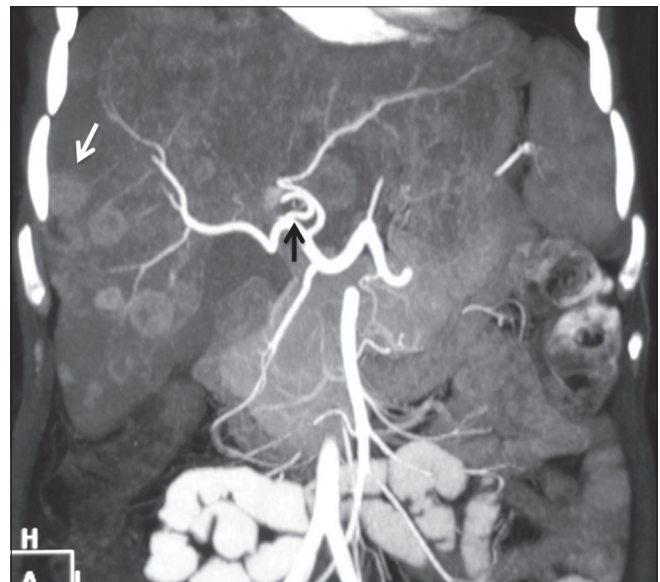
**Figure 7:** Volume-rendered image showing replaced origin of RHA (arrow) from SMA



**Figure 8:** Volume-rendered image showing replaced origin of RHA (arrow) from aorta



**Figure 9:** Volume-rendered image showing accessory origin of RHA (arrow) from aorta



**Figure 10:** Coronal maximum-intensity projection image showing origin of MHA (black arrow) from RHA. Multiple liver metastases are also seen (white arrow)

not defined in two cases. Late origin of GDA was seen in two cases. Double hepatic artery is differentiated from late

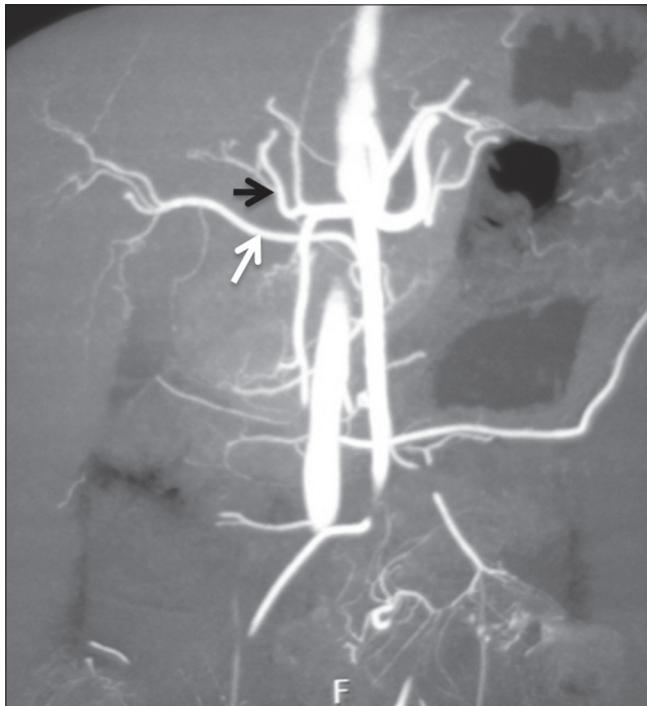origin of the GDA by the presence of a CHA. In the case of a double hepatic artery, there is no CHA and the GDA may originate from either hepatic artery. In case of a distal origin of the GDA, GDA originates from one hepatic artery after the division of the CHA into the RHA and LHA.

In our study, double hepatic arteries were seen in 14 patients, trifurcation of CHA [Figure 13] was seen in

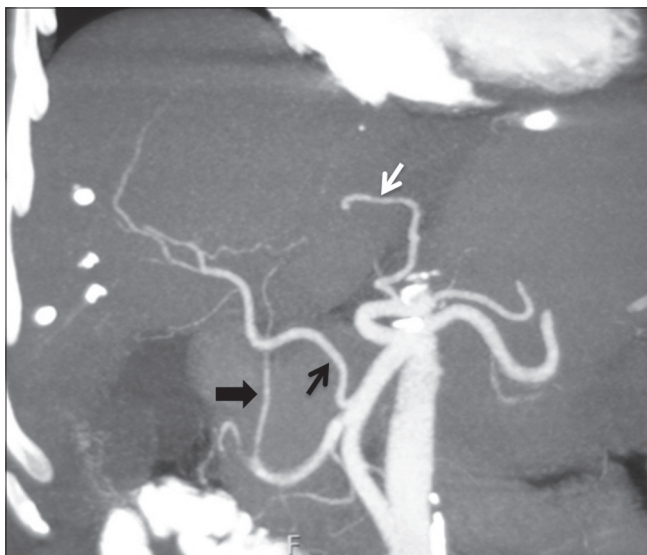
43 (7.16%), and quadrifurcation of CHA in 13 (2.16%) of the patients [Figure 14]. Early branching of RHA [Figures 15 and 16] was seen in 5 (0.83%) and early branching of LHA in 3 (0.5%) of the patients [Figure 17]. The importance of these anatomic variations has its relevance in advanced intervention procedures like transcatheter arterial chemoembolization (TACE), transarterial radionuclide therapy (TART), and placement of infusion pumps. When

placed surgically, these catheters are typically placed in the GDA in a retrograde direction with the catheter tip in the proximal GDA or in the HAP. The GDA distal to the catheter insertion site and the right gastric artery and branches supplying blood to the stomach and duodenum are ligated to prevent nontarget infusion.<sup>[15]</sup> In this position, the catheter perfuses the RHA and LHA in a patient with standard anatomy. When placed percutaneously, catheters are typically positioned in the HAP to infuse both hepatic arteries. In cases of a double hepatic artery and trifurcation or quadrifurcation of the CHA, an alternate catheter position or more than one catheter must be considered preoperatively to ensure adequate tumor perfusion.<sup>[15,16]</sup>

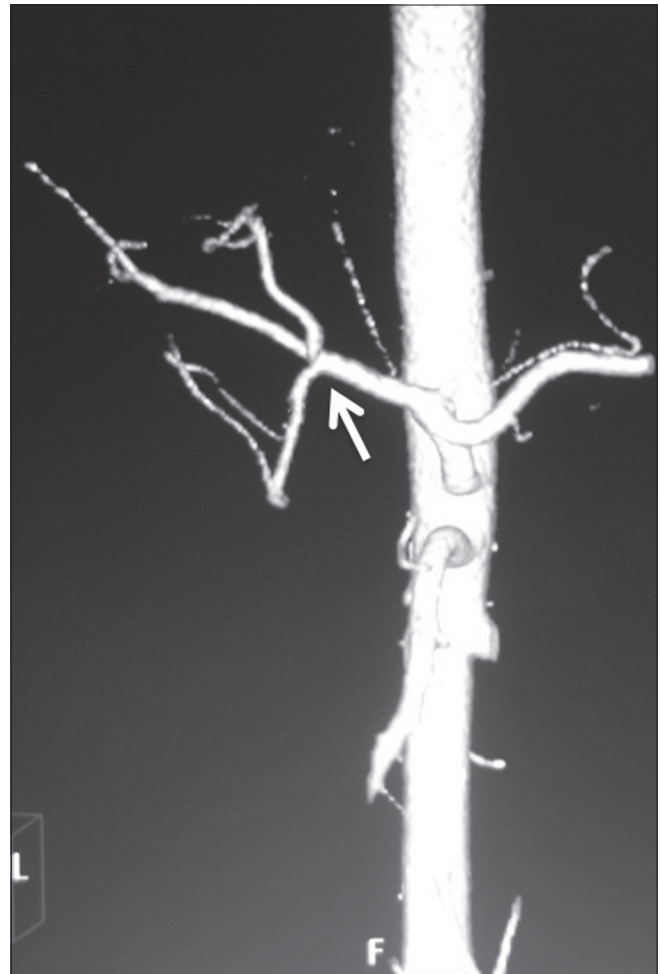
There are three main types of liver transplantation: cadaveric, live donor liver transplantation, and split-liver grafting. The right lobe of liver is resected and the left lobe left behind in living adult donors, while in children, the left lobe is resected. The incision for hemihepatectomy plane is close to Cantlie line, which is a relatively avascular plane running 1 cm to the right of the middle hepatic



**Figure 11:** Coronal maximum-intensity projection image showing replaced origin of RHA (white arrow) from SMA and origin of MHA (black arrow) from LHA

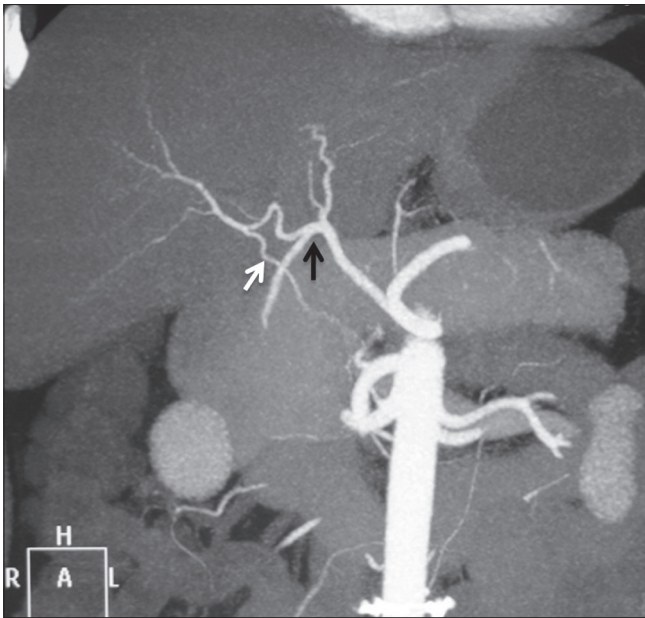


**Figure 12:** Coronal maximum-intensity projection image showing replaced RHA (black arrow) from SMA and replaced LHA (white arrow) from LGA. Ambiguous celiac axis is seen due to absent CHA and origin of GDA (arrowhead) from RHA



**Figure 13:** Volume-rendered image showing trifurcation of CHA (arrow) into RHA, LHA, and GDA

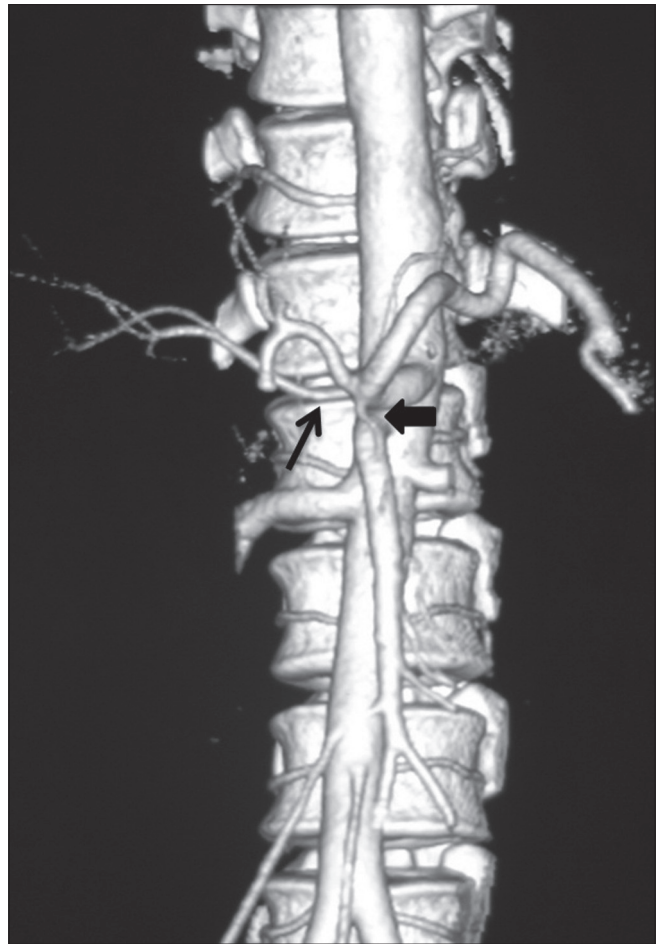




**Figure 14:** Coronal maximum-intensity projection images showing quadrifurcation of CHA (black arrow) and accessory RHA (white arrow) from SMA

vein connecting the gall bladder and the inferior vena cava. Hepatic arterial variants that need extra caution, in liver transplant donors, include the MHA arising from the RHA, as the hepatectomy plane would cut this artery, trifurcation of CHA, and early branching of RHA/LHA as ligation of the CHA can cause gastric or duodenal hypoperfusion. Similarly, arterial variants relevant for transplant recipients are short RHA, celiac artery stenosis, replaced or accessory LHA, and replaced hepatic trunk arising from the SMA, as these variations increase the complexity during the surgery. Since the entire native liver is resected in the recipient, MHA variants are not of significance for these patients. Excessive manipulation of RHA during surgery, which occurs usually due to its anomalous course, can result in biliary complications like stricture and cholangitis, ultimately leading to graft failure. This can be prevented with accurate preoperative knowledge of the arterial anatomy. In patients with normal arterial anatomy, the chemotherapy pump is placed in the hepatic artery after the origin of the gastroduodenal artery to avoid turbulence within the hepatic artery and maintain long-term patency. Adequate assessment of the arterial anatomy prior to placement of the infusion pumps reduces the chances of complications like extrahepatic misperfusion and chemotoxicity, chemical cholangitis, bleeding, and duodenitis.

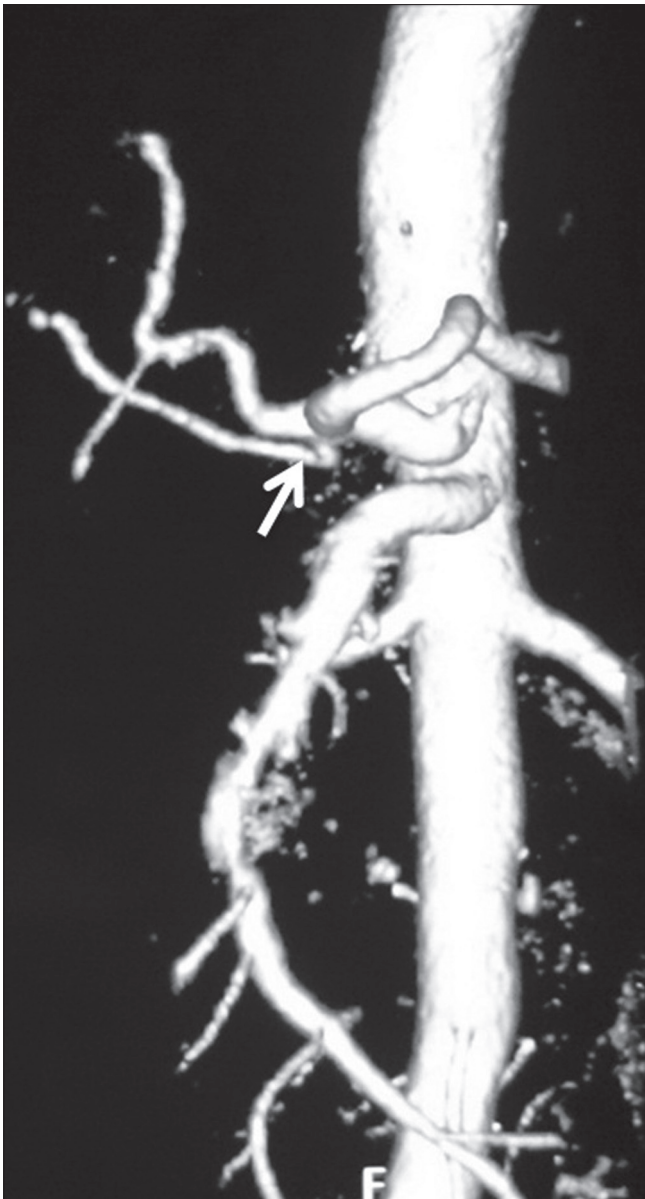
Ishigami *et al.*,<sup>[17]</sup> studied the significance of variant hepatic artery anatomy in liver transplant recipient patients and found that a small-caliber CHA often coexists with variant hepatic artery anatomy. Diameter of the CHA was measured near the origin of the GDA. The diameter of CHA was smaller in patients (mean 5.8 mm) with variant hepatic



**Figure 15:** Volume-rendered images showing early branching of RHA (arrow) with ambiguous celiac axis due to vertical anastomotic channel (arrowhead) between celiac axis and SMA

artery anatomy compared to those with classic hepatic artery anatomy (mean 6.3 mm). They concluded that variant hepatic artery anatomy in a liver transplant recipient increases the risk of post-transplantation hepatic artery complications like stenosis and thrombosis due to coexisting small caliber of CHA in these patients. Such patients can benefit from meticulous preoperative evaluation of the arterial anatomy and careful surgical planning. Accessory hepatic artery is less likely to increase the risk of such complications than a completely replaced hepatic artery because the caliber of the CHA is usually normal in cases of accessory hepatic artery.

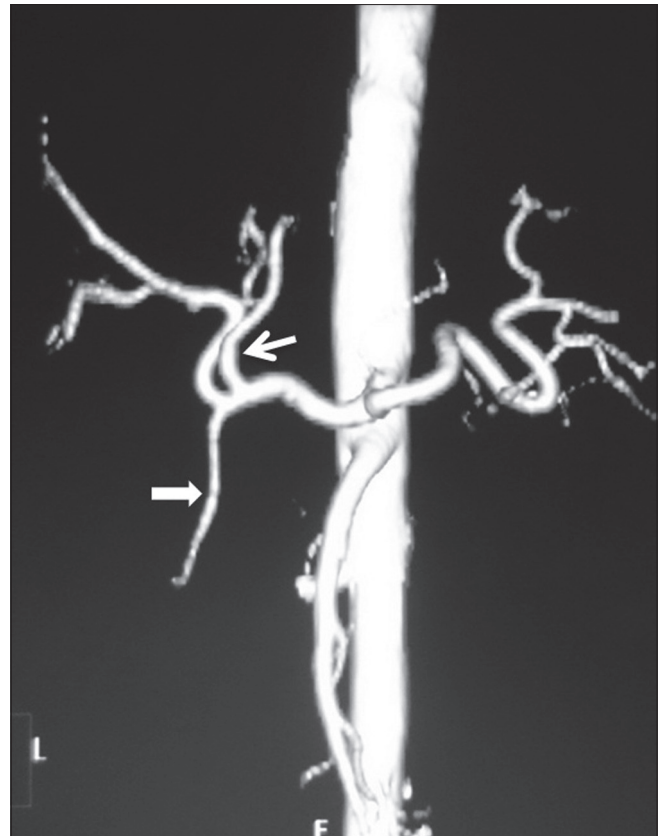
Arterial anatomy of the celiac axis and SMA is of great value in pancreatic and hepatobiliary surgeries as direct visualization of the surgical field is limited during surgeries, especially in obese and patients with prior history of surgery. Thus, preoperative knowledge of anatomic variations would help surgeons to avoid extensive dissection and vascular damage. Identification of a replaced RHA is important as it usually courses posterior to the portal vein, and knowledge of such anatomy prevents complications such as bleeding during surgery. In surgeries



**Figure 16:** Volume-rendered image showing early branching of RHA (arrow)

for malignancies of head/uncinate process of the pancreas, information on the presence or absence of a replaced RHA is critical. Since these patients are jaundiced, utmost care needs to be taken to preserve this artery if it is not involved, as hepatic necrosis is more common in these patients if the arterial flow is also compromised.<sup>[18]</sup> Anomalous origin of RHA from the celiac axis or aorta is more prone to iatrogenic injury. An accessory LHA needs to be ligated separately in surgeries where blood supply in the porta hepatis is occluded. Anomalous course of CHA should be mentioned in pancreatico-duodenal surgeries as it may be inadvertently injured during resection.

The present study had some limitations. First, since our study was based on the analysis of CT images, description



**Figure 17:** Volume-rendered image showing early branching of LHA (arrow) before GDA (arrowhead)

of fine arterial networks could have been missed and was beyond the capability of CT examination. Second, the new nomenclature system described by Song *et al.*, Covey *et al.*, and Wang *et al.*, has not been assessed on the interventional and surgical procedures by us. However, we have tried to describe detailed 3D anatomy of the variations observed by us.

This study is the first of its kind which comprehensively describes variations of celiac axis and hepatic artery branches. In today's scenario, the role of MDCT angiography in preoperative evaluation of patients undergoing hepatobiliary surgeries and advanced interventional procedures cannot be underestimated in order to avoid life-threatening complications.

### Acknowledgement

We express our sincere gratitude to our colleagues Dr. Varun, Dharendra and the faculty of the Department of Radiodiagnosis, for their valuable contribution and constant support.

### References

1. Michel NA. Observations on the blood supply of the liver and gallbladder (200 dissections). Blood supply and anatomy of the upper abdominal organs, with a descriptive atlas. Philadelphia, Pa: Lippincott;1955. p. 64-9.

2. Vandamme JP, Bonte J, Van der Scheueren G. A reevaluation of hepatic and cystic arteries: The importance of aberrant hepatic branches. *ActaAnat* 1969;73:192-209.
3. Suzuki T, Nakayasu A, Kawabe K, Takeda H, Honjo I. Surgical significance of anatomic variations of the hepatic artery. *Am J Surg* 1971;122:505-12.
4. Song SY, Chung JW, Yin YH, Jae HJ, Kim HC, Jeon UB, *et al.* Celiac axis and common hepatic artery variations in 5002 patients: Systematic analysis with spiral CT and DSA. *Radiology* 2010;255:278-88.
5. Catalano OA, Singh AH, Uppot RN, Hahn PF, Ferrone CR, Sahani DV. Vascular and biliary variants in the liver: Implications for liver surgery. *RadioGraphics* 2008;28:359-78.
6. Covey AM, Brody LA, Maluccio MA, Getrajdman GI, Brown KT. Variant hepatic arterial anatomy revisited: Digital subtraction angiography performed in 600 patients. *Radiology* 2002;224:542-7.
7. Wang S, He X, Li Z, Peng Z, Tam NL, Sun C, *et al.* Characterization of the middle hepatic artery and its relevance to living donor liver transplantation. *Liver Transpl* 2010;16:736-41.
8. Tandler J. Über die Varietäten der Arteria coeliaca und deren Entwicklung. *AnatHefte* 1904;25:473-500.
9. Morita M. Reports and conception of three anomalous cases in the area of the celiac and superior mesenteric arteries [in Japanese]. *Igaku Kenkyu* 1935;9:1993-2006.
10. Nebesar RA, Kornblith PL, Pollard JJ, Michels NA. Celiac and superior mesenteric arteries: A correlation of angiograms with dissections Boston Little, Brown ; 1969.
11. Gordon DH, Martin EC, Kim YH, Kutcher R. Accessory blood supply to the liver from the dorsal pancreatic artery: an unusual anatomic variant. *Cardiovasc Radiol* 1978;1:199-201.
12. Browne EZ. Variations in origin and course of the hepatic artery and its branches. *Surgery* 1940;8:424-45.
13. Daseler EH, Anson BJ, Hambley WC, Reimann AF. The cystic artery and constituents of the hepatic pedicle: A study of 500 specimens. *Surg Gynecol Obstet* 1947;85:47-63.
14. Michels NA. Newer anatomy of the liver and its variant blood supply and collateral circulation. *Am J Surg* 1966;112:337-47.
15. Zanon C, Grosso M, Clara R, *et al.* Percutaneous implantation of arterial port-acath via trans-subclavian access. *Anticancer Res* 1999;19:5667-71.
16. Blumgart L, Fong Y. *Surgery of the liver and biliary tract*. New York, NY: Saunders; 2000. p. 1625-8.
17. Ishigami K, Zhang Y, Rayhill S, Katz D, Stolpen A. Does variant hepatic artery anatomy in a liver transplant recipient increase the risk of hepatic artery complications after transplantation? *AJR Am J Roentgenol* 2004;183:1577-84.
18. Thomas PG, Baer HU, Matthews JB, Gertsch P, Blumgart LH. Post-operative hepatic necrosis due to reduction in hepatic arterial blood flow during surgery for chronic biliary obstruction. *Dig Surg* 1990;7:31-5.

**Cite this article as:** Sureka B, Mittal MK, Mittal A, Sinha M, Bhambri NK, Thukral BB. Variations of celiac axis, common hepatic artery and its branches in 600 patients. *Indian J Radiol Imaging* 2013;23:223-33.

**Source of Support:** Nil, **Conflict of Interest:** None declared.