

Retrograde fluoroscopy-guided trans-urethral exchange of ureteral stents: Comparison of direct grasping vs. modified snare

Rosario Francesco Grasso, Eliodoro Faiella, Roberto Luigi Cazzato, Giacomo Luppi, Riccardo Del Vescovo, Francesco Giurazza, Simona Mercurio, Bruno Beomonte Zobel

Department of Radiology, University "Campus Bio-Medico di Roma", Via Alvaro del Portillo, 200 00128, Rome

Correspondence: Dr. Roberto L. Cazzato, Department of Radiology, University "Campus Bio-Medico di Roma", Via Alvaro del Portillo, 200, 00128, Rome. E-mail: r.cazzato@unicampus.it

Abstract

Background: Several different techniques including guide-wire lasso, simple snare, modified snare (MS) and direct grasping (DG), are available for retrograde ureteral stent retrieval and exchange. Choice among them is not always easy and depends on many different factors, including the local level of expertise. **Objective:** To compare the MS and DG during retrograde exchange of double-J ureteral stent under fluoroscopic guidance. **Settings and Design:** 66 patients (36 men and 30 women; mean age 66.6 years) needing retrograde ureteral stent exchange were included. All stents were previously placed through an antegrade way. **Materials and Methods:** Time needed to grasp each single stent was recorded as well as the complications. **Statistical Analysis:** Fisher's test was used to compare procedural time in both groups; $P < 0.05$ was considered significant. **Results:** 102 stents were exchanged. Mean time was 4.46 min for DG and 7.81 min for MS ($P = 0.029$). No significant complications were encountered. **Conclusions:** Compared to the MS, the DG is easier, quicker, and less expensive.

Key words: Fluoroscopy; retrograde stent exchange; stent; ureter

Introduction

Double-J-shaped ureteral stents are commonly used to maintain ureteral patency when managing malignant or benign stenosis or during ureteral wound healing.^[1] These stents can be placed in either a retrograde manner cystoscopically or in an antegrade manner through a nephrostomic access.^[2] Periodic stent exchange is necessary every 4-6 months to prevent migration, infection, and obstruction.^[3] As with placement, retrieval

can also be performed in either a retrograde or an antegrade manner, with the former being preferred because nephrostomic access is not needed. Retrograde retrieval can be performed by cystoscopic guidance^[2] or by fluoroscopic guidance,^[4] with the fluoroscopic guidance being preferred because epidural or general anesthesia is not required. Several different techniques have been described for retrograde fluoroscopy-guided ureteral stent exchange,^[5] and can generally be divided into grasping and snaring techniques.

In the present study, we compared the modified-snare (MS) technique and the direct-grasping (DG) technique during retrograde exchange of double-J ureteral stents.

Materials and Methods

The present retrospective study included 66 patients (36 men and 30 women; mean age, 66.6 years; range, 40-85 years)

Access this article online

Quick Response Code:



Website:
www.ijri.org

DOI:
10.4103/0971-3026.125615

referred to our department for retrograde exchange of double-J ureteral stents under fluoroscopic guidance, over a 12-month period. Thirty-six (54.5%) patients had bilateral stents and 30 (45.5%) had unilateral stents. A total of 102 ureteral stents were exchanged. Ureteral obstructions were a result of compression by pelvic malignancies or by their secondary lymphadenopathies: 30 male patients presented with bladder cancer, 6 male patients with prostate cancer, 6 female patients with rectal cancer, 9 female patients with ovarian cancer, and 15 female patients presented with uterine cancer and, among them, 1 presented with iatrogenic transection of the right ureter following surgical intervention. All lesions were within the distal third of the corresponding ureter. No patients with ileal conduit were included in the present study.

Conventional ureteral stents (Ureteral Stent System; Boston Scientific, Natick, MA, USA, 8 Fr × 24 cm or 8 Fr × 26 cm) were used in all cases. All stents had been previously placed via an anterograde approach through percutaneous nephrostomy sites.

Fifteen (14.7%) stents were removed in six patients because of obstruction with subsequent hydronephrosis detected during an ultrasound exam. The other 87 (85.3%) were regularly and routinely exchanged within 4-6 months after implantation.

Stents were retrieved by either the MS or DG technique, according to the discretion of the interventional radiologist performing the procedure. All the procedures were performed by three experienced interventional radiologists in the angiographic suite at our institution. Sixty-three stents (61.7%) were extracted by the MS technique and 39 stents (38.3%) by the DG technique. The time needed to grasp each ureteral stent was recorded from the moment the guide wire-snare system or the forceps were inserted to the moment the ureteral stent was externalized outside the urethral meatus.

Written informed consent was obtained from all patients before performing the procedure. The local Institutional Review Board approved this study.

Statistical analysis

Fisher's test was performed to compare the time needed to grasp the ureteral stents by the DG technique versus MS technique. $P < 0.05$ was considered significant.

Procedures

All patients had a normal coagulative status as assessed by our institution laboratory before starting the procedure. The patients were placed in a supine position, and local asepsis was obtained with povidone iodine. The patients were mildly sedated with midazolam (1-5 mg) and administered prophylactic antibiotic cefazolin (1 g). In all cases, local

anesthesia was achieved by injection of viscous lidocaine into the urethra. A 12-Fr Foley catheter was inserted into the urinary bladder to allow passage of a 0.035-inch guide wire (Radifocus, Terumo, Tokyo, Japan). A 9-Fr angiographic sheath (Radifocus, Terumo; length, 10 cm for women and 25 cm for men) was then inserted over the guide wire after removal of the Foley catheter. The urinary bladder was subsequently distended and made opaque with a solution of normal saline and contrast medium (Xenetix; Guerbet, Roissy CDG Cedex, France).

MS technique

With the inserted snare left in place, a 0.035-inch guide wire (Radifocus, Terumo, Tokyo, Japan) was inserted through the sheath and advanced in order to encircle the bladder end of the stent. Thereafter, a lasso comprising the snare and guide wire was created by passing the guide wire tip through the snare (Amplatz GooseNeck Snare Kit, 25 mm, EV3, Covidien, Plymouth, MN, USA). The lasso was then tightened around the stent [Figure 1] by jointly extracting the snare and guide wire. The stent was subsequently fixed to the tip of the sheath and removed from the urethra along with the sheath. Attention was paid to keep the renal pelvic end of the double-J ureteral stent in place within the ureter. After grasping the end of the double-J stent outside the urethra, a 0.035-inch guide wire was advanced carefully under fluoroscopic guidance into the renal pelvis through the stent. A new stent was then advanced in a retrograde direction with a pusher. When the renal pelvic end of the new stent reached the renal pelvis, the guide wire was gently extracted in order to allow recoil of the stent in the renal pelvis. The pusher was further advanced into the bladder, and then the guide wire was withdrawn until the bladder end of the stent recoiled. The proximal and distal positions of the stent were routinely confirmed by fluoroscopy after the procedure.

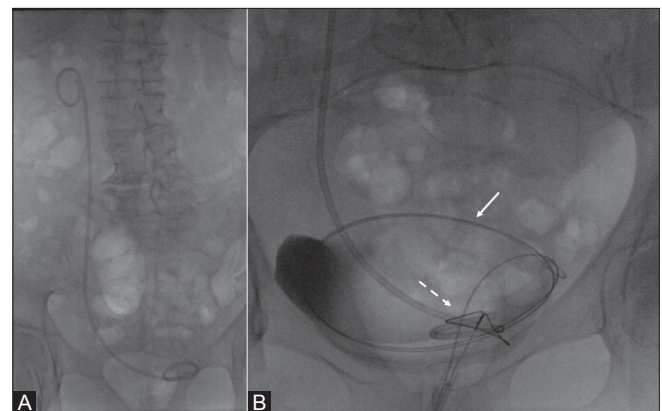


Figure 1 (A, B): Right ureteral “double-J” stent to be changed in a 79-year-old female patient affected by ovarian cancer (A). The MS technique was used; the guide wire (straight arrow) encircling the bladder end of the ureteral stent was passed through the snare (dashed arrow) in order to obtain a lasso made up of the snare and the guide wire (B)

Exchange was always performed by retrograde advancement of the guide wire through the previously externalised stent. If, however, obstruction of the stent prevented retrograde advancement of the guide wire to the renal pelvis, a sheath was advanced in a retrograde fashion around the externalized stent in order to gain access to the ureteral meatus.

DG technique

Flexible endoscopic grasping forceps (reusable rat tooth grasping forceps; working length: 700 mm; minimum working channel: 2.0 mm; opening diameter: 8.0 mm) were advanced through the sheath. The bladder end of the double-J stent was localized relative to the forceps under fluoroscopic guidance and then directly grasped. In some cases (i.e., male patients with prostate benign hyperplasia), the forceps were directed to the distal end of the stent by means of a guiding catheter (Mach1 Peripheral, 8 Fr; Boston Scientific, Natick, MA, USA). Once the stent was grasped, the sheath and the forceps were jointly extracted until the bladder end of the stent was externalized [Figure 2]. The exchange procedure was identical to that described for the MS technique.

Results

A total of 102 ureteral stents were successfully exchanged in 66 patients. All stents were successfully externalized either with the MS technique (63 stents in 42 patients, including 6 stents in three patients that were retrieved with the MS technique after DG failure) or the DG technique (39 stents in 24 patients). Fifty-one (77.3%) patients complained of mild pain in the region of the lower abdomen and urethra during the procedure, especially when the double-J stent passed the urethra. However, the pain was not severe enough to require more than mild sedation. Three patients (4.5%) presenting with an obstructed stent experienced severe pain that was managed with opioids and a self-limiting gross hematuria lasting less than 24 h, both due to calcified encrustations covering almost the entire stent. Those stents were retrieved by means of the MS technique. Other three (4.5%) patients with an obstructed stent experienced chills

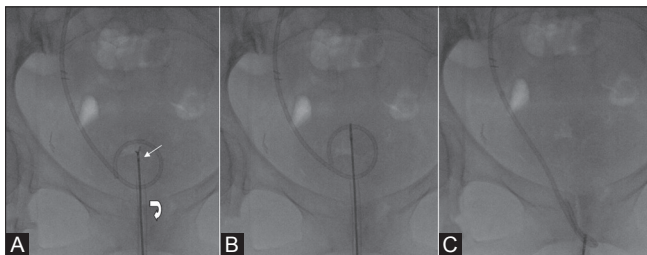


Figure 2 (A-C): Retrieval of a right ureteral double-J stent in a 62-year-old female patient presenting with ureter leakage following surgical intervention for uterine cancer. (A) Flexible endoscopic grasping forceps (arrow) were advanced through the sheath (curved arrow). (B) The position of the bladder end of the double-J stent was localized relative to the forceps under fluoroscopic guidance and then directly grasped. (C) The sheath and the forceps were jointly externalized

and fever following the procedure and required additional antibiotic therapy for 5 days. No other major complications were noted.

The mean time needed to retrieve a ureteral double-J stent was 4.46 min (range, 3-7 min) for the DG technique and 7.81 min (range, 4-12 min) for the MS technique ($P = 0.029$).

Discussion

Management of malignant ureteral strictures is a common problem in clinical practice. Although percutaneous nephrostomic tubes provide immediate relief by decompressing the hydronephrosis secondary to ureter obstruction, long-term management is difficult for the patient. Accordingly, ureteral stents are considered a desirable alternative to nephrostomies. While both plastic and metallic ureteral stents are available, plastic stents are preferred because they are not affected by the typical complications associated with metallic stents, such as epithelial hyperplasia.^[6] When correctly placed, double-J stents ensure anterograde urine flow from the renal pelvis to the bladder. Slight cranio-caudal movement of the stent, usually no more than a few millimeters, may occur, but does not compromise ureteral function. Ureteral migration, usually in the caudal direction, may, however, disrupt stent function and require replacement of the stent. Stents are routinely exchanged every 4-6 months in order to prevent encrustation, and are also exchanged when infection is suspected. Double-J ureteral stents can be placed under cystoscopic or fluoroscopic guidance, with the latter being preferred because it is less expensive^[7] and better tolerated by patients. In fact, compared to the cystoscopic technique, the fluoroscopy-assisted exchange uses more flexible and smaller-calibre instruments (i.e., 9-12 Fr vs. 18-22 Fr for the cystoscopic technique) and requires only mild sedation rather than epidural or general anesthesia.^[5] Accordingly, the fluoroscopic approach is becoming a valuable alternative to the standard cystoscopic one.

Several retrograde fluoroscopy-guided procedures have been described, with most of them aiming at snaring or grasping the bladder end of the stent. The simplest snaring method can be performed by means of a guide wire folded in two to create a lasso that is then inserted into a sheath in order to encircle the stent (guide-wire lasso).^[5] This method is inexpensive as it requires less equipment, but it cannot be applied in all cases because of the difficulties related to stent encircling. Moreover, this technique does not allow a firm grasping of the stent. Thus, several attempts may be needed to retrieve the stent, which can lengthen the procedural time.

A simple snare technique can also be applied to retrieve the ureteral stent extremity by means of a snare kit inserted into a

sheath. Once the loop of the snare is inserted into the bladder, the loop is placed around the stent extremity and tightened against a catheter advanced toward the snare. According to Park *et al.*,^[5] this technique is easy to perform, although it cannot be applied in every case, especially when the bladder stent extremity is laterally oriented or is positioned at the bottom of the bladder. We have found the simple snare technique to be valuable, but pigtailling of the large snare can impede grasping the stent extremity. The MS technique was developed to create a large snare by looping the guide wire around the stent several times. The DG technique is the only method for grasping the stent. This method is quick and easy to perform and allows a firm grip, but one of the drawbacks is unintentional snaring of the bladder mucosa.

Over a 3-year period (2010-2012) at our institution, a total of 330 patients underwent fluoroscopy-guided ureteral double-J stent positioning or exchange, with 561 ureteral prostheses positioned. The majority of these cases were performed by the MS technique, until July 2011, when the DG technique was introduced. Since then, the MS and DG techniques have been routinely applied. In our experience, among the different snare methods, the MS technique is preferable because it has a greater chance of success with fewer attempts. However, as demonstrated by the present study, the DG technique is less time-consuming compared to the MS technique (4.46 vs. 7.81 min, respectively) and easier to perform since operators handle only the forceps rather than a guide wire and goose-neck snare kit.

Complications during the DG procedure, such as grasping the bladder mucosa, are uncommon, occurring only a few times in our cases without related bleeding complications. In fact, only three cases of gross hematuria occurred in our cases, likely due to an obstructed and encrusted stent scratching the mucosa.

The main limitations of the present study include its small sample size and absence of multicenter involvement. Further studies are needed to confirm the results.

Conclusions

Compared to the MS technique, the DG technique is an easier and quicker technique for retrograde exchange of ureteral stents. In the event that the DG technique is unsuccessful, the MS technique can easily be applied.

References

1. de Baere T, Denys A, Pappas P, Challier E, Roche A. Ureteral stents: Exchange under fluoroscopic control as an effective alternative to cystoscopy. *Radiology* 1994;190:887-9.
2. Uthappa MC, Cowan NC. Retrograde or antegrade double-pigtail stent placement for malignant ureteric obstruction? *Clin Radiol* 2005;60:608-12.
3. Chew BH, Knudsen BE, Denstedt JD. The use of stents in contemporary urology. *Curr Opin Urol* 2004;14:111-5.
4. Yedlicka JW Jr, Aizpuru R, Hunter DW, Castañeda-Zúñiga WR, Amplatz K. Retrograde replacement of internal double-J ureteral stents. *AJR Am J Roentgenol* 1991;156:1007-9.
5. Park SW, Cha IH, Hong SJ, Yi JG, Jeon HJ, Park JH, *et al.* Fluoroscopy guided transurethral removal and exchange of ureteral stents in female patients: Technical notes. *J Vasc Interv Radiol* 2007;18:251-6.
6. Hekimoğlu B, Men S, Pinar A, Ozmen E, Soylyu SO, Conkbayir I, *et al.* Urothelial hyperplasia complicating use of metal stents in malignant ureteral obstruction. *Eur Radiol* 1996;6:675-81.
7. Chang RS, Liang HL, Huang JS, Wang PC, Chen MC, Lai PH, *et al.* Fluoroscopic guidance of retrograde exchange of ureteral stents in women. *AJR Am J Roentgenol* 2008;190:1665-70.

Cite this article as: Grasso RF, Faiella E, Cazzato RL, Luppi G, Vescovo RD, Giurazza F, *et al.* Retrograde fluoroscopy-guided trans-urethral exchange of ureteral stents: Comparison of direct grasping vs. modified snare. *Indian J Radiol Imaging* 2013;23:347-50.

Source of Support: Nil, **Conflict of Interest:** None declared.