

Percutaneous transhepatic portal vein stenting in a patient with benign non-transplant postoperative portal vein stenosis: A case report

KS Madhusudhan, Nikhil Agrawal¹, Deep N Srivastava, Sujoy Pal¹, Arun K Gupta

Department of Radiodiagnosis, ¹Gastrointestinal Surgery, All India Institute of Medical Sciences, Ansari Nagar, New Delhi, India

Correspondence: Dr. Deep N Srivastava, Department of Radiodiagnosis, All India Institute of Medical Sciences, Ansari Nagar, New Delhi - 110 029, India. E-mail: drdeepsrivastava@rediffmail.com

Abstract

Extrahepatic portal vein stenosis is caused by a variety of benign and malignant diseases and results in development of symptoms due to portal hypertension. Benign post-surgical adhesions causing portal vein stenosis in non-transplant population is an uncommon etiology of portal hypertension. Endovascular treatment of such patients with angioplasty and stenting is uncommonly reported in literature. We report a case of portal hypertension caused by benign postoperative portal vein fibrosis, successfully treated by self-expandable metallic stent.

Key words: Portal hypertension; portal vein stenosis; portal vein stenting

Introduction

Portal vein stenosis is caused by a number of conditions, the most common being inflammatory conditions of surrounding organs like pancreatitis, cholecystitis, and cholangitis.^[1] Other causes include involvement by pancreatic, hepatic, or biliary tumors and by fibrosis caused by previous surgery or radiotherapy.^[2,3] Stenosis of portal vein results in pre-hepatic portal hypertension leading to the development of portosystemic collaterals and intractable ascites.^[4] Endovascular management in the form of angioplasty and stenting is a well-described and feasible technique with acceptable results in patients with malignant portal vein stenosis and hepatic transplantation.^[5-7] However, little is known about the role of stenting in portal vein stenosis

caused by postoperative adhesions in non-transplant population, with only two small studies reported so far.^[8,9] We describe a case of postoperative portal vein stenosis successfully treated by percutaneous stent placement.

Case Report

A 45-year-old female patient presented to the gastrointestinal surgery out-patient department with history of pain in right hypochondrium and jaundice of 3 months duration. Ultrasonography (USG) revealed dilated intrahepatic biliary radicles (IHBR) in both lobes of liver with an ill-defined mass lesion in the region of porta hepatis. Multiphase contrast-enhanced computed tomography (CT) scan of the abdomen showed an ill-defined mass lesion involving the left hepatic duct and the primary biliary confluence with resultant dilatation of the IHBR of both lobes [Figure 1]. The mass showed delayed persistent contrast enhancement. Left branch of portal vein was completely encased by the mass with atrophy of the left lobe of liver. The main and right portal vein and the right, left, and proper hepatic arteries were normal. No abdominal lymphadenopathy was seen. The imaging diagnosis was infiltrating cholangiocarcinoma involving left hepatic duct and primary biliary confluence

Access this article online

Quick Response Code:



Website:
www.ijri.org

DOI:
10.4103/0971-3026.125622

with invasion of left portal vein. The patient was surgically treated with left hepatectomy, hepaticojejunostomy, and portal vein repair. Histopathology confirmed the diagnosis. Subsequently, the patient was treated with chemotherapy and radiotherapy.

During follow-up, the patient presented with short history of abdominal pain and distension after about 8 months of surgery. USG revealed gross ascites and Doppler study showed severely narrowed portal vein. This was followed by contrast-enhanced CT scan of the abdomen which revealed narrowing of extrahepatic portal vein at the site of repair with multiple periportal portosystemic collaterals and gross ascites. No mass lesion was seen in liver or at porta hepatis [Figure 2]. A diagnosis of postoperative benign portal vein stenosis was made and she was treated with percutaneous transhepatic balloon angioplasty of the portal vein, which showed disappearance of most of the collaterals [Figure 3]. Although the symptoms relieved initially, they recurred after 3 weeks and USG showed persistent stenosis of the extrahepatic portal vein. Since the angioplasty showed a positive outcome, percutaneous transhepatic portal vein stenting was planned. After initial balloon dilatation of the stenotic segment, a self-expandable metallic stent (Bloomington Indiana, USA), measuring 4 cm in length and 10 mm in diameter, was placed across the stenosis [Figure 4A]. Portal venography after the stenting showed disappearance of the collaterals [Figure 4B]. Patient's symptoms improved with minimal ascites

on follow-up USG after 1 month. Four months after stenting, the patient again developed moderate ascites with deranged liver functions and vomiting. USG showed ascites with coarsened liver echotexture and patent portal vein stent with normal flow. Two weeks later, the patient died of hepatic failure, which was presumed to be due to postoperative chemo-radiotherapy.

Discussion

Extrahepatic portal vein stenosis is caused by a number of benign and malignant diseases, with inflammatory and malignant conditions being responsible for most of the cases.^[1,2] Postoperative anastomotic stenosis of portal vein in liver transplant recipients is a well-known complication.^[4,10] Benign extrahepatic portal vein stenosis occurring after hepatic lobectomy is an uncommon complication.^[8,9] This may result in the development of portal hypertension and the patients may suffer from recurrent gastrointestinal bleeding and intractable ascites which affects patient's quality of life.^[4] Surgical treatment of portal vein stenosis is often difficult and depends on the etiology. Surgery is limited due to the presence of adhesions at the site of surgery, by the length of involved segment of portal vein, and increased risk of complications of second surgery.^[9,10]

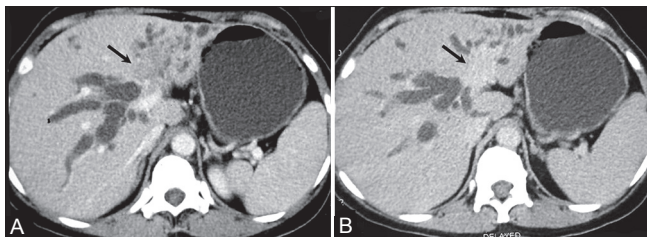


Figure 1 (A, B): Axial contrast-enhanced CT scan in venous (A) and delayed (B) phases showing hypodense mass lesion (arrow) involving primary biliary confluence and left hepatic duct with atrophy of left lobe of liver and involvement of portal vein. Note the delayed enhancement of the mass (B)

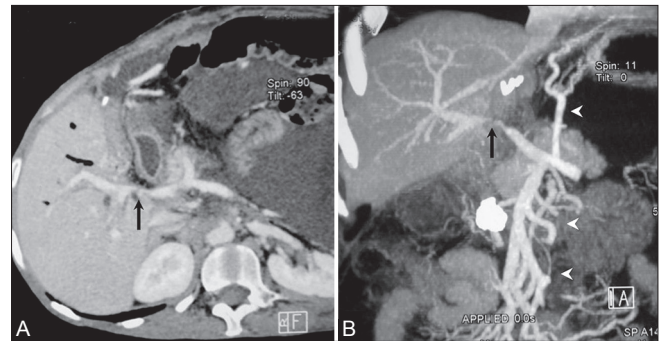


Figure 2 (A, B): (A) Curved reconstruction of CT scan showing short segment narrowing of main portal vein (arrow) without residual or recurrent mass. Ascites is also noted. (B) Maximum intensity projection image showing the stenosis (arrow) with multiple collaterals (arrow heads)

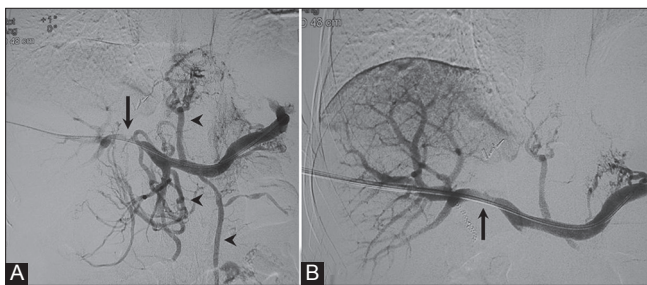

Figure 3 (A, B): (A) Transhepatic portal venogram showing stenosis of main portal vein (arrow) with multiple collaterals (arrow heads). (B) Venogram after balloon venoplasty showing near-normal caliber at the site of stenosis (arrow) with reduction of collaterals

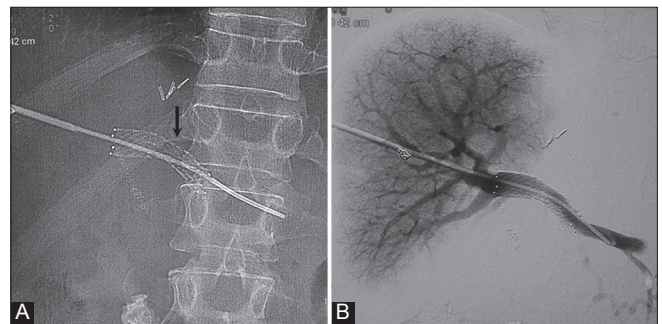


Figure 4 (A, B): (A) Showing metallic portal vein stent (arrow) with catheter *in situ*. (B) Venogram after stent placement showing normal caliber of portal vein and complete disappearance of collaterals

Percutaneous transhepatic angioplasty and/or stenting is a viable treatment option for patients with symptomatic portal vein stenosis.^[9] The treatment is less invasive and palliative in patients with malignant etiology. Self-expandable metallic stents (10-14 mm diameter) are most commonly used in relieving portal vein stenosis.^[9] The length of the stent varies from 4 to 8 cm, depending on the length of stenosis. Balloon dilatation of the stent should be performed if narrowing persists after deployment. The success and patency rates of the stents varied from 79 to 100% in inflammatory and malignant causes.^[2,5] In transplant patients, the patency rates are about 91%.^[11]

There is very limited literature on the role of angioplasty and stenting in patients with portal hypertension due to non-transplant postoperative benign extrahepatic portal vein stenosis. Kim *et al.* found patency period of 30.1 ± 25.6 months in their 11 patients with postoperative benign portal vein stenosis compared to 7.3 ± 7.7 months in patients with recurrent tumor.^[9] They found major complications in three patients, including liver abscess, septicemia and acute portal vein thrombosis.^[9] No complications were seen by Woodrum *et al.* in their cases. In our case, the procedure itself was without complications. The stent was patent till the patient survived and relieved intractable ascites.

In conclusion, benign postoperative portal vein stenosis may result in uncontrollable and symptomatic portal hypertension. Percutaneous stenting is an excellent, safe, and effective option in the management of such patients.

References

1. Cohen J, Edelman RR, Chopra S. Portal vein thrombosis: A review. *Am J Med* 1992;92:173-82.
2. Yamakado K, Nakatsuka A, Tanaka N, Fujii A, Isaji S, Kawarada Y, *et al.* Portal venous stent placement in patients with pancreatic and biliary neoplasms invading portal veins and causing portal hypertension: Initial experience. *Radiology* 2001;220:150-6.
3. Mitsunaga S, Kinoshita T, Kawashima M, Konishi M, Nakagohri T, Takahashi S, *et al.* Extrahepatic portal vein occlusion without recurrence after pancreaticoduodenectomy and intraoperative radiation therapy. *Int J Radiat Oncol Biol Phys* 2006;64:730-5.
4. Shan H, Xiao XS, Huang MS, Ouyang Q, Jiang ZB. Portal venous stent placement for treatment of portal hypertension caused by benign main portal vein stenosis. *World J Gastroenterol* 2005;11:3315-8.
5. Novellas S, Denys A, Bize P, Brunner P, Motamedi JP, Gugenheim J, *et al.* Palliative portal vein stent placement in malignang and symptomatic extrinsic portal vein stenosis or occlusion. *Cardiovasc Intervent Radiol* 2009;32:462-70.
6. Tsukamoto T, Hirohashi K, Kubo S, Tanaka H, Hamba H, Shuto T, *et al.* Percutaneous transhepatic metallic stent placement for malignant portal vein stenosis. *Hepatogastroenterology* 2003;50:453-5.
7. Wei BJ, Zhai RY, Wang JF, Dai DK, Yu P. Percutaneous portal venoplasty and stenting for anastomotic stenosis after liver transplantation. *World J Gastroenterol* 2009;15:1880-5.
8. Woodrum DA, Bjarnason H, Andrews JC. Portal vein venoplasty and stent placement in the nontransplant population. *J Vasc Interv Radiol* 2009;20:593-9.
9. Kim KR, Ko GY, Sung KB, Yoon HK. Percutaneous transhepatic stent placement in the management of portal venous stenosis after curative surgery for pancreatic and biliary neoplasms. *Am J Roentgenol* 2011;196:W446-50.
10. Woo DH, Laberge JM, Gordon RL, Wilson MW, Kerlan RK Jr. Management of portal venous complications after liver transplantation. *Tech Vasc Interv Radiol* 2007;10:233-9.
11. Cheng YF, Ou HY, Tsang LL, Yu CY, Huang TL, Chen TY, *et al.* Vascular stents in the management of portal venous complications in living donor liver transplantation. *Am J Transplant* 2010;10:1276-83.

Cite this article as: Madhusudhan K, Agrawal N, Srivastava DN, Pal S, Gupta AK. Percutaneous transhepatic portal vein stenting in a patient with benign non-transplant postoperative portal vein stenosis: A case report. *Indian J Radiol Imaging* 2013;23:351-3.

Source of Support: Nil, **Conflict of Interest:** None declared.