

Intercostal artery pseudoaneurysm complicating corrosive acid poisoning: Diagnosis with CT and treatment with transarterial embolisation

MV Chalapathi Rao, Abhishek A Rathi, Sharath P Reddy¹, Sambit Sahu²

Department of Radio-diagnosis, ¹Department of Gastroenterology, ²Department of Critical Care, Krishna Institute of Medical Sciences, Secunderabad, Andhra Pradesh, India

Correspondence: Dr. MV Chalapathi Rao, Department of Radiodiagnosis, Krishna Institute of Medical Sciences, Minister Road, Secunderabad, Andhra Pradesh - 500 003, India. E-mail: chalapati_m@yahoo.com

Abstract

Pseudoaneurysms of intercostal artery are very rare. All the published cases have been caused by trauma, either iatrogenic or otherwise. They can cause hemothorax, retroperitoneal hemorrhage or can present as pulsatile chest mass. Doppler ultrasound, contrast-enhanced CT and conventional angiogram can accurately diagnose this condition. All the reported cases have been treated by embolisation, stenting or surgery. We report an unusual case of intercostal artery pseudoaneurysm arising as a complication of corrosive poisoning presenting with hematemesis and treated by glue embolisation. The authors believe this to be the first case of intercostal artery pseudoaneurysm that is non-traumatic, complicating corrosive poisoning and presenting with hematemesis.

Key words: Corrosive poisoning; hematemesis; intercostal artery pseudoaneurysm; N-butyl cyanoacrylate

Introduction

Intercostal artery pseudoaneurysm is an extremely rare phenomenon with only a few cases described so far. Trauma, surgery and intervention procedures are the reported causes. We describe a case of corrosive poisoning induced intercostal artery pseudoaneurysm, presenting with massive hematemesis and shock which was treated by glue embolisation. To the author's belief and to the best of their knowledge, this is the first reported case of non-traumatic intercostal artery pseudoaneurysm caused by acid ingestion and presenting with hematemesis.

Case Report

A 32 year old male with history of suicidal intent corrosive acid consumption, 5 weeks ago, was referred to our hospital with complaint of massive hematemesis. The patient initially presented, 4 weeks after corrosive consumption, to another hospital with two episodes of massive hematemesis where the patient was managed conservatively with blood transfusion. An upper gastrointestinal endoscopy revealed Grade 3 corrosive injury involving esophagus, gastroesophageal junction and stomach.

At the time of admission, patient was pale with pulse rate of 98/min and blood pressure of 90/58 mm of Hg. Laboratory investigations revealed haemoglobin level of 6.3 g/dl, RBC count of 2.03 millions/mm³ and 1.32 INR. CT angiogram was performed to delineate the exact cause and site of bleed which revealed hematoma in and around the upper thoracic oesophagus on non-contrast enhanced scan [Figure 1]. On contrast-enhanced study, a small

Access this article online

Quick Response Code:



Website:
www.ijri.org

DOI:
10.4103/0971-3026.134397

pseudoaneurysm of right third intercostal artery, posterior to thoracic esophagus at level of D4-D5 intervertebral disc was noticed [Figure 2]. Patient's condition deteriorated due to continuous ongoing hematemesis. His blood pressure dropped to 60/35 mm of Hg, haemoglobin level to 3.1 g/dl. Multiple units of fresh frozen plasma, blood and intravenous fluids were administered and patient was taken for emergency embolisation of pseudoaneurysm. Selective cannulation of right third intercostal artery via right femoral artery puncture was performed with a 4 Fr Cobra catheter. Initial angiogram showed pseudoaneurysm with active leak [Figure 3]. Pseudoaneurysm was cannulated with 0.017" Headway microcatheter (MicroVention) with the help of 0.014" micro guide wire. 0.5ml of N-butyl cyanoacrylate (NBCA)

glue (Histoacryl) was thoroughly mixed with 2 ml of Lipiodol (Guerbet) to make 20% NBCA solution. About 1.0 ml of this solution was carefully injected under guidance in the right third intercostal artery after flushing the microcatheter with 5% dextrose solution, checking that there was no reflux into non-target vessels [Figure 4]. There was extravasation of glue-lipiodol mixture into the intercostal space due to active leak. Check angiogram revealed complete exclusion of the pseudoaneurysm from circulation [Figure 5].

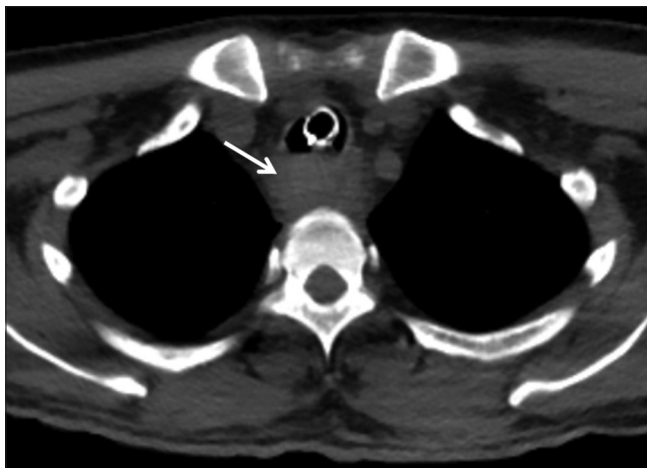


Figure 1: Axial non-enhanced CT chest showing hyperdense hematoma in and around the esophagus (arrow)

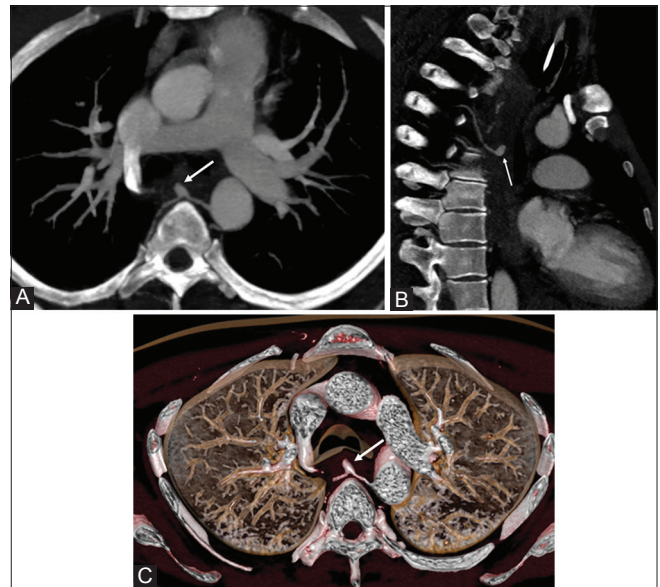


Figure 2: Reconstructed CT angiogram maximum intensity projection image showing the right 3rd intercostal artery pseudoaneurysm (arrow) (A) axial (B) swirled lateral (C) 3D reconstructed

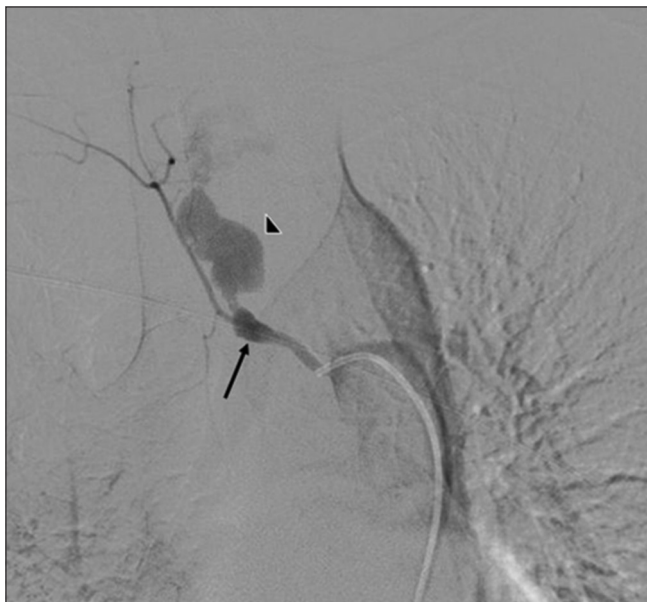


Figure 3: Selective right intercostal artery DSA using road-map technique shows the pseudoaneurysm (arrow) with active contrast leak (arrowheads)

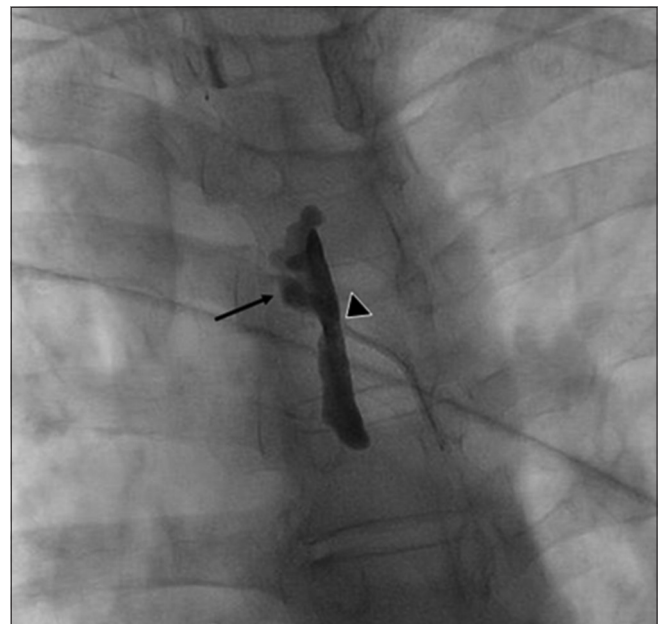


Figure 4: Image showing radio-opaque glue in the pseudoaneurysm (arrow) with micro-catheter in situ (arrowhead). Note local peri-aneurysmal glue leak

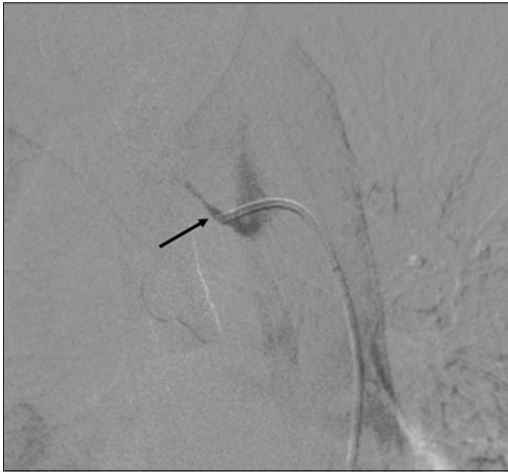

Figure 5: Post-embolisation check angiogram showing complete cut-off of the aneurysm from circulation (arrow)

The patient's hematemesis stopped immediately after the procedure and after active resuscitation, his vital parameters became stable. Hemoglobin was 9.3 g/dl on the next day of the procedure with no fresh episode of hematemesis. The patient was discharged in stable condition two days after the procedure.

Discussion

Pseudoaneurysm of intercostal artery is extremely rare. To the author's knowledge, only 9 cases have been reported in English literature.^[1-9] Etiology described in all the published cases was trauma, either iatrogenic or otherwise and the presentation was in the form of hemothorax, retroperitoneal hematoma or pulsatile swelling.^[1-10]

This was a complicated case because of massive hematemesis, continuous on-going blood loss and circulatory shock. Timely and successful embolisation proved life saving in our patient.

Doppler ultrasound, CT angiography and Digital subtraction angiography (DSA) are the investigations commonly used to diagnose pseudoaneurysm. Accurate diagnosis of aneurysm can be achieved by utilising the multi-planar reformation (MPR) and Maximum intensity projection (MIP) feature of CT. DSA is not only diagnostic but also has the advantage of endovascular treatment in the same setting.

Coil embolisation, glue embolisation, thrombin injection and surgery are the various treatment options available. Stenting of non-bleeding pseudoaneurysm and conservative management of asymptomatic cases has also been described.^[2,4,6] Surgical treatment is usually reserved for failed embolisation or where embolisation could not be accomplished.^[5] The choice of embolic material in vascular interventional procedures depends

on anatomy, pathology, flow characteristics and personal preference of the interventional radiologist. The main advantage of NBCA is that it is capable of conforming within the vessel and occludes the vessel lumen rapidly besides being cheap. Lipiodol is mixed with NBCA to make it radio-opaque and to dilute it so as to delay its time of polymerisation.^[10,11] NBCA quickly solidifies by exothermic reaction when it comes in contact with an ionic solution of alkaline pH such as blood. To prevent early solidification within the delivery system itself, the catheter is primed with low pH non-ionic 5% dextrose solution prior to injection of glue bolus.

Spinal cord ischemia, a serious complication which can arise due to embolisation needs special mention. Detailed knowledge of spinal cord blood supply, anatomy of radiculo-medullary arteries, the artery of Adamkiewicz and expertise of interventional radiologist are the determining factors of outcome of embolisation procedure.

Esophageal and gastric burns, perforation, mediastinitis, early fatal outcome, esophageal and pyloric stenosis and carcinoma formation are the various complications of corrosive ingestion.^[12] This case emphasizes the consideration of pseudoaneurysm, as a possible complication of corrosive poisoning, in patients presenting with hematemesis.

Conclusion

Pseudoaneurysm of intercostal artery can cause massive rapid blood loss and can be life threatening. Clinical suspicion, accurate diagnosis and early timely intervention can be lifesaving in such a situation.

References

1. Sekino S, Takagi H, Kubota H, Kato T, Matsuno Y, Umemoto T. Intercostal artery pseudoaneurysm due to stab wound. *J Vasc Surg* 2005;42:352-6.
2. Callaway MP, Wilde P, Angelini G. Treatment of a false aneurysm of an intercostal artery using a covered intracoronary stent-graft and a radial artery puncture. *Br J Radiol* 2000;73:1317-9.
3. Casas JD, Perendreu J, Gallart A, Muchart J. Intercostal artery pseudoaneurysm after a percutaneous biliary procedure: Diagnosis with CT and treatment with transarterial embolization. *J Comput Assist Tomogr* 1997;21:729-30.
4. Atherton WG, Morgan WE. False aneurysm of an intercostal artery after thoracoscopic sympathectomy. *Ann R Coll Surg Engl* 1997;79:229-30.
5. Aoki T, Okada A, Tsuchida M, Hayashi J. Ruptured intercostal artery pseudoaneurysm after blunt thoracic trauma. *Thorac Cardiovasc Surg* 2003;51:346-7.
6. Bluebond-Langner R, Pinto PA, Kim FJ, Hsu T, Jarrett TW. Recurrent bleeding from intercostal arterial pseudoaneurysm after retroperitoneal laparoscopic radical nephrectomy. *Urology* 2002;60:1111.
7. Yamakado K, Nakatsuka A, Tanaka N, Takano K, Matsumura K, Takeda K. Transcatheter arterial embolization of ruptured

- pseudoaneurysms with coils and n-butyl cyanoacrylate. *J Vasc Interv Radiol* 2000;11:66-72.
8. Melloni G, Bandiera A, Crespi G, Zannini P. Intercostal artery pseudoaneurysm after computed tomography-guided percutaneous fine needle aspiration lung biopsy. *J Thorac Imaging* 2012;27:W48-9.
 9. Kawai H, Ito M. Intercostal artery pseudoaneurysm after thoracoscopic lung resection. *Gen Thorac Cardiovasc Surg* 2009;57:550-2.
 10. Kim J, Shin JH, Yoon HK, Ko GY, Gwon DI, Kim EY, *et al.* Transcatheter renal artery embolization with N-butyl cyanoacrylate. *Acta Radiol* 2012;53:415-21.
 11. Monsignore LM, Scarpelini S, Santos JS, Abud DG. Urgent percutaneous transcatheter embolization of hemorrhagic hepatic lesions with N-butyl cyanoacrylate. *Diagn Interv Radiol* 2012;18:403-9.
 12. Ramasamy K, Gumaste VV. Corrosive ingestion in adults. *J Clin Gastroenterol* 2003;37:119-24.

Cite this article as: Chalapathi Rao MV, Rathi AA, Reddy SP, Sahu S. Intercostal artery pseudoaneurysm complicating corrosive acid poisoning: Diagnosis with CT and treatment with transarterial embolisation. *Indian J Radiol Imaging* 2014;24:135-8.

Source of Support: Nil, **Conflict of Interest:** None declared.