

Fetal gastric pseudomass at 30 weeks of gestation and its regression after 17 days of birth

Karippaliyil Balakumar, Kannan Misha, Karippaliyil Milind

Department of Ultrasonography, Balku's Scan Centre, PVS Hospital, Calicut 2, Kerala, India

Correspondence: Dr. Balakumar K, Balku's Scan Centre, PVS Hospital, Calicut 2, Kerala - 673 002, India. E-mail: balakumar_k@dataone.in

Abstract

Second trimester fetal ultrasonography (USG) occasionally reveals an echogenic intragastric mass. These masses are usually small due to the organized debris from swallowed amniotic fluid, and they normally disappear in the third trimester. This report shows a fetal intragastric echogenic mass detected at 30 weeks of gestation that persisted as a large heterogeneously echoic mass even on the 10th day after birth. The immediate postnatal USG features were consistent with the possibility of an intragastric soft tissue mass, though abdominal radiographs and computed tomography (CT) with oral contrast were non-specific. The baby remained asymptomatic in the neonatal period and USG scanning again after a week showed normal stomach and other intra-abdominal visceral echoes.

Key words: Fetal anomaly; fetal gastric pseudomass; fetal gastrointestinal anomalies

Introduction

Fetal USG in the late trimesters occasionally shows intra-gastric echogenic shadows which is an innocent finding usually disappearing by late third trimester. The fetus illustrated here had an intragastric echogenic mass of significant size.

The case presented here is unique due to the fact that the fetal intragastric mass persisted throughout the second and third trimesters and it disappeared after 17 days of birth.

Case Report

A primigravida of 30 weeks gestation was referred for routine USG for assessing fetal growth. The mother had no contributory history or any abnormal clinical finding.

On scanning (using Aloka 5000 machine, 2.75-5 MHz, HD probe), the fetal growth and biophysical parameters were normal. The fetal abdomen showed a slightly irregular, moderate-level echoic shadow within the gastric bubble, measuring 32 × 20 mm [Figure 1]. There was no calcification within the mass or at the periphery. The gastric walls were smooth and intact. Reassessment after an hour showed the same finding with no change in position or shape of the mass. There was no demonstrable blood flow within the mass on color Doppler. The fetus was rescanned at 34 weeks and at 38 weeks of gestation. The echoic shadow persisted inside the stomach bubble with no other abnormal findings. The intragastric mass measured 35 × 22 mm at 34 weeks and 39 × 28 mm at 38 weeks of gestation. She delivered a full-term healthy baby, who remained asymptomatic in the immediate postnatal period. The baby was breastfed as there was no vomiting or visible gastric peristalsis. The bowel opening was normal. The baby was scanned on the 10th day after birth for verifying the antenatal USG finding. The slightly irregular, moderate-level echoic gastric mass measured 40 × 35 mm at this time [Figures 2A and B]. The mass showed no free movement inside the non-distended stomach nor could be displaced away from the gastric wall. A thin speck of very low velocity color flow was demonstrable at the periphery [Figure 3]. The plain radiograph of abdomen and oral contrast study of

Access this article online

Quick Response Code:



Website:
www.ijri.org

DOI:
10.4103/0971-3026.134403

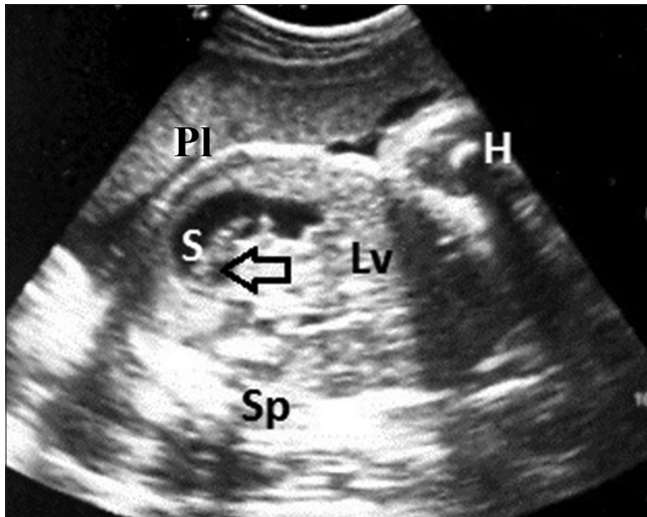


Figure 1: Fetal abdominal USG at 30 weeks of gestation: A slightly oblique USG scan of the fetal abdomen at 30 weeks of gestation shows an irregular (arrow) intragastric echogenic shadow (S: Stomach, H: Cross-sectional view of the humerus, PI: Placenta, Sp: Spine, Lv: Liver)

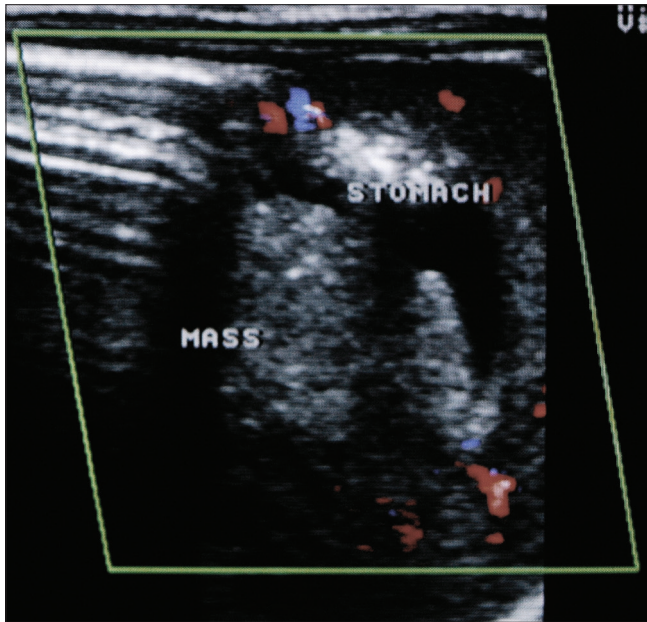


Figure 3: Neonatal abdominal scan on 10th day after birth: The intragastric mass shows very low velocity color flow at the periphery (which may be an artifact at very sensitive color flow setting)

stomach [Figure 4] did not contribute a definite diagnosis. Computed tomography (CT) of abdomen with oral contrast showed a filling defect of fluid density with an attenuation of 10 to 20 HU within the stomach [Figure 5]. The baby remained asymptomatic, and on follow-up, the intragastric echogenic mass gradually disappeared within a week.

Discussion

Fetal gastric echogenic shadow mimicking a mass is an occasional finding during a second trimester USG. The reported incidence of this finding is 1 in 300 second

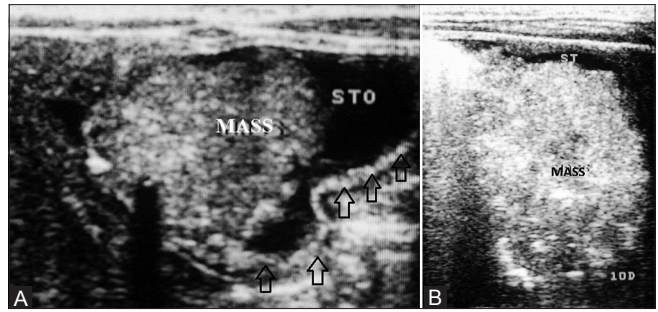


Figure 2 (A, B): Neonatal abdominal scan on 10th day after birth: The upper abdominal scan of the neonate (on 10th day after birth) shows an heterogeneously echoic mass inside the stomach (STO, ST). Part of the stomach wall is well-delineated (arrows)

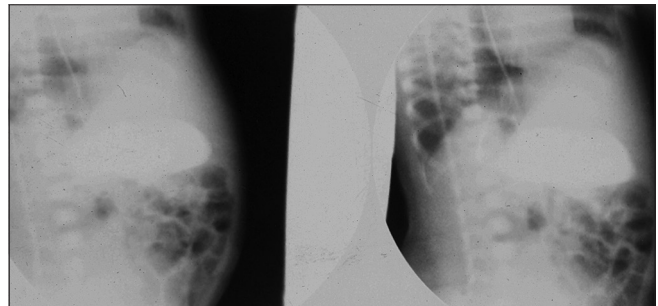


Figure 4: Neonatal abdominal radiograph with oral contrast: The radiograph of the abdomen with oral contrast showed no definite mass lesion

trimester scans.^[1] The swallowed vernix in the stomach comprising the cells shed from fetal skin, urinary epithelium, and umbilical cord leads to the formation of a pseudomass. Subchorionic hemorrhage reaching the amniotic cavity can also contribute to formation of a gastric pseudomass because of the swallowed blood. Similarly, placental abruption or amniocentesis can produce a similar mass due to the same mechanism.^[2,3] These intragastric components conglomerate and appear like a mass within the stomach bubble termed as “pseudomass.” These gastric masses usually measure 4-12 mm in size.^[4] This fetus had a fairly large heterogeneously echoic mass which persisted throughout the late trimester and in the early neonatal period. The mass measuring 40 × 35 mm could not be displaced away from the gastric wall, probably due to its proximity to the stomach wall. The very low velocity color flow at the periphery of the mass could have been an artifact caused by the movement of intervening fluid layer. The presence of a “gastric pseudomass” is not a serious concern as it usually disappears in due course of time when the gastric peristalsis becomes more effective in the third trimester.^[4-6] This case illustrates the fact that the gastric pseudomass can be even larger and can persist for few days after birth. The complete regression was evident by 17 days after birth.

The differential diagnoses of fetal intragastric mass are limited. An endogastric teratoma may present as

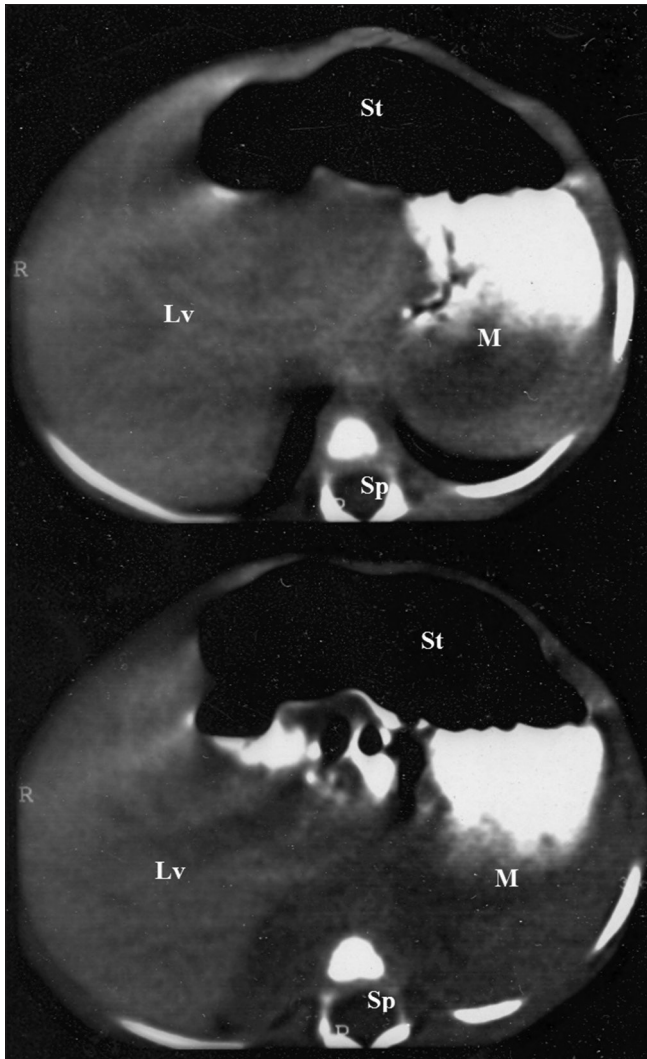


Figure 5: Neonatal abdominal CT with oral contrast: The abdominal CT with oral contrast shows a filling defect of 10 to 20 HU within the stomach (St: Stomach, Lv: Liver, M: Mass, Sp: Spine)

a solid mass inside the stomach.^[7] However, upper abdominal masses contiguous with stomach wall include

the differential diagnoses of teratoma, neuroblastoma, nephroblastoma, and pancreatoblastoma.^[8]

Conclusion

This case illustrates the atypical presentation of fetal gastric mass in the third trimester which persisted as a large mass even after 10 days of birth. All imaging modalities suggested the possibility of a gastric pseudomass proven by its gradual complete resolution by 17 days after birth.

References

1. Nyberg DA, Mack LA, Patten RM, Cyr DR. Fetal bowel. Normal ultrasonographic findings. *J Ultrasound Med* 1987;6:3-6.
2. Walker JM, Ferguson DD. The sonographic appearance of blood in the fetal stomach and its association with placental abruption. *J Ultrasound Med* 1988;7:155-61.
3. Daly-Jones E, Sepulveda W, Hollingsworth J, Fisk NM. Fetal intraluminal gastric masses after second trimester amniocentesis. *J Ultrasound Med* 1994;13:963-6.
4. Fakhry J, Shapiro LR, Schecter A, Weingarten M, Glennon A. Fetal gastric pseudomasses. *J Ultrasound Med* 1987;6:177-80.
5. Sase M, Nakata M, Tashima R, Kato H. Development of gastric emptying in the human fetus. *Ultrasound Obstet Gynecol* 2000;16:56-9.
6. McNamara A, Levine D. Intraabdominal fetal echogenic masses: A practical guide to diagnosis and management. *Radiographics* 2005;25:633-45.
7. Gamanagatti S, Kandpal H. Gastric teratoma. *Singapore Med J* 2007;48:e99-101.
8. Akram M, Ravikumar N, Azam M, Corbally M, Morrison JJ. Prenatal findings and neonatal immature gastric teratoma. *BMJ Case Rep* 2009;bcr10.2008.1050.

Cite this article as: Karippaliyil B, Kannan M, Karippaliyil M. Fetal gastric pseudomass at 30 weeks of gestation and its regression after 17 days of birth. *Indian J Radiol Imaging* 2014;24:160-2.

Source of Support: Nil, **Conflict of Interest:** None declared.