

Stretched bowel sign in combined transmesocolic and transomental internal hernia: A case report and review of literature

Nischal G Kunderagi, Shanmugam Vinayagam, Srinivasa Mudali

Department of Radiology, SRM University Medical College and Hospital, Chennai, Tamil Nadu, India

Correspondence: Dr. Nischal G Kunderagi, Department of Radiology, SRM University Medical College and Hospital, Chennai, Tamil Nadu, India.
E-mail: drngk@yahoo.com

Abstract

Transomental and transmesenteric hernias are rare types of internal hernia, with a reported frequency of upto 4% and 8%, respectively. Combined transomental and transmesocolic hernia is even rare. Only in a few types of internal hernia, the dilated small bowel loops will be seen extending from the antero-superior aspect of the distal stomach and cause stretching effect over the adjacent bowel loops with increase in the size of the herniated bowel segment or intestinal obstruction. We report a rare case of idiopathic combined transomental (across the lesser omentum) and transmesocolic internal hernia with “stretched bowel sign,” its diagrammatic representations, and review of literature.

Key words: Internal hernia; non-contrast enhanced computed tomography study; stretched bowel; transmesocolic; transomental

Introduction

Combined transomental and transmesocolic hernia is a rare type of transmesenteric internal hernia. These types of internal hernias are difficult to diagnose on imaging modalities, as herniated small bowel loops are non-clustered and non-encapsulated. We report a rare case of idiopathic combined transomental and transmesocolic internal hernia with its imaging features, diagrammatic representations and review of literature. “Stretched bowel sign” (i.e., stomach and large bowel were stretched down by the herniating small bowel loops through the mesentery) can be used as an important clue to diagnose this type of internal hernia on cross sectional imaging, along with features of intestinal

obstruction (non-clustered, non-encapsulated dilated small bowel loops). This sign can also be used in diagnosing the double omental hernia.

Case Report

A 55 year old male patient presented to emergency department with a history of sudden-onset vomiting, vague abdominal pain, and increasing abdominal distension. Patient was known to have chronic renal disease for 5 years prior to presentation. No history of prior abdominal surgeries was noted. On examination, the abdomen was soft and non-tender. A radiograph of the abdomen obtained in an erect position showed few central air-fluid levels suggesting the presence of small bowel obstruction. Then a gastric tube was seen vertically extending into the left lower lumbar region. USG of the abdomen revealed dilated stomach extending below the level of the umbilicus and a few dilated hyperperistaltic small bowel loops. There was wall thickening involving the distal stomach. Mild ascites was present. In view of chronic renal disease, a non-contrast enhanced computed tomography (CT) scan of the abdomen was performed

Access this article online

Quick Response Code:



Website:
www.ijri.org

DOI:
10.4103/0971-3026.134407

which showed non-clustered, non-encapsulated dilated small bowel loops predominantly in the lower abdomen with large stretched stomach. Transverse colon was seen below the level of the stomach in the upper pelvis and the small bowel loops were seen ventral to the transverse colon. An internal hernia, probably of transmesocolic transomental type, causing small bowel obstruction with stretching of stomach and transverse colon was suspected. However, clear segmental differentiation of the small bowel was not made out. Thus, another CT scan with oral contrast material was performed. Stomach and proximal jejunal loops were opacified with oral contrast; however, distal jejunal and ileal loops were not opacified even on delayed scan images (6 hours). Dilated small bowel loops were seen predominantly right antero-lateral and inferior to the stomach and transverse colon. Afferent and efferent small bowel loops with beaking were seen clearly just above the antral part of the stomach [Figures 1A-C]. Mild distal stomach wall thickening was again noted. These findings suggested the presence of a transomental (lesser omentum) and transmesocolic internal hernia.

The patient subsequently underwent open laparotomy. A loop of non-ischemic dilated small bowel was seen herniating through the defects in the transverse mesocolon (5.0 cm) and the lesser omentum (gastrohepatic ligament, about 4.0 cm) into the peritoneum. Stomach and transverse colon were stretched down by the herniated small bowel loops [Figure 2]. Small bowel loops were repositioned and the defects were closed.

Postoperatively, the patient was followed up with USG, and he has been doing well for more than 10 months.

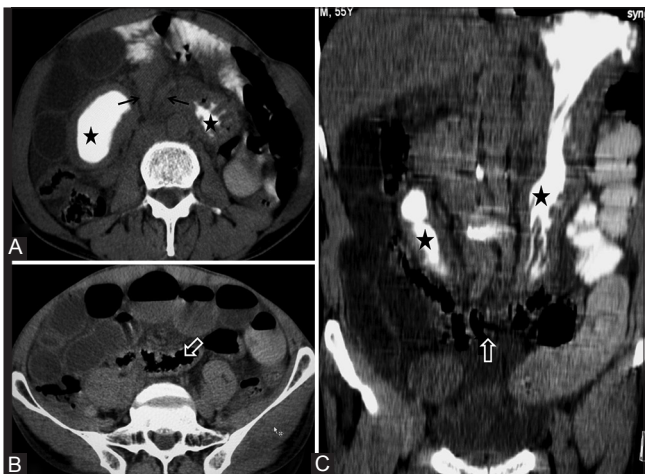


Figure 1 (A-C): CT scan axial and oblique coronal images show elongated and stretched down stomach (star-shaped markers) and transverse colon (white open arrow) with two collapsed small bowel loops with beaking (black arrows in A) seen antero-superior to the antral part of the stomach. Dilated small bowel loops are seen right lateral and inferior to the stomach and the transverse colon. Mild free fluid in between the bowel loops and mild distal stomach wall thickening (congestive edema) are also noted

Discussion

Transmesenteric hernia occurs when a loop of intestine protrudes through a defect in the intestinal mesentery or omentum. Similar to many other internal hernias, there is no true peritoneal sac.

The reported frequencies of transomental and transmesenteric hernias are about 4% and 8%, respectively.^[1] Combined transomental and transmesocolic hernia is even rare.^[2]

Transmesenteric hernia comprises approximately 5-10% of all internal hernias. These hernias are the most common type of internal hernia in pediatric population and account for 35% of all internal hernias. Mesenteric defects have an association with intestinal ischemic accidents and have an increased incidence in infants with intestinal atresia. Small bowel mesenteric defects were found in 71% all transmesenteric hernias, with ileo-cecal defects accounting for 54% of these occurrences.^[3] Mesocolic defects were found in 26%, with transmesocolic defects making up 59% of these variants.^[3]

A second peak of transmesenteric hernia is seen in the adult population and can be iatrogenic or related to prior abdominal surgery, especially with Roux-en-Y anastomosis, trauma, or inflammation. Three main types of transmesenteric internal hernias are seen which are as follows:

- The most common type is the transmesocolic, which has been documented to occur in 0.7-3.25% of patients after laparoscopic Roux-en-Y gastric bypass surgery^[4]
- Hernia through a defect in the small bowel mesentery
- Peterson type, which involves herniation of small bowel behind the Roux loop before the small bowel eventually passes through the defect in the transverse mesocolon.

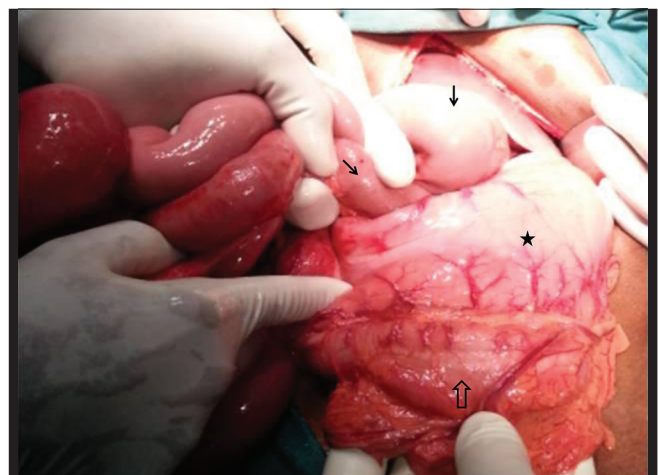


Figure 2: Intraoperative image showing herniated small bowel loops (black arrows) seen entering the peritoneal cavity from the superior aspect of the antrum of the stomach (star-shaped marker). Transverse colon is seen just below the stomach (open arrow)

Depending on the type of transmesenteric hernia and the segment and length of the herniated bowel, imaging appearances may vary. Transmesocolic hernia on oral contrast studies and CT may show a beaked appearance of both the afferent and efferent loops and the resultant mass effect on the stomach and transverse colon. These findings may simulate a left paraduodenal hernia or can be mistaken for a concomitant occurrence of small-bowel volvulus and closed loop obstruction,^[4] but are almost always clustered and encapsulated. In our case, the stomach and transverse colon were stretched down by the non-clustered, non-encapsulated herniating small bowel loops.

Defect in the transverse mesocolon may provide access for internal herniation of small bowel loops posterior to the transverse colon into the lesser sac. Usually the orifice will be very large with an avascular space in the base of the mesocolon. Many loops may herniate without strangulation, gangrene, or even significant obstruction. Re-entry into the greater peritoneal cavity is frequent via the routes of the foramen of Winslow, the gastrohepatic ligament, and the gastrocolic ligament.^[5] In our case, we found herniation of small bowel loops through the transverse mesocolon and gastrohepatic ligament back into the peritoneal cavity with significant small bowel obstruction.

Transomental hernia accounts for approximately 1-4%^[1,5] of the internal hernias. Most occur on the right side of the greater omentum without a sac and are always intraperitoneal. The clinical and radiological findings are almost identical to those of transmesenteric hernias.^[5]

Chou *et al.*^[2] described the CT findings of their case on contrast study (oral and IV) as an unusual course of mesenteric vessels and unusual location of the small bowel. The proximal small bowel loops were in the right upper quadrant at a level cephalad to the hepatic flexure of the

colon and ventral to the transverse colon. Stretched lower gastric body was also noted. In our case, dilated proximal small bowel loops were seen in the mid abdomen on the right side, caudal to the hepatic flexure and ventral to the transverse colon. Stomach was stretched down [Figures 1 and 3].

Herniation of small bowel loops through the defect in the transverse mesocolon and gastrocolic ligament^[2,5] can also cause mass effect with stretching of transverse colon and non-clustered, non-encapsulated dilated small bowel loops.

Double omental hernia^[6,7] probably may not cause stretching of transverse colon as the small bowel loops will pass ventral and superior to the transverse colon into the lesser sac and then prolapse into the peritoneal cavity through the defect in the lesser omentum [Figure 4]. Prolapsed small bowel loops will be seen extending from the antero-superior aspect of the distal stomach. Pressure effects over the stomach can be seen with increasing herniating bowel segment or obstruction as compared to our case ("stretched bowel sign"). Also, it can be diagnosed on CT scan either by mesenteric vascular reorientation or by abnormal small bowel position. However, transverse colon may be seen in normal position and without pressure effects. Double omental hernia may present as painful tender epigastric lump with strangulation.^[7]

In the classification of transomental hernias given by Takeyama *et al.*,^[1] herniation through the free greater omentum and into the lesser sac through the defect in gastrocolic ligament has been mentioned. But in the present case and a few other reported cases,^[6-9] the classification can be modified as herniation either into the lesser sac or into the peritoneal cavity across the omentum (through greater or lesser omentum) and into the layers of omentum.

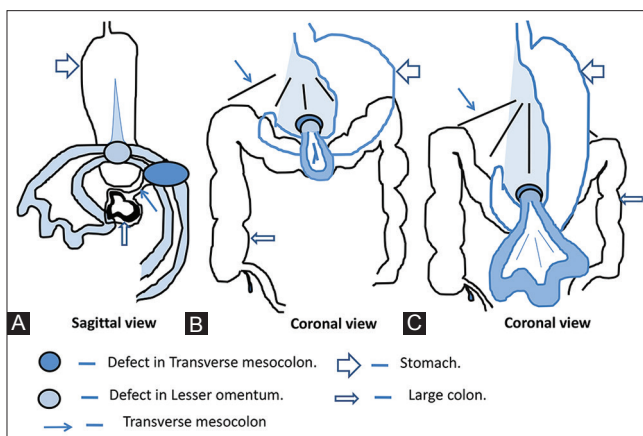


Figure 3 (A-C): Diagram representing combined transmesocolic and transomental (through lesser omentum) hernia. A shows the herniated bowel loops seen ventral to the distal stomach, and C represents the stretched down stomach and the transverse colon with increasing intestinal obstruction. B represents the initial findings of the same hernia

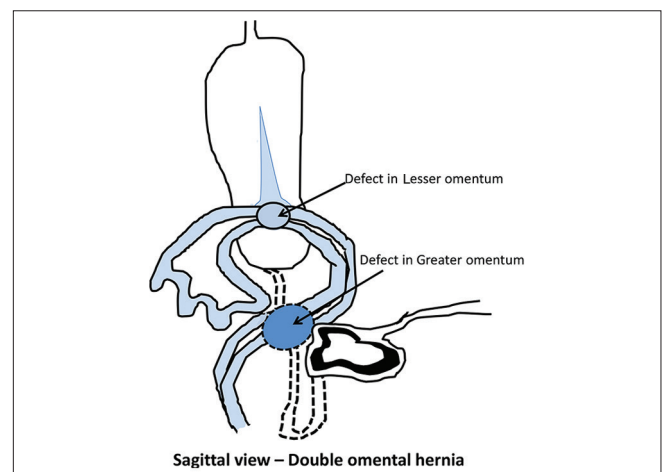


Figure 4: Diagram showing double omental hernia with small bowel loops herniating from greater and lesser omental defects with prolapsed loops seen anterior to the distal stomach; it may present as epigastric lump

Conclusion

The indirect signs (small bowel loops antero-superior to the distal stomach, ventral to the transverse colon, and the stretched bowel sign) are useful for diagnosis of combined transomental (through lesser omentum) and transmesocolic hernia and double omental hernia (internal hernias where the herniating bowel loops are seen antero-superior to the distal stomach and stretching of adjacent bowel loops with increasing herniating bowel segment and/or intestinal obstruction) on routine USG and CT examinations and even on barium follow-through study. Using the same principle, hernias through a defect in the transverse mesocolon and gastrocolic ligament can also cause mass effect with stretching of the transverse colon.

References

1. Takeyama N, Gokan T, Ohgiya Y, Satoh S, Hashizume T, Hataya K, *et al.* CT of internal hernias. *Radiographics* 2005;25:997-1015.
2. Chou CK, Mak CW, Wu RH, Chang JM. Combined transmesocolic-transomental internal hernia. *AJR Am J Roentgenol* 2005;184:1532-4.
3. Stern LE, Warner BW. Congenital Internal Abdominal hernias: Incidence and Management. In: Fitzgibbons RJ Jr, Greenburg AG, editors. *Nyhus and Condon's hernia*. 5th ed. Philadelphia: Lippincott Williams and Wilkins; 2002. p. 461.
4. Martin LC, Merkle EM, Thompson WM. Review of internal hernias: Radiographic and clinical findings. *AJR Am J Roentgenol* 2006;186:703-17.
5. Meyers MA, Charnsangavej C, Oliphant M. *Meyers' Dynamic Radiology of the Abdomen Normal and Pathological Anatomy*. 6th ed. New York, NY: Springer; 2011. p. 398-400.
6. See JY, Ong AW, Iau PT, Chan ST. Double omental hernia-case report on a very rare cause of intestinal obstruction. *Ann Acad Med Singapore* 2002;31:799-801.
7. Mukherjee R, Paira SK, Ghosh P, Halder SK, Roy B, Ray D, *et al.* Strangulated double omental hernia presenting as an epigastric lump. *J Indian Med assoc* 2012;110:655-6.
8. Masuda H, Nakayama H, Nakamura Y, Aoki N. A rare type of lesser sac hernia. *Hepatogastroenterology* 2001;48:741-2.
9. Rayter Z, Chinegwundoh F. An unusual omental hernia. *Postgrad Med J* 1990;66:682-3.

Cite this article as: Kundaragi NG, Vinayagam S, Mudali S. Stretched bowel sign in combined transmesocolic and transomental internal hernia: A case report and review of literature. *Indian J Radiol Imaging* 2014;24:171-4.
Source of Support: Nil, **Conflict of Interest:** None declared.