Article published online: 2021-08-02

Bilateral congenital absence of flexor pollicis longus with thumb hypoplasia and thenar atrophy

Vikas Chaudhary, Harsha Sehgal, Shahina Bano[1], Pranjali R Parmar, Sanjay Kumar[2]

Department of Radiodiagnosis, [2]Orthopedics, Employees' State Insurance Corporation Model Hospital, Sector-9A, Gurgaon, Haryana, and [1]Radiodiagnosis, Post Graduate Institute of Medical Education and Research, Dr. Ram Manohar Lohia Hospital, New Delhi, India

Correspondence: Dr. Vikas Chaudhary, Department of Radiodiagnosis, Employees' State Insurance Corporation (ESIC) Model Hospital, Sector - 9A, Gurgaon - 122 001, Haryana, India. E-mail: dr_vikaschaudhary@yahoo.com

Abstract

Congenital absence of flexor pollicis longus with or without associated anomalies of thenar muscles and thumb is of rare occurrence. Inability to flex the interphalangeal joint of the thumb and absent dorsal wrinkles and flexion creases of the thumb are important clues to the diagnosis. Routine radiography and cross-sectional imaging help to confirm and document the condition. This article presents an extremely rare case of bilateral congenital absence of flexor pollicis longus tendon with thumb hypoplasia and thenar atrophy.

Key words: Bilateral congenital anomaly; flexor pollicis longus; magnetic resonance imaging; thenar atrophy

Introduction

The human thumb is opposable and prehensile, making it the most unique digit of the hand, responsible for hand functions, grasp, manual dexterity, and fine motor skills. The thenar eminence constitutes the intrinsic muscles of the hand that are responsible for complex movements of the thumb. Congenital anomaly of the thumb and/or of the thenar muscles can be quite a disabling condition.[1] In 1979, Arminio was the first to report congenital absence of the flexor pollicis longus (FPL) tendon.[2] Since then, many cases have been published with congenital absence of the FPL tendon with or without associated anomalies of the thumb and thenar muscles.[3-6] Most of the reports have documented unilateral absence of FPL tendon;[2-6] bilateral absence is extremely rare.[7,8] Only three cases of bilateral congenital absence of FPL tendon have been reported so far; no thenar atrophy was seen in these cases.[7,8,9] We present a case of a 9-year-old female child with bilateral congenital absence of FPL tendon and associated thumb hypoplasia and thenar eminence atrophy.

Access this article online	
Quick Response Code:	Website: www.ijri.org
	DOI: 10.4103/0971-3026.137044

Case Report

A 9 year old female child presented to our hospital with difficulty in performing tasks like writing or holding an object. However, she had no significant difficulty in her daily activities.

There was absence of flexion movement at interphalangeal (IP) joints of bilateral thumbs. The child did not give any history of trauma. Family history of any birth defect was also absent.

Local examination revealed minor hypoplasia of the thumbs and absence of dorsal wrinkles [Figure 1a] and flexion creases [Figure 1b] at the IP joints of both the thumbs. Thenar eminence atrophy was present [Figure 1b]. Active flexion at the IP joints of bilateral thumbs was absent. Thumb opposition was also weak. Functional limitation in holding a pen was documented [Figure 1c]. Movements of all other joints of the hand were normal.

Radiograph of hands showed mild skeletal and soft tissue hypoplasia of bilateral thumbs [Figure 2].

Magnetic resonance imaging (MRI) of hands showed absence of bilateral FPL muscles. In addition, there was absence of flexor pollicis brevis (FPB) and abductor pollicis brevis (AbPB) muscles and hypoplasia/atrophy of bilateral opponens pollicis (OP) muscles. Bilateral adductor pollicis brevis (AdPB) muscles appeared normal in morphology [Figure 3].

After pre-anesthetic checkup, the patient was planned for FPL reconstruction in bilateral thumbs. Two-staged surgery was planned; in the first stage, flexor pulley was reconstructed, and 2 months later, FPL reconstruction was done using flexor digitorum superficialis (FDS) tendon to the ring finger. Postoperative physiotherapy was done to increase the range of motion (ROM) of the IP joints of both thumbs. At this moment, the patient has achieved ~20° of flexion at the IP joints bilaterally.

Discussion

Congenital inability to flex the IP joint of the thumb may be due to several causes, including congenital absence of FPL, anomalous insertion of FPL, congenital tenovaginitis of the flexor tendon sheath, partial anterior interosseous nerve paralysis, traumatic rupture of the FPL, and anomalous connection between the tendons. Among these, congenital absence of the FPL is extremely rare.[4,5]

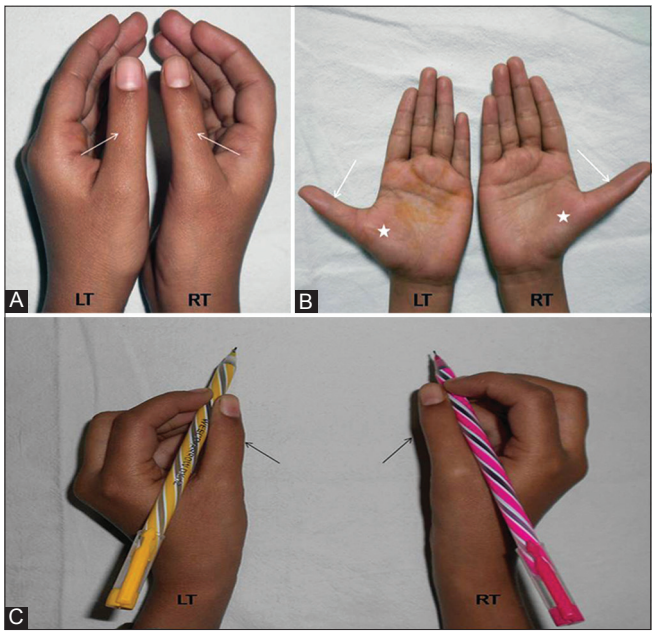

Figure 1 (A-C): (A) Dorsal view of both thumbs. Minor hypoplasia of both the thumbs and absence of dorsal wrinkles are seen (arrows). (B) Palmar surface of the hands show absent flexion creases (arrows) of bilateral thumbs. Thenar eminence atrophy is also present (asterisk). (C) Functional limitation in holding a pen; note the absence of active flexion of the interphalangeal joints of both the thumbs

Absence of FPL may occur with or without associated anomalies of the thumb and thenar muscles.[3-6] Thumb hypoplasia with congenital absence of the FPL tendon, but without hypoplasia of the thenar muscles is the rarest variation.[4,5] Congenital absence of thenar muscles (e.g. FPB and AbPB) without absence of FPL has also been reported in literature.[1] The deficiency of FPL is usually unilateral,[2-6] but may rarely be bilateral.[7-8] Most cases are reported in the pediatric age group[2,6,7] and only a few are described in adults.[3,7]

Clinically, the affected thumb shows absent or less evident dorsal wrinkles and flexion creases. The FPL tendon could not be palpated in the flexor crease of the thumb. There is loss of active flexion at the IP joint. Skeletal and soft tissue hypoplasia of thumb may be present.[2-8] According to Blauth *et al.*, thumb hypoplasia may be classified as isolated minor hypoplasia (type 1), associated with thenar hypoplasia and metacarpophalangeal (MCP) joint instability (type 2), musculotendinous/osseous deficiency with absent active motion at MCP or IP joint (type 3), floating thumb (type 4), and complete absence of the thumb (type 5).[10]

Radiography and cross-sectional imaging help to confirm and document the diagnosis. Imaging may show absence (agenesis), hypoplasia, or atrophy of the muscles and tendons.[3,4] Ultrasonography (USG) is a low-cost, safe, non-invasive, and rapid method of evaluating musculoskeletal system. Real-time USG examination helps to evaluate the tendons dynamically. Absence of radiation exposure makes USG well accepted by all patients. It is indicated in patients with cardiac pacemakers and metal implants where MRI is contraindicated. Computed tomography (CT) and MRI may be used to confirm and support the USG findings.[11]

Surgical reconstruction followed by rigorous rehabilitation has been the treatment of choice. The preferred surgical

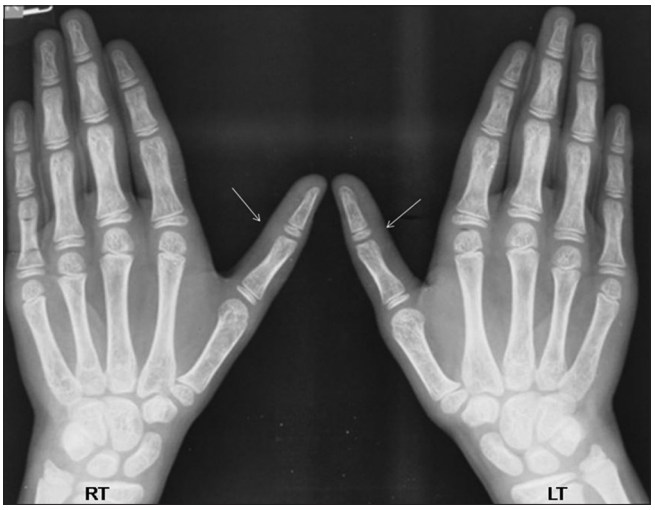

Figure 2: Radiograph of both hands shows mild skeletal and soft tissue hypoplasia of bilateral thumbs

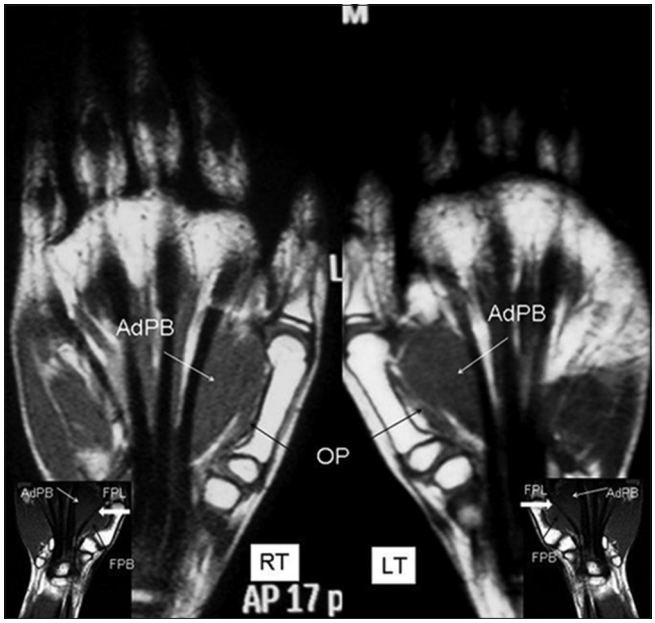

Figure 3: T1W coronal image of both the hands shows absence of bilateral flexor pollicis longus (FPL) tendons. Normally, FPL tendon is seen between the lateral head of flexor pollicis brevis (FPB) and the oblique head of adductor pollicis brevis (AdPB) muscles, and is inserted into the base of the distal phalanx of thumb (see inset images). Bilateral flexor pollicis brevis (FPB) and abductor pollicis brevis (AbPB) muscles were also absent. Hypoplasia/atrophy of bilateral opponens pollicis (OP) muscles was present. Bilateral AdPB muscles appeared normal in morphology

technique is one- or two-staged tendon transfer using the FDS tendon of the ring finger. The range of flexion achieved at IP joint after the surgery varies between 20° and 35°. Following surgery, planned physiotherapy is a must to obtain satisfactory results.[4,6,8]

This case is unique as it demonstrates bilateral congenital absence of FPL tendon in association with thumb hypoplasia and thenar atrophy in a child. Thenar atrophy was due to selective absence of bilateral FPB and AbPB, and hypoplasia/atrophy of OP. However, the patient had intact functioning of bilateral AdPB muscles.

References

1. Koca K, Ekinci S, Ege T, Ozyurek S, Kurklu M, Battal B, *et al*. Bilateral congenital absence of flexor pollicis brevis and abductor pollicis brevis muscles with bilateral thenar atrophy: A case report. Clin Med Insights Arthritis Musculoskelet Disord 2012;5:59-62.
2. Arminio JA. Congenital anomaly of the thumb: Absent flexor pollicis longus tendon. J Hand Surg Am 1979;4:487-8.
3. Suresh SS, Abraham R, Kumar SS. Absent flexor polllicis longus: Case report with review of literature. Hand 2009;4:74-7.
4. Demirseren ME, Afandiyev K, Durgan M, Kilicarslan K, Yorubulut M. Congenital absence of flexor pollicis longus tendon without associated anomalies of thumb hypoplasia; a case report and review of the literature. Hand 2007;2:184-7.
5. Alicioglu B. Radiologic findings of the flexor pollicis longus hypoplasia. Skeletal Radiol 2007;36:120-3.
6. Thomas C, Mathivanan T. Congenital absence of flexor pollicis longus without hypoplasia of the thenar muscles. J Hand Surg 1999;24:385-6.
7. Lutes WB, Tamurian R. Bilateral congenital absence of the flexor pollicis longus. Orthopedics 2007;30:318-9.
8. Neal NC, Burke FD. Bilateral congenital absence of the flexor pollicis longus. Hand Surg 1996;1:191.
9. Usami F. Bilateral congenital absence of the flexor pollicis longus with craniofacial abnormalities. J Hand Surg Am 1987;12:603-4.
10. Riley SA, Burgess RC. Thumb hypoplasia. J Hand Surg Am 2009;34:1564-73.
11. Patil P, Dasgupta B. Role of diagnostic ultrasound in the assessment of musculoskeletal diseases. Ther Adv Musculoskelet Dis 2012;4:341-55.

Cite this article as: Chaudhary V, Sehgal H, Bano S, Parmar PR, Kumar S. Bilateral congenital absence of flexor pollicis longus with thumb hypoplasia and thenar atrophy. Indian J Radiol Imaging 2014;24:268-70.

Source of Support: Nil, **Conflict of Interest:** None declared.